

Use of a Hybrid Open and Endovascular Approach to Successfully Repair a Traumatic Retrohepatic Inferior Vena Cava Injury

Yan Shi¹, Matthew J Wall Jr² and Ramyar Gilani^{3*}

¹Division of Vascular Surgery, Michael E. DeBakey Department of Surgery, Baylor College of Medicine, USA

²Division of Cardiothoracic Surgery, Michael E. DeBakey Department of Surgery, Baylor College of Medicine, USA

³Division of Vascular Surgery, Michael E. DeBakey Department of Surgery, Baylor College of Medicine, USA

Abstract

Purpose: To describe a damage control open and endovascular approach that successfully repaired a catastrophic retrohepatic injury to the inferior vena cava (IVC).

Case Report: A 25-year-old man presented with two gunshot wounds to the trunk. During open operative exploration, a penetrating injury to the IVC behind the caudate lobe of the liver was encountered. To quickly control hemorrhage, en-mass ligation of the injured area and surrounding tissues was performed which resulted in significant IVC stenosis at the level of the repair. After resuscitation in the intensive care unit, the patient was brought back to the operating room where inline flow through the IVC was reestablished by bridging the defect using a 20mm x 55mm covered stent graft.

Conclusions: As endovascular expertise and devices become more refined and readily available to treat trauma, variations of this hybrid technique have the potential to become powerful tools to repair retrohepatic IVC injuries.

Keywords: Retrohepatic; Inferior vena cava; Endovascular; Trauma; IVC ligation; IVC; IVC Stenosis

Introduction

Retrohepatic Inferior Vena Cava (IVC) injuries remain among the most challenging vascular injuries to manage. Perioperative mortality has not been significantly reduced despite the introduction of novel techniques and approaches detailed in the surgical literature over the past decades. In many cases, the main obstacles to successful repair are lack of adequate exposure and difficulty controlling hemorrhage. Some of these obstacles may be overcome using endovascular therapy, which has the inherent advantages of allowing remote endoluminal vascular access and offering potential therapeutic intervention without need for surgical exposure and traditional proximal and distal control. In this report, we describe the successful repair of a retrohepatic inferior vena cava injury using a hybrid open and endovascular approach.

Case Report

A previously healthy 25 year-old man presented to the emergency department after sustaining two gunshot wounds to the left chest and back. On presentation, he was normotensive with a Glasgow Coma Scale (GCS) score of 15. A left tube thoracostomy was placed for a

hemopneumothorax seen on chest radiograph. The patient was taken emergently to the operating room for exploration and placed on a non-fluoroscopy compatible bed. Injuries to the left hemidiaphragm, the stomach, and the caudate lobe of the liver were encountered. An expanding hematoma surrounding the caudate lobe was explored and a large volume venous bleeding was encountered, which was refractory to control via Pringle maneuver and suprarenal IVC clamping. A through-and-through injury of the IVC posterior to the liver was revealed. Because of the ongoing hemorrhage, the IVC, the caudate lobe, and surrounding tissues were ligated en-mass using 4-0 prolene figure-of-eight sutures as a desperate damage control maneuver with planned re-exploration and possible reconstruction. The other injuries were addressed, the abdomen was packed, and the patient was taken to the intensive care unit for resuscitation.

As expected, the patient experienced a marked decrease in urine output and an increase in his serum creatinine from 0.9 to 1.8 mg/dl after 6 hours. Once the patient was adequately resuscitated, he was taken back to the operating room and bilateral femoral vein access was obtained. A venogram demonstrated occlusion of the suprarenal IVC (Figure 1A) at the level of ligation and a large infrarenal thrombus. These findings were confirmed with Intravascular Ultrasound (IVUS). To prevent propagation or migration of the thrombus after restoration of IVC patency, open thrombectomy was performed via a transverse venotomy at the level of the renal veins away from the injury prior to attempting our repair. The procedure yielded a large amount of fresh thrombus.

***Corresponding author:** Ramyar Gilani, Division of Vascular Surgery, Michael E. DeBakey Department of Surgery, Baylor College of Medicine, One Baylor Plaza, MS 390, Houston, TX 77030, USA, Tel:2405065230; E-mail: rgilani@bcm.edu

Received July 21, 2014; Accepted August 03, 2014; Published August 15, 2014

Citation: Shi Y, Wall Jr MJ, Gilani R (2014) Use of a Hybrid Open and Endovascular Approach to Successfully Repair a Traumatic Retrohepatic Inferior Vena Cava Injury. J Vasc Med Surg 2: 147. doi: [10.4172/2329-6925.1000147](https://doi.org/10.4172/2329-6925.1000147)

Copyright: © 2014 Shi Y, et al. This is an open-access article distributed under the terms of the Creative Commons Attribution License, which permits unrestricted use, distribution, and reproduction in any medium, provided the original author and source are credited.

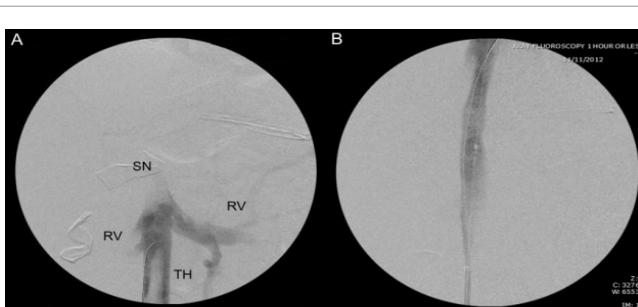


Figure 1: Initial and completion venogram. (A) Initial subtraction venogram of the inferior vena cava. SN: Area of stenosis; RV: Renal veins; TH: Large thrombus. **(B)** Completion venogram with brisk flow across deployed stent graft.

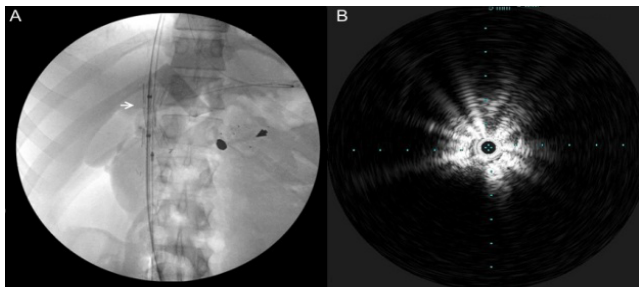


Figure 2: Placement of covered stent graft. (A) White Arrow: Angiogram showing placement of 20mm x 55mm covered stent graft at the level of the stricture. A radiopaque wound marker and bullet are visible on the right (B) Corresponding IVUS image demonstrates nascent stent graft and near total occlusion of the vena cava lumen.

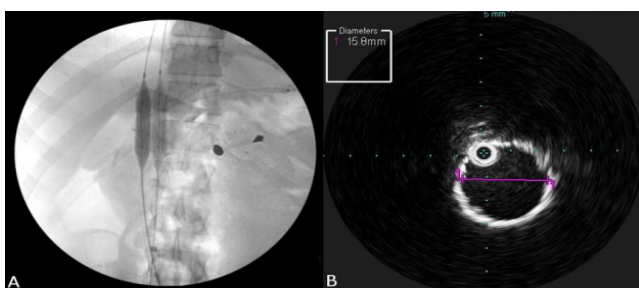


Figure 3: Dilation of stent and of patency. (A) Angiogram demonstrating dilation of the stenosis and deployment of the covered endostent using dual 12mm high pressure balloons. (B) IVUS measurement of fully deployed endostent demonstrates a widely patent lumen measuring 15.8mm.

After completing the thrombectomy, the IVUS probe was introduced to measure IVC diameters and mark levels of the hepatic and renal veins. An ESLE 20 mm×55 mm stent graft (Cook Medical, Bloomington, IN) was then introduced and deployed between the hepatic and renal veins (Figure 2). The sutures for ligation were still in place causing significant graft stenosis, these were purposely disrupted by dilating the stent graft using two 12mm high pressure balloons (Figure 3). Completion venography and IVUS demonstrated brisk flow through the vena cava, no extravasation of contrast, and widely patent hepatic and renal veins (Figure 1B).

The patient had an uneventful post-operative course. Urine output normalized and serum creatinine returned to baseline within 48 hours. The patient was discharged home on hospital day eight. At one month follow-up, the patient was recovering well without evidence of kidney dysfunction or lower extremity edema.

Discussion

Traumatic injuries to the retrohepatic vena cava remain among the most challenging vascular injuries encountered by the trauma surgeon. The expected mortality associated with IVC injuries is 64 to 77% [1-3]; the most common cause of death is overwhelmingly due to exsanguinations [2], which often occurs during the prolonged maneuvers required to achieve exposure and subsequent control of the bleeding vessels. The procedure of IVC ligation is an acceptable damage control maneuver to rapidly control hemorrhage in a physiologically unstable trauma patient in which primary IVC repair would be exceedingly difficult and prolonged, such as the case in IVC injuries

that occur behind the parenchyma of the liver. However, there are only sporadic case reports of patients who have survived suprarenal IVC ligation [4,5].

Endovascular techniques to manage vascular pathology have been described as early as 1969[6]. The endovascular approach has since been validated as a powerful adjunct to open repair of aortic trauma in a large multicenter trial [7]. In the past two decades, these techniques have increasingly been applied to the realm of vascular trauma with promising initial results [8-10]. To date, three case reports are noted of IVC injuries repaired using endovascular therapy [11-13]. In each case, hemorrhage was successfully controlled by deployment of an endograft within the IVC. No stent-related complications, patency issues, or hemorrhage-related deaths were reported during follow-up in these cases.

The case we describe demonstrates inherent difficulties in managing retrohepatic IVC injuries with traditional open techniques, as well as the utility of implementing endovascular capability in combination with open damage control surgery. As expected, the injured IVC was associated with significant hemorrhage. Furthermore, the hemorrhage was exacerbated and uncontrollable once the surrounding hepatic attachments and the retroperitoneum were incised. Hemorrhage control was attempted via a Pringle maneuver and suprarenal IVC clamping, but this was ineffective. Clamping the IVC immediately below the hepatic veins for controlled repair was felt to be temporally and technically impractical, leaving ligation and atriocaval shunt to consider.

In retrospect, the patient would have been better served by being placed on a fluoroscopic compatible OR table from the outset, which is increasingly being used by our service for operative trauma explorations. Once a hematoma in the retroperitoneum is identified, temporary hemorrhage control via packing without further dissection and consideration for endovascular options is advisable. Diagnosis, endovascular balloon control, and definitive therapy are all possible and would have been applicable in this case during the initial exploration. In addition, an IVC ligated or significantly narrowed because of necessity can be safely salvaged via an endovascular approach. If salvage is to be attempted, it is important to utilize suture that can be disrupted later with balloon insufflation. It can also be important to preserve vessel continuity without division during damage control if an endovascular rescue is to be an option.

Conclusion

This case report and other few cases described in the literature to date indicate that an endovascular approach has the potential to be a powerful adjunctive tool for the repair and control of difficult to access IVC injuries and warrants consideration when such injuries are encountered.

References

1. Degiannis E, Velmahos GC, Levy RD, Souter I, Benn CA, et al. (1996) Penetrating injuries of the abdominal inferior vena cava. *Ann R Coll Surg Engl* 78: 485-489.
2. Burch JM, Feliciano DV, Mattox KL, Edelman M (1988) Injuries of the inferior vena cava. *Am J Surg* 156: 548-552.
3. Turpin I, State D, Schwartz A (1977) Injuries to the inferior vena cava and their management. *Am J Surg* 134: 25-32.
4. Sullivan PS, Dente CJ, Patel S, Carmichael M, Srinivasan JK (2010) Outcome of ligation of the inferior vena cava in the modern era *Am J Surg* 199: 500-506.

5. Votanopoulos KI, Welsh FJ, Mattox KL (2009) Suprarenal inferior vena cava ligation: a rare survivor. *J Trauma* 67: E179-180.
6. Dotter CT (1969) Transluminally placed coil-spring endoarterial tube grafts: long-term patency in canine popliteal artery. *Invest Radiol* 4: 329-332.
7. Cambria RP, Crawford RS, Cho JS, Bavaria J, Farber M, et al. (2009) A multicenter clinical trial of endovascular stent graft repair of acute catastrophes of the descending thoracic aorta. *J Vasc Surg* 50: 1255-1264.
8. Reuben BC, Whitten MG, Sarfati M, Kraiss LW(2007) Increasing use of endovascular therapy in acute arterial injuries: analysis of the National Trauma Data Bank. *J Vasc Surg* 46: 1222-1226.
9. DuBose JJ, Rajani R, Gilani R, Arthurs ZA, Morrison JJ, et al. (2012) Endovascular management of axillo-subclavian arterial injury: a review of published experience. *Injury* 43: 1785-1792.
10. White R, Krajcer Z, Johnson M, Williams D, Bacharach M, et al. (2006) Results of a multicenter trial for the treatment of traumatic vascular injury with a covered stent. *J Trauma* 60: 1189-1195.
11. Watarida S, Nishi T, Furukawa A, Shiraishi S, Kitano H, et al. (2002) Fenestrated stent-graft for traumatic juxtahepatic inferior vena cava injury. *J Endovasc Ther* 9: 134-137.
12. Erzurum VZ, Shoup M, Borge M, Kalman PG, Rodriguez H, et al. (2003) Inferior vena cava endograft to control surgically inaccessible hemorrhage. *J Vasc Surg* 38: 1437-1439.
13. Castelli P, Caronno R, Piffaretti G, Tozzi M (2005) Emergency endovascular repair for traumatic injury of the inferior vena cava. *Eur J Cardiothorac Surg* 28: 906-908.