

## Treatment of Cutaneous Leishmaniasis by Topical Application of Honey

Mahasen Wadi<sup>1\*</sup>, Al Fadhil Al Obeid<sup>2</sup> and Sami Khalid<sup>3</sup>

<sup>1</sup>King Saud University, College of Applied Medical Sciences, Department of Clinical Laboratory Sciences, Riyadh, Saudi Arabia

<sup>2</sup>Al-Neelain University, Faculty of Medical Laboratory Science, Department of Medical Microbiology Khartoum, Sudan

<sup>3</sup>Khartoum University, Faculty of Pharmacy, Department of Pharmacognocny Kartoum, Sudan

### Abstract

**Objective:** The objective of this study is to evaluate the effect of topical application of honey on induced cutaneous leishmaniasis ulcer in 25 hamsters (*Mesocricetus auratus*) compared with control group of another 25 hamsters treated by pentostam injection.

**Methods:** A group of 50 adult male and female hamsters, were inoculated with  $1 \times 10^5$  cells/mL of *Leishmania major*. Culture medium was examined microscopically for promastigotes. Samples of 0.1 ml positive culture were inoculated to the hamster –tail base intradermally. The animals were checked for lesion. Which were taken impression smear.. Smears were fixed and stained with Giemsa's. Honey was applied topically to infected lesions of one group of hamsters. The control group were injected with 0.1 mL pentostam intramuscular every other day. Lesions were measured daily by millimeter paper.

**Results:** After two weeks all the inoculated hamsters developed different types of lesions. The 25 group of hamsters treated with honey responded to treatment after one week. The control group treated with pentostam injection showed low response to treatment, it took prolonged time to heal up to 12-16 weeks.

**Conclusion:** Topical dressing of cutaneous leishmaniasis ulcers with honey is very effective and helps in the treatment in a short time as compared with pentostam injection.

**Keywords:** Cutaneous leishmaniasis; Alternative treatment; Pentostam

### Introduction

Apitherapy has become the focus of interest as a form of alternative and preventive medicine for treatment of a number of clinical cases. Honey has been suggested as an effective healing agent in treatment of postoperative wounds [1]. In many cases honey has cleaned up wounds when conventional treatment was unsuccessful. Honey has a potent antibacterial activity and is very effective in clearing wounds infection by inhibiting a wide range of bacteria [2]. Commercial honey has been reported to accelerate wound healing when applied topically to experimentally induced wounds [3]. Wadi [4], was the first to investigate the biological activity of Sudanese honey on purulent wounds of hospitalized patients when applied topically, favorable results were obtained. Honey can enhance wound healing by promoting healthy granulation tissue growth and act as a barrier to prevent cross infection [4]. Antibacterial activity of honey was attributed to hydrogen peroxide naturally present in it [5].

Cutaneous leishmaniasis is a zoonotic disease caused by protozoa of the genus *Leishmania* and is transmitted to humans by sand fly insects of the genus *Phlebotomus*. There are two important stages in the life cycle of *Leishmania*: amastigotes found in man and other non-human reservoir mammals and promastigotes found in the sand fly. In the vertebrate host, Cutaneous leishmaniasis is caused by the amastigote form, which infects the macrophage cells in which it multiplies by binary fission, causing death of the host cell. The lesion then becomes necrotic. The clinical outcome will depending on the parasite strain and the host immune response. The lesions are confined to the skin and to the mucous membrane A granulomatous response occurs and a necrotic ulcer forms at the bite site. Macrophages containing amastigotes, which may be killed by sensitized lymphocytes were detected in microscopic smear. The lesion may become chronic, usually accompanied by secondary bacterial infection [6]. Diagnosis is usually confirmed microscopically by demonstrating the presence

of amastigotes in smear taken from the skin lesion or organs or may be demonstrated in hamsters inoculated with samples collected from patients. Sodium stibogluconate (pentostam), is the drug of choice given intramuscular in case of multiple lesions [6]. Recent clinical and laboratory research has addressed diagnosis by the polymerase chain reaction which seems to be approaching a gold standard status as the novel techniques offer considerable advantages [7]. Treatment in single lesion it may be injected into the margin of the ulcers. Leishmaniasis responds poorly to treatment and frequently relapses. Secondary infections add to the severity of lesions both in the skin and mucous membranes [6]. Zenia *et al.* [8] investigated the *in vitro* activity of honey dilutions against three species of *Leishmania* (the promastigote stage (. The result was compared with the effects of the same concentrations of sugars. Honey and sugar both had anti-leishmanial effects *in vitro*, but honey was found to be more effective than sugar. Mohammad *et al.* [9] tested honey as an adjuvant therapy with intralesional glucantime and reported that the effect of glutacantime in healing was actually decreased.

### Material and Methods

#### Culture medium

Schneider's medium was used, this medium is useful for maintaining

\*Corresponding author: Mahasen Wadi, King Saud University, College of Applied Medical Sciences, Department of Clinical Laboratory Sciences, Riyadh, Saudi Arabia; E-mail: [mahasinwadi@yahoo.com](mailto:mahasinwadi@yahoo.com)

Received February 18, 2011; Accepted March 27, 2011; Published April 06, 2011

**Citation:** Wadi M, Al Fadhil, Khalid S (2011) Treatment of Cutaneous Leishmaniasis by Topical Application of Honey. J Bacteriol Parasitol 2:110. doi:10.4172/2155-9597.1000110

**Copyright:** © 2011 Wadi M et al. This is an open-access article distributed under the terms of the Creative Commons Attribution License, which permits unrestricted use, distribution, and reproduction in any medium, provided the original author and source are credited.

parasite stocks and is available from Sigma Chemical, ( U.K ) in the form of powder. The recommended amount of powder was dissolved in 1L of deionized water and stirred with a magnetic stirrer until all the powder was dissolved,  $p^H$  was adjusted to 7.4 by using 0.1 mL HCL. The medium was filtered through sterile filter using a 0.2 micrometer membrane filter. Then it was poured into pre-autoclaved sterile bottles and 10% V/V sterile fetal calf serum was added, 1% antibiotic-penicillin and streptomycin was added to prevent bacterial contamination. The medium was checked for sterility by incubation at 37°C for 24 hours.  $1 \times 10^5$  cells of leishmania major, ( isolated from patients ) was inoculated to the medium. Regular checks for parasite growth were made by observing the inoculated medium using microscopical objective lens( x 40 ). Incubation time was six days at 22 °C.

### Animal inoculation

A group of 50 adult male and female hamsters were shaved at the base of the tail and were cleaned by alcohol swabs. The medium was examined microscopically for promastigotes. Positive culture was centrifuged at 3000 rpm for 3 minutes, the supernatant layer was discarded. An aliquot of 0.1 Ml from the culture deposit was inoculated into the hamsters-tail base-intradermally. The hamsters were checked for lesion at the site of inoculation weekly. Impression smears were taken from detected lesion. The smears were then fixed with methanol and stained with Giemsa's. Biopsy was smeared on slide and allowed to dry. The slide was immersed in methanol for 1-3 minutes for fixation. Diluted Gimesa's stain (1:10) in buffered saline ( $p^H$  7.2) was used for 20 minutes. The slide was washed by distilled water and examined under oil immersion objective lens x100.

### Biopsy technique

A small piece of skin was removed from the opened lesion of the infected hamsters by a sharp sterile blade near the edge of the lesion, in which amastigotes were present. The biopsy was transferred to 10% formalin in sterile universal containers for diagnosis. The material was fixed and sectioned for standard histopathological processing. The fixed smear material was processed for staining with Giemsa's stain.

### Tissue processing

The following steps for tissue processing was; dehydration and embedding in paraffin wax. Automated tissue processing was performed.

### Topical dressing of the infected lesion by honey

Infected hamsters were divided randomly into two groups, one group of 25 hamsters were treated with topical dressing of natural raw honey. The other 25 hamsters group served as control and were treated with pentostam injection. The animals were examined daily. All opened lesion of the 25 hamsters – test group – was covered by honey sample K obtained from Yemen- (Sidr). Honey was applied topically to the infected lesion by soaking gauze in honey and covered by plasters. Each animal was kept separately, to prevent licking by other animals. Animals were dressed daily by topical application of honey, lesion size was measured daily in cm. The control group was injected every other day by with 0.1ml intramuscular pentostam and the lesion was cleaned daily by saline and alcohol and covered by sterile gauze. The lesions were measured daily.

### Results

After two weeks all inoculated hamsters developed different types of lesions ranging from nodules to opened ulcerated lesions Figures 1 and 2. The size of the lesion ranged from 0.5 to 2cm.

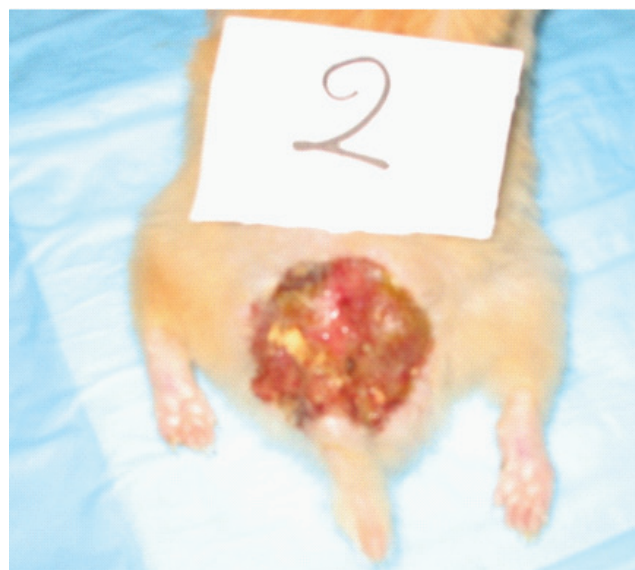


Figure 1: Developed *Leishmania* ulcer after 2 weeks of infection.

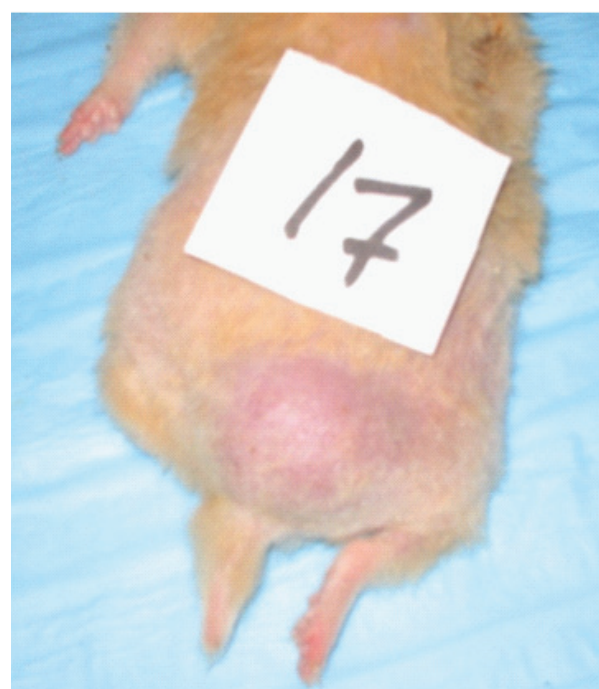


Figure 2: Nodular form of *Leishmania* ulcer after 2 weeks of infection.

Smears were taken from all lesions and stained with Giemsa's stain and examined microscopically for amastigotes stage. The smears showed intracellular amastigotes, inflammatory cells, lymphocytes, histocytes and plasma cells. Amastigotes were found intracellular as well as extracellular due to the cell ruptured and a biopsy from the lesion was taken to make a definitive diagnosis. The group of hamsters treated daily by honey application on sterile clean gauze, showed a good response to treatment after one week. Lesion appears bright red with early epithelization tissue. Necrotic tissue was replaced with healthy granulation tissue Figures 3 and 4.



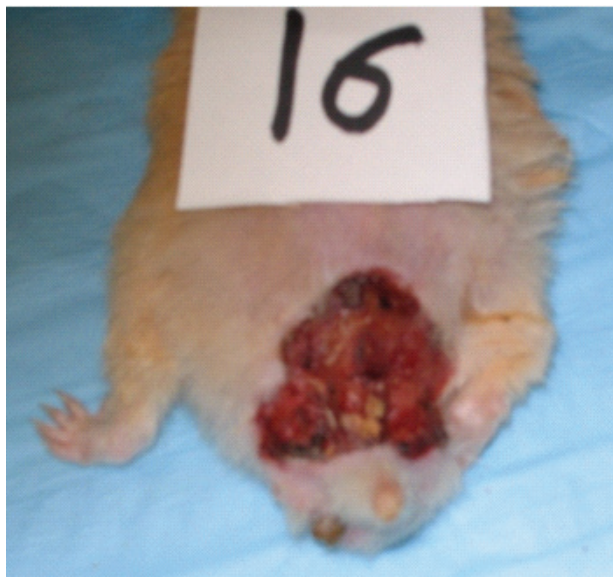

Figure 3: Leishmania ulcer before honey treatment, ulcer full of pus.

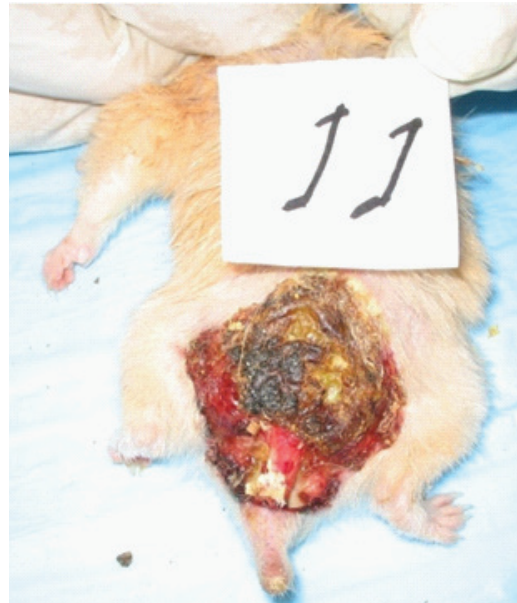

Figure 5: Leishmania ulcer after 4 weeks of pentostam injection.

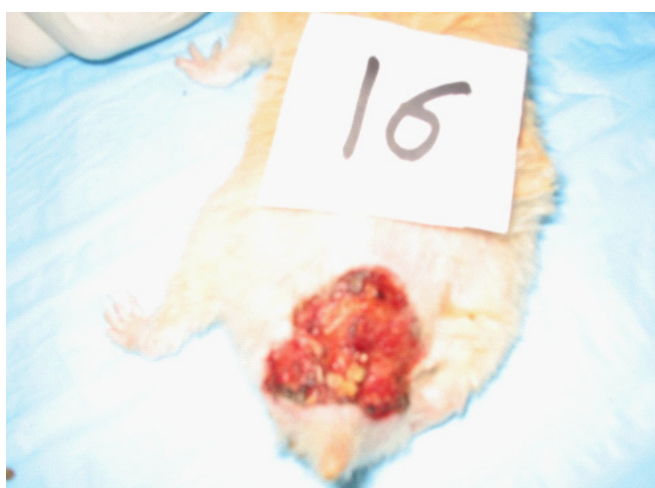


Figure 4: Leishmania ulcer after one week of honey dressing, healthy granulation tissue was formed.

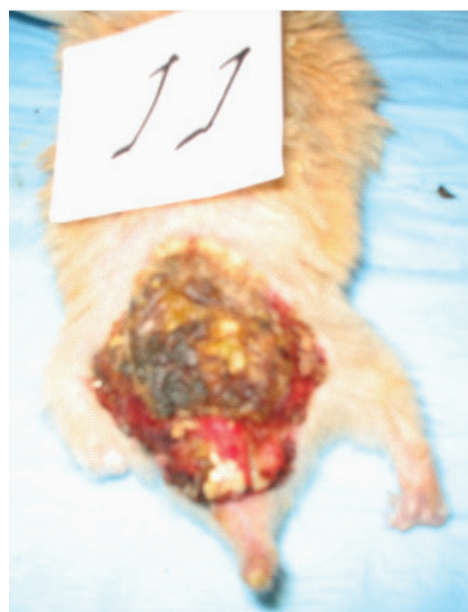


Figure 6: Leishmania ulcer after 6 weeks of pentostam injection.

Healing of 80 % hamsters treated with honey were achieved within 4 weeks. Healing was assessed by disappearance of amastigotes in microscopic smear and ulcer size was decrease Figure 9.

Futhermore, formation of healthy granulation tissue and cleanliness of ulcers from bacterial infection confirmed the healing process. In healing lesion smears showed giant and lymphocytes cells. The other 25 hamsters served as control group: treated with pentostam injection showed poor response to the treatment, 48 % of hamsters were healed. Ulcers remaining infected with amastigotes, lesions appeared with pus and necrotic tissue, Figures 5 and 6. It took prolonged time to heal up to 16 weeks. Animals treated with daily application of honey responded within short period as compared with those treated with pentostam injection Table 1. Healing was judged by absence of amastigotes and cleanliness of ulcer from bacterial and fungal infection. Growth of healthy granulation tissue was obtained.

Complete healing of the lesions was assessed by absence of

amastigote parasite: negative direct smear and complete re epithelization of the ulcers were observed. Diameter lesion and size of ulcers were decreased when measured by the millimeter papers Figure 7 and 8.

## Discussion

Cutaneous leishmaniasis is one of the important endemic diseases in tropical and subtropical countries. It is a long lasting skin disease and the ulcer might be at high risk of secondary infection. Honey is a well known antibacterial agent that help healing wounds and ulcers [11]. The findings of the present study showed that healing of cutaneous leishmaniasis of hamsters treated with honey dressing was achieved within 4 weeks. Ulcers appeared bright red with healthy granulation

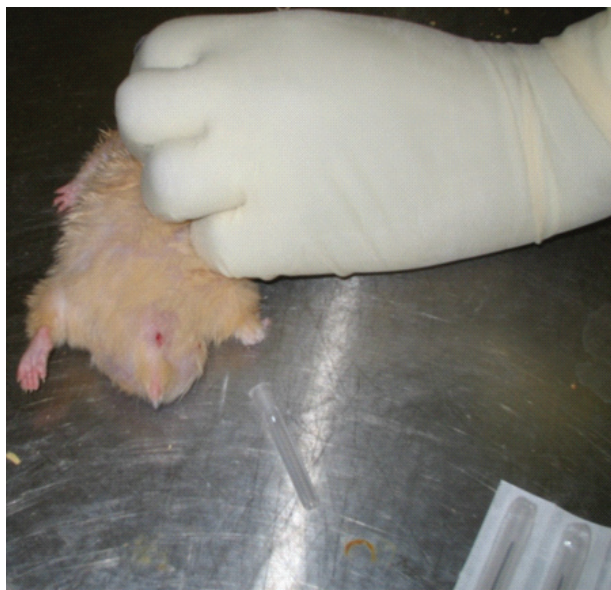

Figure 7: Healing of the ulcer treated with honey after 4 weeks.

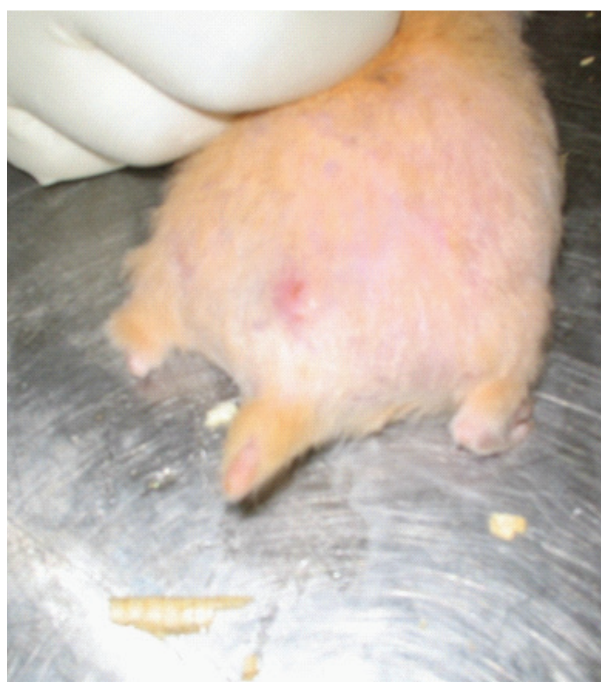

Figure 8: Healing of the ulcer treated with honey after 4 weeks.

tissue free from amastigotes, bacteria and fungus, while the control group treated with pentostam injection took prolonged time to heal of 14–16 weeks. The lesions appeared infected with pus and necrotic tissue. Amastigotes were detected. The course of the healing process may take more than a year [6]. Honey has been suggested as an effective treatment for different kinds of infected ulcers as it was proved as antibacterial agent that inhibit a wide range of micro-organisms [10]. In speculating about the mechanisms of honey as destructive agent for amastigotes, it is reasonable to assume that Hygroscopic nature of honey, plus it is acidic properties (low  $p^H$  3.6) may inhibiting

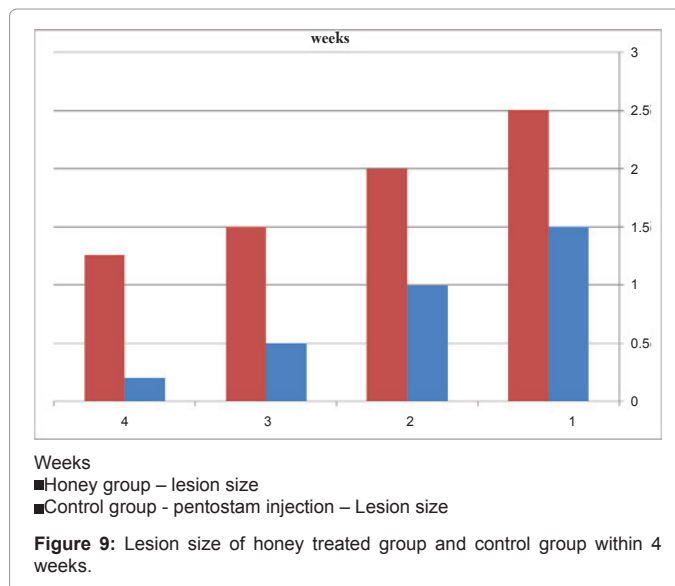


Figure 9: Lesion size of honey treated group and control group within 4 weeks.

intracellular amastigotes. Honey is a saturated solution of sugars, with very low water content [5]. This condition is inhibitory to the most of microorganisms. Bactericidal and fungicidal effect of honey will most probably prevent secondary infection of the leishmanial ulcers. Also the low  $p^H$  of honey may help to create and maintain optimal conditions for fibroblast activity which requires mild acidic wound condition [11]. Compatibility of these findings were confirmed previously by Wadi [4] who proved that honey accelerated healthy granulation tissue of 12 hospitalized patients. Recent findings reported by Zenia *et al.* [8] which proved that honey has an antileishmanial activity when tested *in vitro*. However, the combination of honey and glucatime was found ineffective in controlling cutaneous leishmaniasis when compared with glucantime alone [8]. Furthermore the pentamidine the drug of choice for the treatment of cutaneous leishmaniasis is considered the most effective drug but with side effects [11]. Leishmaniasis responded poorly to treatment and frequently relapses. Secondary bacterial infection of the ulcer, when present should be eliminated by treatment with appropriate antibacterial agents. Supportive treatment and good nursing care are needed in most cases, particularly those with complications. Treatment should be given until the aspirate or smear are free of parasites for at least two weeks. If relapses occur, the drug should be given for twice as long as the first treatment[6]. Alternatively, honey can be suggested as an effective treatment for cutaneous leishmaniasis concerning the toxic effects of drugs. Additional advantages with the use of honey it is low cost effectiveness as compared with the drugs.

Honey has been suggested as an effective agent for different kinds of infected ulcers, as honey was proved as antibacterial agent that inhibit a wide range of micro-organisms [1]. Honey cleans the infected wounds (*i.e.* diabetic wounds, ulcers, burns and gangrene) by inhibiting a numbers of Gram- positive and Gram -negative bacteria and fungi, so this might prevent secondary infection in leishmaniasis, obviously honey help the healing process. Edema was subsided and necrotic tissue was replaced by healthy granulation tissue [4]. The hygroscopic properties of honey, may inhibiting amastigotes in macrophage cells. However, there has been tendency for healing process as honey gave favorable results when applied topically on infected wounds and ulcers [4] Bactericidal effect of honey prevented secondary infection of the leishmanial ulcers. Based on the above premise honey was thought as clearing and effective agent against amastigote. These results are in agreement with the previous findings by Zeina *et al.* [8], who found that honey was effective *in vitro* against promastigotes. Although the



Animal group	Lesion assessment	Honey treated group	Control group treated with pentostam injection
Ulcer size after infection		-All animals developed typical cutaneous leishmaniasis after 2 weeks of infection. Ulcer size about 2cm	
Lesion assessment after one week of treatment		-Lesion appears bright red with healthy granulation tissue. -Ulcer size started to decrease in size	Lesion appears full of pus  -Ulcer size increased in some cases
Lesion assessment after 2 weeks of treatment		-Healing of the ulcer confirmed by disappearance of amastigote in the smear and formation of healthy granulation tissue  -Ulcer was decreased in size	-Non –responsive ulcer with amastigote. Lesion appears with necrotic tissue full of pus  - No clinical change or progressing was observed
Healing duration		Recovery of the ulcers was achieved after 4 weeks	Recovery took prolonged time 12-16 weeks
Side effects of treatment		Honey was applied and removed easily from the lesion without side effects	Usually treatment with drug for long term has side effects, and need supportive treatment.
Susceptibility to secondary infection		-Smears appear free of bacterial and fungal infection as honey acts as strong bactericidal effects	-Lesion was full of pus due to secondary infection. Bactericidal agents must be used

**Table 1:** Patterns of honey and pentostam treatment for cutaneous leishmaniasis.

low pH of honey may help to create and maintain optimal conditions for fibroblast activity (migration, proliferation and organization of collagen which require mild acidic wound condition), [12]. Healing of cutaneous leishmaniasis was maintained when the lesion was free from parasite and bacterial infection. this particular important steps in healing process. Anti –inflammatory effects of honey was attributed to the physical properties of honey, due to it is viscosity, honey provides a protective barrier which prevent cross infection. Additional to the anti – inflammatory effects, low hydrogen peroxide naturally present in honey promotes anabolic metabolism, giving cell growth. Tonks *et al.* [13], reported that honey stimulates cytotoxine release from monocytes, which gives rise to activation of tissue repair. Additional to these effects promoting tissue growth, honey provides vitamins, minerals, amino acids and sugars for the growing cells. Thus honey was found more effective than antileishmanial drugs.

Topical dressing of cutaneous leishmaniasis ulcers with honey is very effective and helps in the treatment in a short term as compared with pentostam treatment. Honey is a natural product can be used easily without side effect with low cost. Further studies to test the efficacy of honey in cutaneous leishmaniasis is needed.

#### Acknowledgements

The present work is a part of PhD research submitted in fulfillment of the requirement of the degree of PhD in medical microbiology, AL Neelain university Khartoum Sudan. I am indebted to the dean of faculty of postgraduate studies and dean of the faculty of medical laboratory science for their help.

We thank the research center King Khalid Hospital-King Saud University, Riyadh, Saudi Arabia for providing the laboratory animals.

#### References

- Vardi A, Barzilay Z, Linder N, Cohen HA, Paret G, et al. (1998) Local application

of honey for treatment of neonatal postoperative wound infection. *Acta Paediatr* 87: 429-432.

- Wadi Mahasen A (2010) Antimicrobial Activity and Chemical Characterization of Different Floral Origin Honey AL Neelian. Khartoum, Sudan.
- Bergman A, Yanai J, Weiss J, Bell D, David MP (1983) Acceleration of wound healing by topical application of honey: an animal model . *Am J Surg* 145: 374-376.
- Wadi Mahasen A (1986) Pharmacological, chemical and microbiological studies of Sudanese bee honey University of Khartoum, Sudan.
- Crane E (1975) A Comprehensive Surveyed E Crane London Heineman in cooperation with International Bee Research Association.
- Paul Chester B, Rodney Clifton Junk (1985) Animal Agentsand Vectors of Human Disease. (5th edn), Lea, Febiber.
- Vega-lopez, Francisco (2003) Diagnosis of cutaneous leishmaniasis. *Curr Opin Infect Dis* 16:97-101.
- Zeina B, Othman O, al-Assad S (1996) Honey and thyme on Rubella virus survival in vitro. *J Altern Complement Med* 2: 345 -348.
- Nilforoushzadeh MA, Jaffary F, Moradi S, Derakhshan R, Haftbaradaran E (2007) Effect of topical honey application along with intra lesion injection of glucantima in the treatment of cutaneous Leishmaniasis. *BMC Complement Altern Med* 7:13.
- Bang LM, Bunting C, Molan P (2003) The effect of dilution on the rate of hydrogen peroxide production in Honey and its implications for wound healing. *J Altern Complement Med* 9: 267 -273 .
- Calvin M (1998) Cutaenous wound repair. *Wounds* 10: 12-32.
- Lai A Fat EJ, Vrede MA, Soetosenojo RM, Lai A Fat RF et al. (2002) Pentamidine, the drug of choice for treatment of cutaneous Leishmaniasis in Surinam. *Int J Dermatol* 4: 796-800.
- Tonks AJ, Cooper RA, Jones KP, Blair S, Parton J, et al. (2003) Honey stimulate inflammatory cytokine production from monocytes. *Cytokine* 7: 21.