

Successful Treatment of Dieulafoy's Gastric Lesion in a Critical Elderly Patient

Jordana de Melo Silva¹, Edmilson Leal Bastos de Moura^{2*}, Élide Lorena Leal Reis³, Marcelo de Oliveira Maia² and Flávio Hayato Ejima¹

¹Gastroenterology Unit, Hospital Santa Luzia, Brazil

²Intensive Care Unit, Hospital Santa Luzia, Brazil

³Universidade Ceuma, São Luís, Maranhão, Brazil

*Corresponding author: Edmilson Leal Bastos de Moura, MSc-SQSW 306 Block B Apto 409-Southwest, Brasília-Federal District, CEP 70673-432, Brazil, Tel: +867592388505; E-mail: ebmoura1@gmail.com

Rec date: May 17, 2017; Acc date: May 25, 2017; Pub date: May 27, 2017

Copyright: © 2017 de Melo Silva J, et al. This is an open-access article distributed under the terms of the creative commons attribution license, which permits unrestricted use, distribution, and reproduction in any medium, provided the original author and source are credited.

Abstract

Dieulafoy's lesion is a rare cause of upper gastrointestinal bleeding. Due to the exceptional nature of its diagnosis and severity of clinical presentation in the critically ill patients, brevity of the treatment is essential. This report describes the treatment of an elderly patient during his stay in the Intensive Care Unit.

Keywords: Gastrointestinal hemorrhage; Melena; Dieulafoy lesion; Diagnosis

Introduction

The Dieulafoy lesion is an important cause of acute gastrointestinal bleeding [1], occurring in up to 6% of non-varicose bleeds of gastrointestinal origin [2]. By definition, it originates in a dilated submucosal artery, which undergoes mucosal erosion, in the absence of an ulcer, aneurysm, or intrinsic mural abnormality [1]. In a review made by Baxter et al. [3], there had been more than 280 reported cases identified worldwide, making this a relatively uncommon condition. The mean age of affected patients is in the fifth decade of life, being more common in men with comorbidities (such as systemic arterial hypertension), chronic renal failure, and diabetes mellitus. It is associated with non-steroidal anti-inflammatory drugs, aspirin and antiplatelet use [4]. The usual clinical picture is painless, massive and recurrent gastrointestinal bleeding [2,4]. It occurs most commonly in the stomach (75%), in the small curvature (up to 6 cm from the gastroesophageal junction in 80% to 95% of cases) [1,2]. The diagnosis is made by endoscopy, sometimes difficult, due to the size of the lesion, normal aspect of the adjacent mucosa and intermittent bleeding, requiring multiple procedures. Endoscopic capsule, endoscopy and angiography are propaedeutic options. Endoscopic treatment includes local injection, ablation and mechanical therapy. Combined mechanical hemostasis therapy with sclerotherapy or ablative therapy are highly effective [1]. If endoscopic treatment fails, angiography with embolization and surgery may be used [1].

Potentially lethal [5], a Dieulafoy injury is difficult to diagnose. It should be considered at 50 and 70 years [6] with upper gastrointestinal bleeding of gastric origin [7]. Endoscopic treatment with epinephrine injection combined with mechanical ligation of the vessel, although the ideal therapy is unknown and dependent on the experience and technology available at each service [1]. In critically ill patients, under ventilatory and hemodialysis support, this approach seems to offer safe treatment. Studies addressing different therapies and long-term results [8], with persuasive casuistry, will indicate the ideal treatment.

Case Report

67-year-old male, with past medical history of hypertension, prostatectomy 20 days, and perirectal abscess treatment 10 days ago. Admitted to the hospital with melena in the last 3 days and hypotension (reversed with saline solution 0.9%). Laboratory tests: Hemoglobin 7.8 g/dL, platelet count 288,000/mm³, INR 1,1. Physical examination revealed mild epigastric pain, with no signs of peritoneal irritation, and pale mucosas.

Endoscopy performed on the intensive care unit (ICU) admission revealed mild erosive pangastritis, gastric ulcers Forrest III. He presented hypovolemic shock and acute renal failure, requiring mechanical ventilatory support, vasopressor use and hemodialysis. Five endoscopic procedures were performed, always with the same findings. The EDA of the 13th day of hospitalization showed clots in the gastric body which, after being aspirated, showed a pulsating active bleeding artery in the posterior wall of the gastric body (Figure 1).

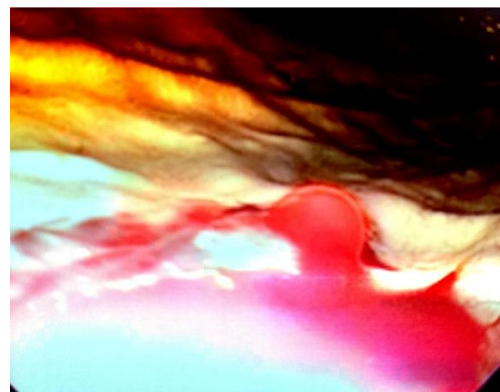


Figure 1: Pulsating active bleeding artery in the posterior wall of the gastric body.

Hemostasis with 1: 10,000 epinephrine solution was performed in the 4 quadrants of the lesion (2.5 mL/quadrant), with temporary

cessation of bleeding, which returned after the endoscopic clip was placed. Hemostasis was repeated with adrenaline, this time with interruption of bleeding, and another endoscopic clip was positioned, with resolution of the frame (Figure 2). Recovery of hemodynamic status after endoscopy, suspension of noradrenaline and stabilization of hematimetry. The patient was extubated the next day, maintaining adequate respiratory pattern. Another endoscopy did not reveal residual bleeding. ICU discharge occurred on 18th day of hospitalization.

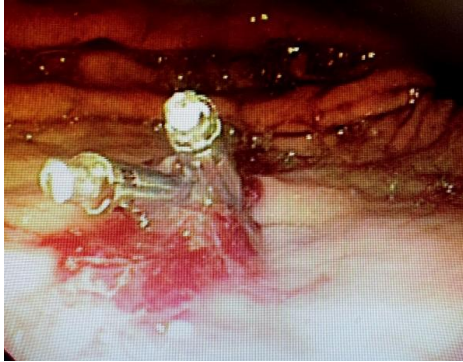

Figure 2: Another endoscopic clip was positioned.

Conclusion

The present report described the diagnosis, endoscopic treatment and the clinical evolution of an elderly critically ill patient stricken by

severe upper gastrointestinal bleeding and progression to hypovolemic shock and acute renal failure with the need for mechanical ventilation support and hemodialysis. Despite his critical clinical condition, the endoscopic chosen treatment proved to be satisfactory and life-saving.

References

1. Nojkov B, Cappell MS (2015) Gastrointestinal bleeding from Dieulafoy's lesion: Clinical presentation, endoscopic findings, and endoscopic therapy. *World J Gastrointest Endosc* 7: 295-307.
2. Jamanca-Poma Y, Velasco-Guardado A, Pinero-Pérez C, Calderón-Begazo R, Umaña-Mejía J, et al. (2012) Prognostics factors for recurrence of gastrointestinal bleeding due to Dieulafoy's lesion. *World J Gastroenterol* 18: 5734-5738.
3. M Baxter, EH Aly (2010) Dieulafoy's lesion: Current trends in diagnosis and management. *Ann R Coll Surg Engl* 92: 548-554.
4. Jeon HK, Kim GH (2015) Endoscopic Management of Dieulafoy's Lesion. *Clin endosc* 48: 112-120.
5. Scudiere JR, Cimbaluk D, Jakate S (2006) A 74-year-old man with fatal gastrointestinal bleeding. Ruptured Dieulafoy lesion or caliber-persistent artery. *Arch Pathol Lab Med* 130: 223-224.
6. Lee YT, Walmsley RS, Leong RWL, Sung JY (2003) Dieulafoy's lesion. *Gastrointest Endosc* 58: 236-243.
7. Scmulewitz N, Baillie J (2001) Dieulafoy lesions: A review of 6 years' experience of a tertiary referral centre. *Am J Gastroenterol* 96: 1689-1694.
8. Walmsley RS, Lee YT, Sung JY (2005) Dieulafoy's lesion: A case series study. *World J Gastroenterol* 11: 3574-3577.