

Rupture of an Intracranial Arteriovenous Malformation (AVM) in Pregnancy: Case Report

Rispoli R^{1*}, Donati L², Bartolini N³, Bolli L⁴, Sulis AM⁴, Zofrea G¹, Passalacqua GP² and Carletti S¹

¹Department of Neurosurgery, S. Maria Hospital, Terni, Italy

²Department of Gynecology, S. Maria Hospital, Terni, Italy

³Department of Neuroradiology, S. Maria Hospital, Terni, Italy

⁴Department of Neuroanesthesiology, S. Maria Hospital, Terni, Italy

Abstract

The rupture of an intracranial Arteriovenous Malformation (AVM) in pregnancy is a rare occurrence, but may have fatal consequences. A link between AVM rupture and pregnancy has been proposed; it may be caused by the increased cardiac output or circulatory effects of the elevated estrogen levels. Surgical intervention for ruptured AVM during pregnancy could prevent rebleeding, and allow for determination of the delivery method based on the obstetrical indications. Cooperation between neurosurgeons, obstetricians, and anesthesiologists and sufficient information about the treatment strategy given to the patients are essential. Here, we report the case of a 27-week-pregnant woman who presented with a symptomatic ruptured cerebral AVM, treated by cesarean section followed surgical resection.

Keywords: Pregnancy; Cesarean section; Arteriovenous malformation

Introduction

The rupture of an intracranial arteriovenous malformation (AVM) in pregnancy is a rare occurrence, but may have fatal consequences [1]. Hemorrhagic stroke is a serious complication during pregnancy and puerperium that has a substantial maternal mortality of 35% to 83%, contributing to more than 5% to 12% of all maternal deaths [2]. Recently, some studies reported the rate of intracranial hemorrhage from AVM was 8.1% per pregnancy, higher than the annual hemorrhage rate of AVM in female patients [2,3]. An aggressive approach is warranted, however, when pregnant patients present with a ruptured AVM.

The risk of re-bleed during the same pregnancy (27% to 30%) is greater than the risk of re-bleed in non-gravid women within one year of their initial bleed (6%). After AVM rupture during pregnancy, maternal mortality was 28% and fetal mortality was 14% [2,4]. Historically, ruptured AVMs in pregnant women have been managed surgically with great success [2,3,5,6]. Here, we report the case of a 27-week-pregnant woman who presented with a symptomatic ruptured cerebral AVM, treated by cesarean section followed surgical resection.

Case Report

A 23-year-old primipara at the 27th week of gestational age was admitted to the hospital with a sudden severe headache associated with nausea or vomiting.

Her past medical history was significant for a cerebral arteriovenous malformation partially embolized. Our patient's only physical exam finding was a left hemiparesis. Non-contrasted computed tomography of her head revealed an acute right fronto-temporal hemorrhage with mild mass effect (Figure 1). Magnetic resonance imaging (MRI) revealed a 5 Å-2.6 cm hematoma in the right fronto-temporal region abutting the ventricle with flow voids, characteristic of an AVM. Digital Subtraction cerebral Angiography (DSA) demonstrated that the nidus was being supplied by the posterior branches of her right middle cerebral, right anterior and posterior cerebral arteries (Figure 2A and 2B). Assuming that the radiation exposure for the groin and for the head is 30 seconds and 45 minutes, respectively, in a general endovascular procedure, the absorbed fetal dose was measured to be 2.8 mGy.

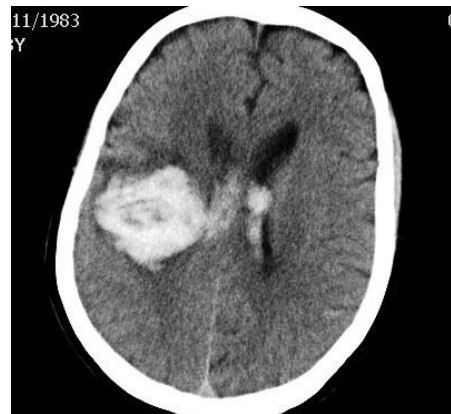

Figure 1: Non-contrasted computed tomography revealed an acute right fronto-temporal hemorrhage with mild mass effect.

The weights of the fetus were estimated to be 1756 g and we were expected premature. Discussions with obstetricians, neurosurgeons and neonatologists, anesthesiologists, encouraged us to schedule cesarean section followed by craniotomy under general anesthesia.

Obstetricians and gynecologists performed Cesarean section immediately followed by the removal of an intra-cranial hematoma under general anesthesia. A 1.9 kg girl was delivered after 10 minutes

***Corresponding author:** Rossella Rispoli, Department of Neurosurgery, S. Maria Hospital, Terni, Italy, Tel: +393331163632; Fax: +390744205424; E-mail: rossella.rispoli@libero.it

Received November 18, 2014; **Accepted** December 15, 2014; **Published** December 17, 2014

Citation: Rispoli R, Donati L, Bartolini N, Bolli L, Sulis AM, et al. (2015) Rupture of an Intracranial Arteriovenous Malformation (AVM) in Pregnancy: Case Report. J Stem Cell Res Ther 5: 256. doi:10.4172/2157-7633.1000256

Copyright: © 2015 Rispoli R, et al. This is an open-access article distributed under the terms of the Creative Commons Attribution License, which permits unrestricted use, distribution, and reproduction in any medium, provided the original author and source are credited.

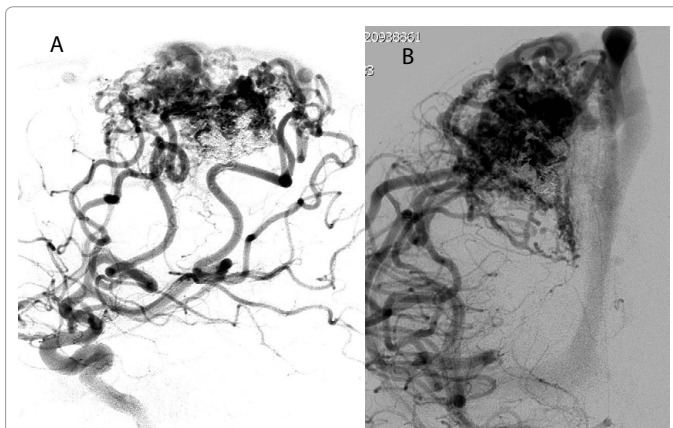


Figure 2A and B: Digital subtraction cerebral angiography demonstrated that the nidus was being supplied by the posterior branches of her right middle cerebral, right anterior and posterior cerebral arteries.

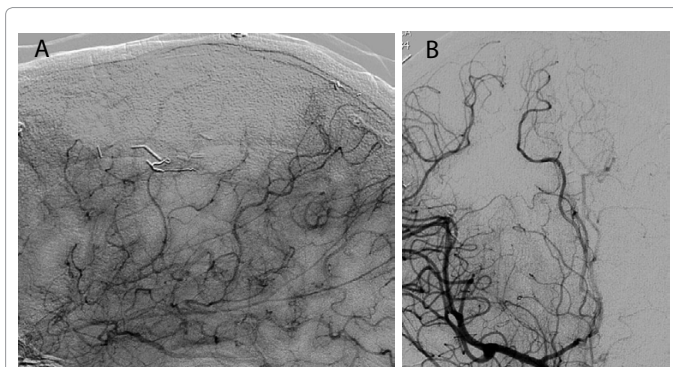


Figure 3A and B: Two days after surgery we performed a cerebral angiogram. The angiogram revealed complete resection of the AVM.

of induction. Baby was intubated and shifted to Neonatal Intensive Care Unit. Apgar scores were 2 at 1 minute and 9 at 5 minutes. The craniotomy was centered over the right fronto-temporal AVM and using the standard microsurgical technique we proceeded to safely and effectively resect the AVM; our patient was transferred to the neurosurgical intensive care unit.

One day after treatment we performed a cerebral CT that revealed the good evacuation of the hemorrhage. Two days after surgery we performed a cerebral angiogram (Figure 3A and 3B). The angiogram revealed complete resection of the AVM. Our patient recovered well with and was discharged home on postoperative day two.

Discussion

The prevalence of cerebral AVMs is estimated at 0.01-0.50% of the population. AVM is generally present in patients aged between 20 and 40 years, and is more common in those over 30 years, the child bearing age for women. The natural history of AVMs is poorly understood, and even less understood in pregnant patients, because the frequency is rare and changes in the maternal body are complicated during pregnancy. No definitive guidelines for the treatment of AVMs during pregnancy exist and the management of cerebrovascular disease in pregnancy is under discussion.

Cerebral arteriovenous malformations (AVMs) may affect the prognosis for both mother and fetus because they may result in fatal intracranial bleeding during pregnancy. Although the influence of

pregnancy on AVM rupture is controversial among investigators, in recent reports, the annual hemorrhage rate during pregnancy was 10.8%; the hemorrhage rate per pregnancy was 8.1%. The frequency of rebleeding during the same pregnancy period could be as high as 27%, which is 4 times higher than for the natural course of a ruptured AVM in the first year [2,6-10]. These risks associated with other risks typical of pregnancy (hypertension, increased age, coagulopathy, disseminated intravascular coagulation and recent use of vasoactive substances) may increase the likelihood of AVM hemorrhage. These risks can be eliminated only by excision of the AVM. The prognosis for the mother and fetus would improve if surgical resection of the AVM is safely performed.

Of these risk factors, our patient had untreated gestational hypertension, which is the single factor most closely linked with AVM rupture. Maternal management of patients with ruptured AVMs should be based mainly on neurosurgical indications rather than on obstetrical indications. When neurological deterioration occurs due to AVM rupture, emergency surgery is necessary. If the fetus is sufficiently mature, simultaneous cesarean section is possible. When there is no indication for emergency surgery for AVM, blood pressure management is important. However, this is not necessarily effective for the prevention of rebleeding because patients with ruptured AVM do not always have a history of hypertension. Although radical treatment tended to be performed after delivery in many case reports and case series, some authors suggested that early surgical intervention for AVM before delivery led to improved maternal and fetal prognosis.

Surgery for AVM is determined primarily by the Spetzler-Martin grading Scale [7]. A potential complication of surgery for AVM during pregnancy is the risk of intraoperative bleeding leading to deterioration of the uterine and placental circulation. Although preoperative embolization is possible for cases with a high risk of intraoperative bleeding, such as deep-seated AVMs, the endovascular treatment itself carries the risk of ischemic and hemorrhagic complications. In addition, there is not enough evidence to presume the safety of iodinated contrast agents which cross the human placenta and enter the fetus. The potential radiation risk and the potential added risks of contrast medium should be considered in the preoperative study. Previous reports of endovascular treatment for AVM during pregnancy are limited [8,9]; we know that fetal radiation effects are highly dependent on both administered dose and developmental stage at the time of exposure. During the first gestational week (0-8 days), a radiation dose of 100 mGy is believed to be lethal to the developing embryo. In the organogenesis period (2-8 weeks), normal maturation may be affected by 500 mGy. During the early fetal stage (8-15 weeks), the radiation dose threshold is estimated to be 120 mGy, whereas the safe limit is projected at 250 mGy in the mid-fetal stage (16-25 weeks). Beyond 25 weeks, the risks of physical deformity and mental retardation are believed to be minimal unless exposure levels exceed 500 mGy. There would be wider surgical indications by discussing the efficacy and risk more about endovascular treatment for AVMs during pregnancy.

Radical treatment for ruptured AVMs in patients with a mature fetus tends to be performed in the early postpartum period. It is desirable for patients with unruptured AVMs to undergo radical treatment before pregnancy due to the increasing risk of AVM rupture during pregnancy.

Prior to pregnancy, multimodal therapies such as direct surgery, endovascular embolization, and radiosurgery can be performed. In patients with unruptured AVMs diagnosed during pregnancy, conservative treatment is performed based on the risk of surgical treatment.

Conclusion

We achieved good maternal and fetal outcomes in our case. We performed the DSA before cesarean section because the neurological status of the patient aggravated and we had to know the architecture of the AVM to prevent intraoperative complications during the cesarean section and neurosurgical procedure. Assuming that the radiation exposure for the groin and for the head is 30 seconds and 45 minutes, respectively, in a general endovascular procedure, the absorbed fetal dose was measured to be 2.8 mGy. Therefore, the risks associated with endovascular procedures appear minimal considering the threshold dose mentioned above and the gestational week.

Surgical intervention for ruptured AVM during pregnancy could prevent rebleeding, and allow for determination of the delivery method based on the obstetrical indications. Cooperation between neurosurgeons, obstetricians, and anesthesiologists and sufficient information about the treatment strategy given to the patients are essential.

References

1. Perquin DA, Kloet A, Tans JT, Witte GN, Dörr PJ (1999) Intracranial arteriovenous malformations in pregnant women. *Ned Tijdschr Geneeskd* 143: 497-500. [PubMed]
2. Trivedi RA, Kirkpatrick PJ (2003) Arteriovenous malformations of the cerebral circulation that rupture in pregnancy. *J Obstet Gynaecol* 23: 484-488. [PubMed]
3. Fujita K, Tsunoda H, Shigemitsu S, Kubo T (1995) Clinical study on the intracranial arteriovenous malformation associated with pregnancy. *Nippon Sanka Fujinka Gakkai Zasshi* 47: 1359-1364. [PubMed]
4. Robinson JL, Hall CS, Sedzimir CB (1974) Arteriovenous malformations, aneurysms, and pregnancy. *J Neurosurg* 41: 63-70. [PubMed]
5. Couldwell SM, Kraus KL, Couldwell WT (2011) Regression of cerebral arteriovenous malformation in the puerperium. *Acta Neurochir (Wien)* 2: 359-362. [PubMed]
6. Schwartz J, Lynbrook NY (1951) Pregnancy complicated by subarachnoid hemorrhage. *Am J Obstet Gynecol* 62: 539-547. [PubMed]
7. Mounayer C, Hammami N, Piotin M, Spelle L, Benndorf G, et al. (2007) Nidal embolization of brain arteriovenous malformations using Onyx in 94 patients. *Am J Neuroradiol* 28: 518-523. [PubMed]
8. Natarajan SK, Ghodke B, Britz GW, Born DE, Sekhar LN (2008) Multimodality treatment of brain arteriovenous malformations with microsurgery after embolization with onyx: single-center experience and technical nuances. *Neurosurgery* 62: 1213-1225. [PubMed]
9. Panagiotopoulos V, Gizewski E, Asgari S, Regel J, Forsting M, et al. (2009) Embolization of intracranial arteriovenous malformations with ethylene-vinyl alcohol copolymer (Onyx). *Am J Neuroradiol* 30: 99-106. [PubMed]
10. Robinson JL, Hall CS, Sedzimir CB (1972) Subarachnoid hemorrhage in pregnancy. *J Neurosurg* 36: 27-33. [PubMed]