

Paraneoplastic Leukemoid Reaction in a Case of Carcinoma Gall Bladder: A Rare Scenario

Jeetendar Paryani^{*}, Sameer Gupta, Arun Chaturvedi, Vijay Kumar, Naseem Akhtar, Parijat Suryavanshi and Shashi Singh Pawar

Department of Surgical Oncology, King George's Medical University, Lucknow, India

^{*}Corresponding author: Dr. Jeetendar Paryani, Department of Surgical Oncology, King George's Medical University, Lucknow, India, T el: +917869313959; E-mail: drjeetendar2004@gmail.com

Received date: December 01, 2018; Accepted date: January 23, 2019; Published date: January 30, 2019

Copyright: ©2019 Paryani J, et al. This is an open-access article distributed under the terms of the Creative Commons Attribution License, which permits unrestricted use, distribution, and reproduction in any medium, provided the original author and source are credited.

Abstract

Paraneoplastic Leukemoid reaction may be defined as elevated WBC counts in association of solid malignancy when other causes like infection and hematological malignancies have been ruled out. The exact mechanism has not been fully elucidated. It is likely that various cytokines produced irregularly by the tumor cells, including granulocyte colony-stimulating factor (G-CSF), may underlie the pathogenesis.

We here describe a case report of a 68-year-old man with locally advanced gall bladder presenting with extremely elevated WBC count. Infection, leukemia, bone marrow involvement were ruled out. Patient underwent surgery and after resection counts normalized. Patient had recurrence few months later which was accompanied by raised TLC.

There are many studies associating this rare phenomenon with lung urothelial melanomas and other malignancies but not with gall bladder cancer making this extremely rare occurrence. Therapeutic strategies for the neoplasm, like surgical excision, chemotherapy, and radiotherapy, frequently result in a decrease in the white blood cell count. Nevertheless, in such patients, the leukemoid reactions have been reported to correlate with an aggressive clinical course, lower survival time, occurring shortly before death.

Keywords: Paraneoplastic; Leukemoid reaction; Gall bladder; Granulocyte colony-stimulating factor (G-CSF)

Introduction

Leukemoid reaction is defined as a white blood cell (WBC) count over 50,000/mm³ with a predominance of neutrophil precursors. When this elevation in the WBC count is associated with malignancy and infection or leukemia is ruled out it may be termed to be paraneoplastic leukemoid reaction [1].

The differential diagnosis of paraneoplastic leukemoid reaction includes infection, hematologic malignancy, iatrogenic origin (e.g. steroids, growth factors), solid tumor spread to bone [1,2]. Granger et al. studied the frequency of extreme leukocytosis in solid tumours and found it occurred in nearly 1-4% of the patients. The Paraneoplastic leukemoid reaction termed as diagnosis of exclusion was found in nearly 10% of the cases [2].

Case Report

A 68-year male patient was complaining of pain in abdomen since 2 and half month and lump in abdomen since 1 month. Abdominal examination revealed a gall bladder lump extending from right hypochondrium to right lumbar region measuring about 10 × 8 cm.

CBC revealed the following Hb-8.0 gm/dl. Total leucocyte count (TLC) was 82400 cells/mm³. Differential Count: 90.8% neutrophils, 3% lymphocytes, 5% eosinophils, 1% basophils. Repeat TLC were persistently high.

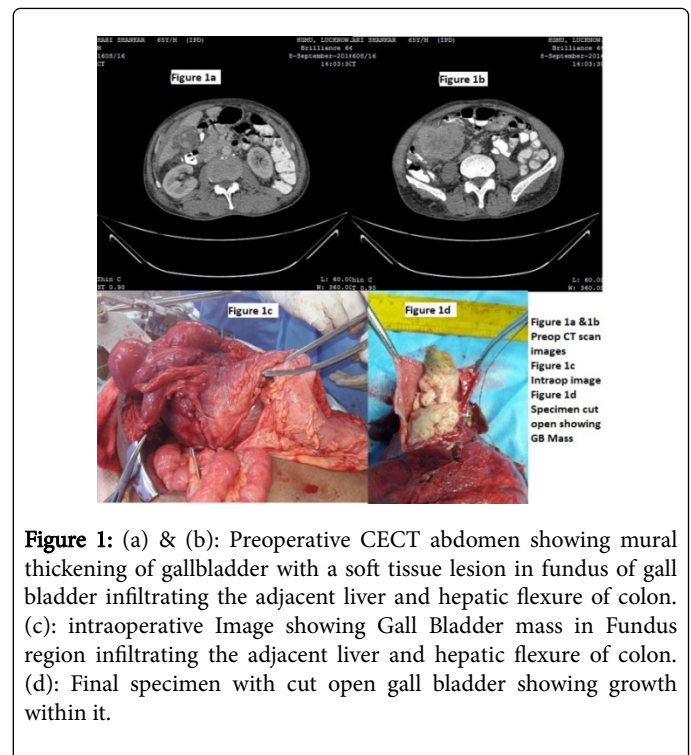


Figure 1: (a) & (b): Preoperative CECT abdomen showing mural thickening of gallbladder with a soft tissue lesion in fundus of gall bladder infiltrating the adjacent liver and hepatic flexure of colon. (c): Intraoperative Image showing Gall Bladder mass in Fundus region infiltrating the adjacent liver and hepatic flexure of colon. (d): Final specimen with cut open gall bladder showing growth within it.

Guided fine needle aspiration cytology (FNAC) of gall bladder mass was positive for malignant cells (Adenocarcinoma).

General Blood Picture/Peripheral Smear revealed TLC 90,000 with 96% neutrophils. Bone Marrow Aspiration showed granulocytic precursors increased with shift to right suggesting normal hematopoiesis with neutrophilic leucocytosis. Procalcitonin Level was within normal limit.

Patient was given adequate preoperative blood transfusion. Fitness was obtained for surgery and was planned the patient for exploratory laparotomy. Per-Operatively there was Gall Bladder mass in Fundus region infiltrating the adjacent liver and hepatic flexure of colon.

Patient underwent Radical Cholecystectomy with Right hemicolectomy with Illio-tranverse anastomosis with diverting loop ileostomy (Figure 1c). Final Histopathology revealed moderately differentiated Adenocarcinoma tumor Size of 10 × 9 × 9 cm (Figure 1d), infiltrating into liver and traverse colon Liver and bowel resection margins free. Lymph nodes free from disease Stage pT3N0 (III A). Three weeks after the surgery, the TLC came down to 9400/mm³. Patient was asked for adjuvant chemotherapy but patient defaulted from treatment.

Patient returned 4 months later with a scar site lump of 5 × 4 cm. Ultrasound abdomens was suggestive GB fossa mass and FNAC of scar was suggestive of recurrence. Blood investigations revealed hemoglobin 7.4g/dl with TLC of 92,000/mm³, unfortunately patient succumbed to the disease before starting of palliative chemotherapy.

Discussion

Extreme Leucocytosis in case of malignancy presents a diagnostic dilemma. It could represent a secondary infection, haemologic secondary malignancy, or bone marrow involvement with solid tumour. These reasons need to rule out before we term the condition as Paraneoplastic leukemoid reaction [2].

In this case we ruled out haematologic malignancy and bone marrow involvement by doing peripheral smear and bone marrow aspiration study. Procalcitonin levels were also normal as well there no other signs of secondary infection. Peripheral smear did not reveal any sign of haemolysis. There was no history suggestive of intoxication and corticosteroid use. Thus we ruled out the essential differentials to paraneoplastic reaction.

Granger et al. study is probably the largest study with respect to leukemoid reaction associated with solid malignancies consisting of 758 patients of which they reported about 10% due to paraneoplastic reaction. Lung cancer was the most common malignancy associated with the phenomena [2].

Ikuma et al. studied case of 227 patients of lung carcinoma and found 33 cases of paraneoplastic leukemoid reaction among them [3].

Urothelial malignancies have also been frequently been studied to be associated with this phenomena. A study by Mizutani et al. found that 9.5% of cases were found to have paraneoplastic leukemoid reaction [4].

This event is been also rarely been described in melanoma. Davis et al found 6 such cases in a series of 626 patients of malignant melanoma [5]. This is also been described in case of cervical cancer in response to chemotherapy and radiation [6] and also with a case of lung sarcoma [7].

Our extensive search of literature only one other case report described this event with gall bladder cancer which makes this extremely rare occurrence [8].

It was been frequently suggested in studies that the count of leucocytes is frequent indicator of tumor burden on patient and high counts often imply poor prognosis. Effective antineoplastic treatment of primary malignancy leads resolution of the counts in small percentage of patients, [2-4]. Some reports also suggest that counts can be used to monitor responses to chemotherapy and radiotherapy as well to detect recurrences in such cases [9]. We observed similar situation with our patient who presented with elevated counts which resolved to normal after being surgical treated. The phenomena presented again as patient had a recurrence.

Paraneoplastic leukemoid reaction is a unique challenge. Detailed clinical attention avoids misdiagnosis and missed diagnosis. Care should be taken to establish the difference between Paraneoplastic syndrome and other secondary causes.

References

1. Chakraborty S, Keenportz B, Woodward S, Anderson J, Colan D (2013) Paraneoplastic leukemoid reaction in solid tumors. *Am J Clin Oncol* 38: 326-330.
2. Granger JM, Kontoyiannis DP (2009) Etiology and outcome of extreme leukocytosis in 758 nonhematologic cancer patients: a retrospective, single-institution study. *Cancer* 115: 3919-3923.
3. Kasuga I, Makino S, Kiyokawa H, Katoh H, Ebihara Y, et al. (2001) Tumor-related leukocytosis is linked with poor prognosis in patients with lung carcinoma. *Cancer* 92: 2399-2405.
4. Mizutani Y, Okada Y, Terachi T, Takechi Y, Yoshida O (1995) Serum granulocyte colony-stimulating factor levels in patients with urinary bladder tumour and various urological malignancies. *Br J Urol* 76: 580-586.
5. Davis JL, Ripley RT, Frankel TL, Maric I, Lozier JN, et al. (2010) Paraneoplastic granulocytosis in metastatic melanoma. *Melanoma Res* 20: 326-329.
6. Nimieri HS, Makoni SN, Madziwa FH, Nemiary DS (2003) Leukemoid reaction response to chemotherapy and radiotherapy in a patient with cervical carcinoma. *Ann Hematol* 82: 316-317.
7. Jardin F, Vasse M, Debled M, Dominique S, Courville P, et al. (2005) Intense paraneoplastic neutrophilic leukemoid reaction related to a G-CSF secreting lung sarcoma. *Am J Hematol* 80: 243-245.
8. Kumar P, Chandra K, Madhok R, Nigam P (2013) Leukaemoid reaction (paraneoplastic syndrome) in adenocarcinoma of gall bladder. *J Assoc Physicians India* 61: 356-357.
9. Dukes JW, Tierney LM Jr (2009) Paraneoplastic leukemoid reaction as marker for transitional cell carcinoma recurrence. *Urology* 73: 928.e17-9.