

Case Report

Open Access

Papillary Carcinoma of Male Breast: The Uncommon Pathology of Breast Cancer

Ikhwan SM^{1*}, Shahidah CA², Mokhzani WM¹ and Zaidi Z¹

¹Department of Surgery, Universiti Sains Malaysia, Jalan Sungai Dua, 11800 Georgetown, Pulau Penang, Malaysia

²Department of Surgery, Kulliyah of Medicine, International Islamic University Malaysia, Jalan Sultan Ahmad Shah, 25200 Kuantan, Pahang, Malaysia

Abstract

Breast cancer in men is uncommon. It represents less than 1% of all cancer in men. The survival rates of breast cancer are similar in men and women. Papillary carcinoma of breast is an extremely rare form of breast cancer. It tends to affect older age group but had excellent prognosis.

Case Report

A 54 year-old Malay male presented with left breast swelling for 6 months duration associated with bloody nipple discharge. There were no constitutional symptoms. No family history of malignancy. Clinically, there was a 3 cm×4 cm left breast mass which was mobile and non tender. The nipple and overlying skin were normal. The lymph nodes in the axillary and supraclavicular fossa were not palpable (Figure 1).

Post operative ultrasound breasts and liver showed no sonographic evidence of other breast nodules or evidence of liver metastasis. Bone scan report also revealed no evidence of skeletal metastasis. Pre operative staging was T2N0M0 (early breast cancer) (Figure 2).

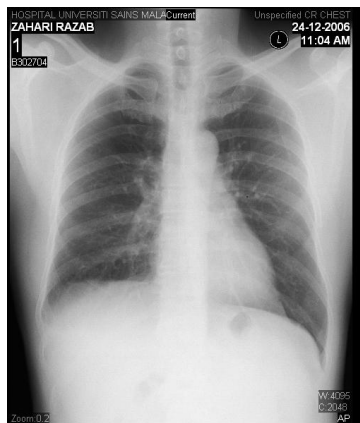


Figure 1: Chest X-ray showed no lung nodule.

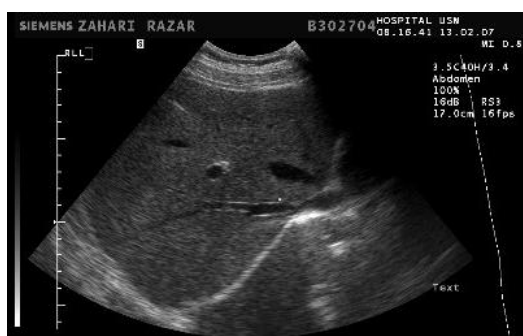

Figure 2: Ultrasound liver showed no liver lesion.

Fine needle aspiration cytology done showed proliferative lesion with high cellularity, highly suspicious of malignancy. He was then underwent left modified radical mastectomy and level II axillary clearance. Histopathology report confirmed the breast mass as papillary carcinoma with free surgical margin and, positive oestrogen-receptor (ER) and Progesterone Receptor (PR). Human Epidermal Growth Factor Receptor 2 (HER2) was negative.

He completed radiotherapy treatment for 20x but refused for chemotherapy. He also had completed Tamoxifen 20 mg/day for 5 years.

Discussion

Male breast carcinoma is a rare disease compared to female breast cancer. It accounts for 0.8% of all breast cancers and less than 1% of all cancers in men. It tends to affect older age group than females, peaks at age 59 years [1,2]. They presented usually at advanced stage than in women and thus carry a less favourable prognosis.

Similar to female breast cancer, genetic plays an important role for developing breast cancer. Positive family history of breast cancer and Klinefelter syndrome predisposed men to breast cancer [2-5]. In addition, majority of inherited breast cancer in men seem to be associated with BRCA2 mutations rather than BRCA1 mutation [2,3,5]. Hyperoestrogenisation resulting from gonadal dysfunction, obesity, or excess alcohol do increase risk of breast cancer in men (Figure 3).

Most of male breast cancer cases presented with breast lump or nipple inversion but often late with more than 40% of individuals having stage III or IV disease [3].

Nearly 90% of all breast cancer in men are invasive carcinomas and the remaining 10% are non-invasive [2]. 85% are infiltrating ductal carcinoma as normal male breast contains only ductal tissue

***Corresponding author:** Ikhwan SM, Department of Surgery, Universiti Sains Malaysia, Jalan Sungai Dua, 11800 Georgetown, Pulau Penang, Malaysia, E-mail: ikhwansani@yahoo.com.my

Received July 10, 2013; Accepted August 14, 2013; Published August 20, 2013

Citation: Ikhwan SM, Shahidah CA, Mokhzani WM, Zaidi Z (2013) Papillary Carcinoma of Male Breast: The Uncommon Pathology of Breast Cancer. Trop Med Surg 1: 140. doi:10.4172/2329-9088.1000140

Copyright: © 2013 Ikhwan SM, et al. This is an open-access article distributed under the terms of the Creative Commons Attribution License, which permits unrestricted use, distribution, and reproduction in any medium, provided the original author and source are credited.

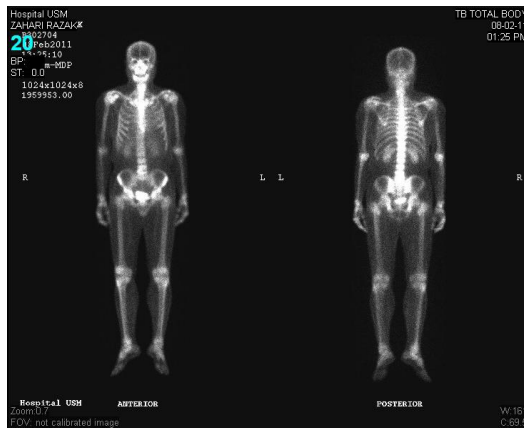


Figure 3: Bone scan showed no skeletal metastasis.

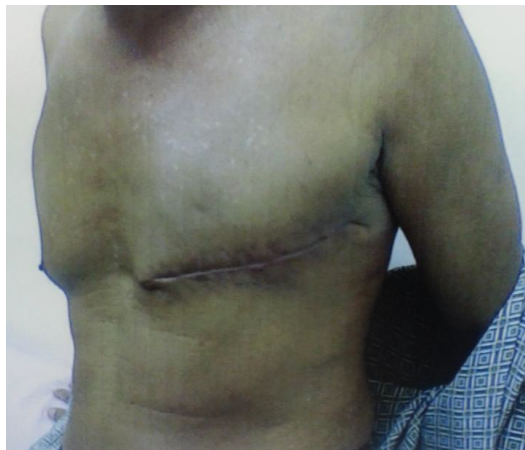

Figure 4: Post operative left mastectomy scar.

and does not contain lobules [6]. Most cases of male breast carcinoma are oestrogen-receptor and progesterone-receptor positive compared to women [2,4,6,7]. As in this case, both oestrogen and progesterone receptor are detected within the tumour.

Invasive papillary carcinoma is even rare condition and account for 5-7.5% of all male breast cancer [8,9]. It commonly occurs at older age group; however in this case, it developed in younger age. Papillary carcinoma has a good prognosis as compared to other histopathological subtypes. The 10-year survival rate is almost 100% and the recurrence-free survival rate is 96% at 2 years and 77% at 10 years [10]. Relatively, the survival rates by age and stage of disease for men and women were similar [1,4].

Surgical excision is the mainstay treatment for male breast carcinoma. Surgery is usually mastectomy with axillary clearance or sentinel lymph node biopsy [3]. Papillary carcinoma is associated with absence of axillary lymph node involvement and low recurrence rate [10]. Hence, wide local excision without axillary dissection is the treatment of choice for papillary carcinoma [10]. In this patient we choose to perform proper mastectomy in view of the tumour size (3-4 cm) which is huge in relation to breast tissue volume in men.

Indications for adjuvant radiotherapy, hormonal therapy and chemotherapy are similar to female breast cancer [4]. Almost 90% of

tumours are oestrogen-receptor positive, therefore male breast cancer usually responded well with hormonal treatment. Tamoxifen is used as standard adjuvant therapy.

We followed up this patient till today for minimum 5 years with annual ultrasound of the breasts and CT scan thorax/abdomen/pelvis (Figure 4).

Conclusion

Papillary carcinoma of male breast is an extremely rare entity with favourable prognosis due to low malignant potential. Treatment modalities in men are similar to women in managing breast cancer. Breast Conserving Surgery (BCS) is the treatment of choice in this type of tumour, however, mastectomy should be considered if BCS jeopardize the surgical oncology margin especially in men with small breast tissue volume. Tamoxifen is the mainstay of adjuvant treatment since most of this disease is oestrogen-receptor positive.

Chemoradiation is reserved for those who are in poor prognostic group or high grade tumours.

References

1. Giordano SH, Cohen DS, Buzdar AU, Perkins G, Hortobagyi GN (2004) Breast carcinoma in men: a population-based study. *Cancer* 101: 51-57.
2. Elshafiey MM, Zeeneldin AA, Elsebai HI, Moneer M, Mohamed DB, et al. (2011) Epidemiology and management of breast carcinoma in Egyptian males: experience of a single Cancer Institute. *J Egypt Natl Canc Inst* 23: 115-122.
3. Fentiman IS, Fourquet A, Hortobagyi GN (2006) Male breast cancer. *Lancet* 367: 595-604.
4. Giordano SH, Buzdar AU, Hortobagyi GN (2002) Breast cancer in men. *Ann Intern Med* 137: 678-687.
5. Weiss JR, Moysich KB, Swede H (2005) Epidemiology of male breast cancer. *Cancer Epidemiol Biomarkers Prev* 14: 20-26.
6. Demirci I, Barut AY, Aybar MD, Tuzcu G (2010) Papillary type breast cancer in men. *The Journal of Breast Health* 6: 26-29.
7. Berta S, Elizabeth M, Fatima C (2013) An update on male breast cancer and future directions for research and treatment. *European Journal of Pharmacology*: 1-13.
8. Arora R, Gupta R, Sharma A, Dinda AK (2010) Invasive papillary carcinoma of male breast. *Indian J Pathol Microbiol* 53: 135-137.
9. Solorzano CC, Middleton LP, Hunt KK, Mirza N, Meric F, et al. (2002) Treatment and outcome of patients with intracystic papillary carcinoma of the breast. *Am J Surg* 184: 364-368.
10. Sinha S, Hughes RG, Ryley NG (2006) Papillary carcinoma in a male breast cyst: a diagnostic challenge. *Ann R Coll Surg Engl* 88: W3-W5.