

## Moyamoya Disease in Childs and Adults: A Review of Surgical Treatment

Quintana LM\*

Faculty of Medicine, Department of Neurosurgery, School of Medicine, Valparaíso University, Chile

### Abstract

Moyamoya Disease is a chronic, cerebrovascular occlusive disease, in which the terminal portions of the intracranial internal carotid arteries and the initial segments of the middle and anterior cerebral arteries progressively become narrowed or occluded. Due to this phenomenon, reduced blood flow to the brain is produced, and tiny collateral vessels at the base of the brain enlarge to become collateral pathways. These vessels are called "Moyamoya vessels" because the angiographic appearance of these vessels resemble the "cloud" or "puff" of cigarette smoke, which is described as "moya-moya" in the Japanese language; also moya-moya is the Japanese word to describe a hazy appearance or an unclear idea about something.

**Keywords:** Moyamoya disease; Brain; Headache; Angiography

### Introduction

In 1950's, Japanese leading neurosurgeons at that time began to notice the new clinical entity of Moyamoya disease [1]. Since its etiology was unknown, it was named in various ways. Takeuchi and Shimizu described it as a hypoplasia of bilateral internal carotid arteries [2]. Later, Suzuki and Takaku described in detail the angiographic appearance and development of this disease<sup>1</sup> and gave it the name Moyamoya disease. Kudo named it officially as the Spontaneous occlusion of the circle of Willis [3] (Figure 1).

### Clinical Findings and Preoperative Assessment

Symptoms and signs of Moyamoya disease include brain ischemia and haemorrhage. Initial symptoms in Moyamoya disease, both juvenile (under 15 years old) and adult cases considered together, are most frequently motor disturbances. In the experience of Suzuki et al. [4] these were found in 36% of patients, followed by intracranial haemorrhage in 25%, headache in 20%, and convulsions in 6%. This is similar to the experience reported by Yamaguchi et al. [5], who reported motor disturbances in 62.7% of males and 53.8% of females, disturbances of consciousness in 28.1% of males and 34.6% of females, signs of meningeal irritation in 10.3% of males and 20.5% of females, and speech disturbances 16.7% of males and 14% of females. However, when these symptoms are studied with regard to age, large differences between juvenile and adult cases become apparent.

Among the juvenile cases, motor disturbances, including monoparesis, paraparesis, and hemiparesis are found in 60%, and in these juvenile cases, some 20% show motor disturbances indicative of transient brain ischemia [4].

If we also included other symptoms thought to be due to brain ischemia, such as sensory disturbances and mental and psychic disorders, then 85% of these juvenile cases show symptoms of brain ischemia. Intracranial haemorrhage was seen in only 4% of juvenile case [4].

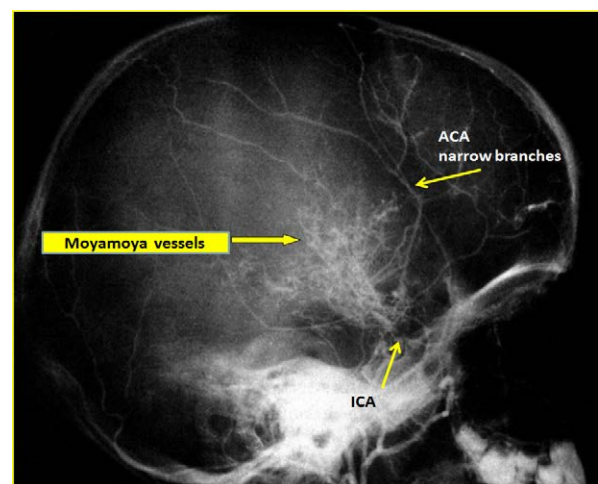
In other Japanese experiences [4,6,7], the onset of adult cases was accompanied by intracranial haemorrhage in 43% of patients, and symptoms due to brain ischemia [8,9], including motor, mental and psychic disturbances, were seen in 20% of these adult cases.

Moyamoya disease is basically diagnosed both by clinical symptoms and angiographic findings.

### Neuroimaging

X-ray computed tomography (CT): CT is useful to differentiate brain ischemia from brain haemorrhage in the acute stage. However, CT is not definitely diagnostic for Moyamoya disease. As a non-invasive mode of imaging, the following magnetic resonance and angiographic MRI imaging modalities are considered first line.

Catheter angiography: This method is essentially required for the diagnosis of Moyamoya disease and is the gold standard of the neuroimaging in this disease. However, catheter angiography has an



**Figure 1:** Lateral view, right carotid angiography showing Moyamoya vessels, supraclinoidal segment of ICA, MCA cannot be seen clearly and the ACA branches are extremely narrowed.

\*Corresponding author: Quintana LM, Faculty of Medicine, Department of Neurosurgery, School of Medicine, Valparaíso University, Chile, Tel: +56956483175; Fax: +56322683860; E-mail: [leonquin@gmail.com](mailto:leonquin@gmail.com)

Received June 05, 2015; Accepted February 01, 2016; Published February 10, 2016

Citation: Quintana LM (2016) Moyamoya Disease in Childs and Adults: A Review of Surgical Treatment. J Vasc Med Surg 4: 250. doi:10.4172/2329-6925.1000250

Copyright: © 2016 Quintana LM. This is an open-access article distributed under the terms of the Creative Commons Attribution License, which permits unrestricted use, distribution, and reproduction in any medium, provided the original author and source are credited.

inherent risk of cerebral infarction, drug allergy, etc, although the incidence is very low.

Magnetic resonance imaging (MRI) and magnetic resonance angiography (MRA): The widespread availability of MRI and magnetic resonance angiography as useful and safe imaging methods has led to the increasing use of these methods for primary imaging in patients with symptoms suggestive of Moyamoya [10-12].

An acute infarct is more likely to be detected with the use of diffusion-weighted imaging, whereas a chronic infarct is more likely to be seen with T1- and T2-weighted imaging. Diminished cortical blood flow due to Moyamoya can be inferred from fluid-attenuated inversion recovery (FLAIR) sequences showing linear high signals that follow a sulcal pattern, which is called the "ivy sign" [13].

The finding most suggestive of Moyamoya on MRI is reduced flow voids in the internal, middle, and anterior cerebral arteries coupled with prominent flow voids through the basal ganglia and thalamus from Moyamoya-associated collateral vessels. These findings are virtually diagnostic of Moyamoya [14], and also called "the sign of termite nest" [15].

When we search for the classical findings of Moyamoya disease, studies, catheter angiography and MRA, show the terminal portions of the intracranial internal carotid arteries and the initial segments of the middle and anterior cerebral arteries progressively become narrowed or occluded. According with the report by Suzuki et al. [1] that named this disease, tiny collateral vessels at the base of the brain enlarge to become collateral pathways. These vessels are called "Moyamoya vessels" because the angiographic appearance of these vessels resemble the "cloud" or "puff" of cigarette smoke, which is described as "moyamoya" in the Japanese language.

Suzuki and Takaku [1] classified the development of Moyamoya disease into 6 stages. According to this classification, many patients fall into stage 3. Fukuyama and Umezumi [16] then further divided stage 3 into 3 subdivisions: 3a, 3b and 3c.

Stage 1: Narrowing of carotid fork.

Stage 2: Initiation of the "Moyamoya vessels", dilatation of the intracerebral main arteries.

Stage 3: Intensification of the "Moyamoya vessels", non-filling of the anterior and middle cerebral arteries.

3a: partial non-filling of the anterior and middle cerebral arteries.

3b: partial preservation of the anterior and middle cerebral arteries.

3c: complete lack of the anterior and middle cerebral arteries.

Stage 4: Minimization of the "Moyamoya vessels", disappearance of the posterior cerebral artery.

Stage 5: Reduction of the "Moyamoya vessels", the main arteries arising from the internal carotid artery disappear. Stage 6: Disappearance of the "Moyamoya vessels", the original Moyamoya vessels at the base of the brain are completely missing and only the collateral circulation from the external carotid artery is seen (Figure 2). Inconveniences of this classification are as follows: Many cases belong to stages 3-5, especially to stage 3. There are few cases in stages 1 and 6. Stages of Moyamoya disease are not strongly related to clinical symptoms. In stages 1 and 6, there are no Moyamoya vessels on cerebral angiography, which are not Moyamoya disease by definition. There are some doubts that there is really vascular dilatation in stage 2.

Progression of angiographic stages is commonly observed in children, but in adults many patients often remain in the same stages. However, when there is good correlation between the clinical picture and the imaging above presented, this angiographic classification is useful.

To examine in greater detail CBF, positron emission CT or single photon CT, or xenon inhalation CT are commonly used. Recently, perfusion x-ray CT and MRI with contrast materials have been used for this purpose [17,18].

## Treatment

### Emergency treatment

In the acute stage, the treatment is the same as for brain infarction or spontaneous intracerebral haemorrhage due to other etiologies [19].

In the case of ventricular haemorrhage, an external ventricular drainage operation is performed if the patient presents in acute evolution with signs of intracranial hypertension [20,21].

In the case of intracerebral haemorrhage (ICH), initial medical treatment is indicated if the haemorrhage totals less than 25 cc in volume. If the hemorrhagic volume totals more than 25 cc, is associated with a lobar topography, and demonstrates mass effect over the midline structures, then surgical evacuation is indicated [20]. Frequently in patients with ICH, infusion of osmotic agents to control the intracerebral pressure and edema, as well as administration of anti-convulsants to control seizures, is also required [21].

It is not indicated to perform by-pass surgery in the acute stage of the disease [19].

### Treatment in the chronic stage

**Patients with cerebral ischemia:** There is no consensus on medical treatment with aspirin, other anti-platelet agents, anticoagulants, vasodilators, or corticosteroids to prevent future ischemic attacks in patients with chronic disease [22].

**Surgical anastomosis:** In order to eliminate ischemic symptoms or to prevent recurrent ischemic stroke, bypass surgery is accepted as the treatment of choice. Site of the by-pass is also determined occasionally by the results of the examination of cerebral blood flow. ( $Xe^{133}$ -CT Scan, SPECT, PET Scan) [2,3].

The rationale to initiate some form of revascularization is as follows:

**Clinical picture:** Already described, mainly different forms

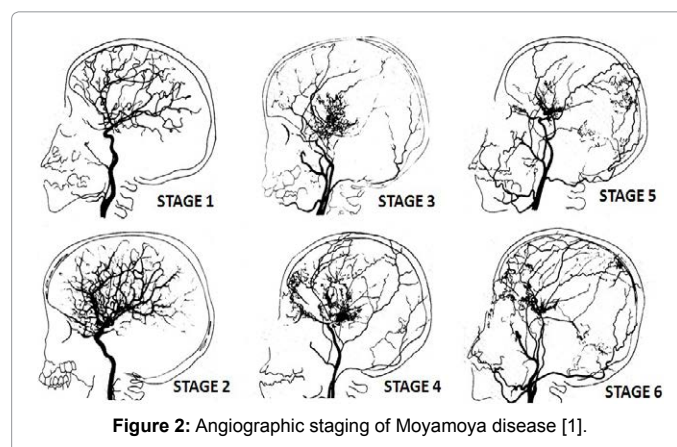


Figure 2: Angiographic staging of Moyamoya disease [1].

of ischemic stroke in children (Juvenile cases), haemorrhagic and ischemic stroke in young adults.

**Laboratory studies:** The following studies may be indicated in patients with Moyamoya disease: In a patient with stroke of unclear etiology, a hypercoagulability profile may be helpful. Significant abnormality in any of these is a risk factor for ischemic stroke: Protein C, Protein S, Antithrombin III, Homocysteine, Factor V Leiden. Erythrocyte sedimentation rate (ESR) can be obtained as part of the initial workup of a possible vasculitis. However, a normal ESR does not rule out vasculitis.

**Imaging studies:** Cerebral angiography is the criterion standard for diagnosis. The following findings support the diagnosis:

1. Stenosis or occlusion at the terminal portion of the internal carotid artery or the proximal portion of the anterior or middle cerebral arteries. Abnormal vascular network in the vicinity of the occlusive or stenotic areas.

2. Bilaterality of the described findings (although some patients may present with unilateral involvement and then progress). Magnetic resonance angiography (MRA) can be performed. Any of these findings on MRA may preclude the need for conventional angiography.

3. One very important clinical finding is the presence of Moyamoya vessels at the angiographic study or MRA, correlated with the clinical picture already described. The moya vessels only are present when the patient is suffering a chronic brain ischemia, and these vessels are representative of the development of collateral ways for the cerebral blood flow to the ischemic brain [22].

Vascular anastomosis is classified as direct or indirect. In direct anastomosis, the superficial temporal artery (STA) in the scalp is dissected and anastomosed with the middle cerebral artery (MCA) on the brain surface under microsurgery. This surgical technique gives the patient a high cerebral blood flow (CBF) immediately after the surgery [23-26]. However, in this disease the diameters of the cortical arteries are very small, and the anastomotic technique requires for its proper implementation cortical arteries of at least 1 millimeter in diameter.

In the indirect anastomosis, the periosteum, dura mater or a slice of the temporal muscle is placed over the brain surface, in anticipation of the development of new spontaneous anastomoses between extra and intracranial circulation. Some period is required to establish such anastomoses that also function with utility. Thus, the brain parenchyma is provided by collateral circulation through these structures, the STA, deep temporal artery, middle meningeal artery and anterior meningeal artery. During the surgical technique (synangiosis), these arteries must be preserved. In some cases, and to ensure close contact between the STA and galea surrounding the cerebral cortex, the extirpation of the piamater is done in zones or “windows”, suturing the edges of the galea to the piamater [27]. While using these indirect techniques, a high increase of cerebral blood flow does not develop immediately; early revascularization is frequently observed between 3 to 6 months following the intervention, especially in cases that course with cerebral ischemia.

It is common to add an indirect bypass more or less when a direct bypass is scheduled. In other situations [23], multiple burr hole surgery is performed, in which multiple small holes are made on the skull bone, in anticipation of the development of spontaneous anastomoses [28,29]. Another less frequent surgery is omental transplantation [30] and omental transposition [31].

In Moyamoya disease, usually both cerebral hemispheres are ischemic, thus bypass surgery is required bilaterally. First, one-sided operation for the hemisphere that is more ischemic is performed, and then bypass surgery for the opposite side is scheduled in two or three months.

The indirect revascularization techniques most widely used are the Encephalo-duro-arterio-synangiosis (EDAS) and the Encephalo-myo-synangiosis (EMS) [32-34]. There are from the paper of T. Matsushima [35], such techniques were reviewed and are summarized in Table 1.

**Patients with intracerebral haemorrhage:** It has been reported that the ICH occurs as a consequence of a hemodynamic overload over the small collateral arteries of neovascularization, the “Moyamoya vessels”, with terminal circulation in the deep zones of the brain in the vicinity of the ventricular wall. However, in these hemorrhagic cases, the advantages of the surgical treatment using direct or indirect bypass with the surgical technique that will be described has yet to be proven. In these hemorrhagic cases, the patients suffering systemic hypertension must be treated with anti-hypertensive drugs, and platelets antiaggregants are not indicated.

**Surgical techniques:** We will describe the most used surgical techniques for this disease which have shown the best results. This includes one direct technique and six indirect techniques.

In relation to general surgery, patients are positioned with the head above the heart atrium to reduce the cerebral venous congestion. Hyperventilation and alpha-adrenergic drugs are not recommended for their vasoconstrictor effect, but moderate hypothermia (32-34°C) and barbiturates, or anesthetics like propofol, are used for cerebral protection during times of temporary arterial occlusion according to the local anesthesiologist’s experience. Mean blood pressure should be maintained at normal or slightly elevated parameters (90-100 mmHg), and plasma expanders should be used intraoperatively to prevent any ischemic event. Intraoperative monitoring with EEG and/or somatosensory evoked potentials allows the detection of ischemic changes in early stages, using the drugs mentioned above. The operating microscope and microsurgical instruments are used routinely in revascularization procedures.

Donor vessel (the STA) should be selected with an external diameter not less than 1 mm because vessels of smaller diameter have a high percentage of occlusion, deliver a low blood flow, are not useful, and are more difficult to anastomosed [23-26]. To prevent mechanical vasospasm, it is useful to apply topical diluted papaverine or nimodipine.

The patient is placed on the operating table with the head rotated toward the contra lateral side and the temporal bone is parallel to the floor, kept in position by the head holder with three points. After the scalp is shaved, the standard Doppler ultrasound is used over the donor

S o.	Table
1	Procedures using scalp artery
2	Procedures using galea
3	Procedures using dura meter
4	Procedures using temporal or other muscles
5	Procedures using omentum
6	Procedures using the combination of the above
7	Direct and indirect anastomoses combined

**Table 1:** So many modes of indirect anastomoses in Encephalo-duro-arterio-synangiosis (EDAS) and the Encephalo-myo-synangiosis (EMS).

artery and correlated with the preoperative angiography to locate the most suitable branch of the STA. The skin is painted with its branches using a marker pen. Usually there are 2 branches of the STA, the frontal and parietal. Both must be marked during the proceedings (Figure 3).

## Direct Bypass Surgery

### Superficial temporal artery - Middle cerebral artery (STA-MCA)

The first by pass STA-MCA as treatment for Moyamoya Disease, and other ischemic cerebrovascular pathologies, was performed in 1972 by Yasargil [24], and since then, several clinical series have been communicated showing good results in the immediate post-operative period with an isolated direct surgical technique[25,26] or combined with other indirect revascularization techniques [23,35].

After sterile preparation, an incision is made beginning on the zygoma with a scalpel No15; the STA is identified and skeletonized using smooth dissection, both with the scalpel and scissors tips. When necessary, a Doppler device is used to check the correct path of the STA, either the frontal or parietal branch are used, depending on the diameter and length, preferably using the larger diameter branch, with the occasional exception of a wider frontal branch passing very low over the forehead. It is advisable to leave a sleeve of collagen tissue support around the artery to avoid injury, decreases the mechanical vasospasm of the artery and allowing the surgeon to handle the vessel without damaging the artery walls. Small side branches are coagulated with bipolar and cut. The length of the artery required depends on the distance from the origin of the visible STA to the bypass site. The artery is separated and protected. Next a supero-medial temporal craniotomy of least 4 centimeters of diameter is created crossing the antero-posterior projection of the sylvian fissure.

The duramater is opened widely relative to the craniotomy, and the microscope is installed to select the recipient artery, which should ideally have an outer diameter of 1 mm or more. We must also take into account the orientation of the recipient artery and the location of the branch of the MCA in relation to the sylvian fissure. As closer branches allow better blood flow back to the internal carotid artery bifurcation, it is best to choose an M3 branch emerging from the sylvian fissure. The exposure of the recipient vessel is performed with a meticulous dissection of the surrounding arachnoid membrane, over a segment from 6 to 10 mm in length, around the direction of the artery. Small collaterals that emerge from the recipient artery are coagulated and cut. It is preferable to place a small piece of plastic underneath the elected branch of the MCA increasing the visibility in a good operating field.

A temporary clip is secured to the proximal segment of the STA and the distal end is cut, the blood flow of the STA can be evaluated by temporarily releasing the clip. Next, irrigate the lumen of the STA with heparinised saline to prevent clot formation inside the lumen artery. The distal portion of the STA is confronted and adapted to the appropriate length to reach the recipient artery without tension. Next, distal cuff of connective tissue around the artery is removed in a long, approximately 3 to 5 mm piece, preparing this segment for anastomosis. The distal end of the STA is cut in oblique form. Then microclips are installed on each side of the dissected segment of the recipient artery, and then a diamond-shaped incision of the wall is made using microsurgical scissors.

Subsequently, under a microscope, the anastomosis is performed using 10-0 monofilament suture. Sutures are placed first at the corners of the diamond-shaped incision and then five interrupted sutures are

placed over the distal wall edges. The procedure is repeated with five interrupted sutures over the nearest wall. Always include the intima in the suture to avoid any increased tension at the sutured site (Figure 4).

We recommended using interrupted sutures [23,24,36,37], but some authors prefer a continuous suture [38]. Proceed to remove the first distal clip and then the proximal clip of the recipient artery. Finally, the temporary clip on the STA is removed. Classically, it is recommended that the time of temporary clipping of the recipient artery should be no more than 30 minutes. After removing the clips, cottonoids are applied with gentle pressure on the site of the anastomosis. If there is some point in the anastomosis with a higher rate of bleeding, then an additional suture must be placed. Minor oozing usually ceases with Surgicel (vegetal oxidized cellulose mesh, Ethicon®) and pressure on the anastomosed site. Once the anastomosis is complete, Doppler can be used to examine anastomotic patency.

Proceed to suture the dura mater carefully to avoid narrowing of the STA. The bone plate is replaced so as to prevent any pressure on the STA. Finally, the temporal is muscle, galea, and skin are sutured in the conventional manner.

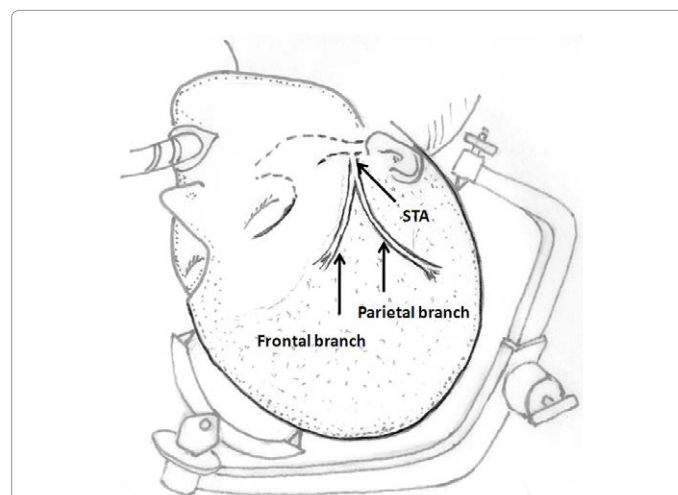


Figure 3: Position of the patient's head, the patient is placed on the operating table with the head rotated toward the contra lateral side, the temporal bone parallel to the floor and kept in position by the head holder with three points.

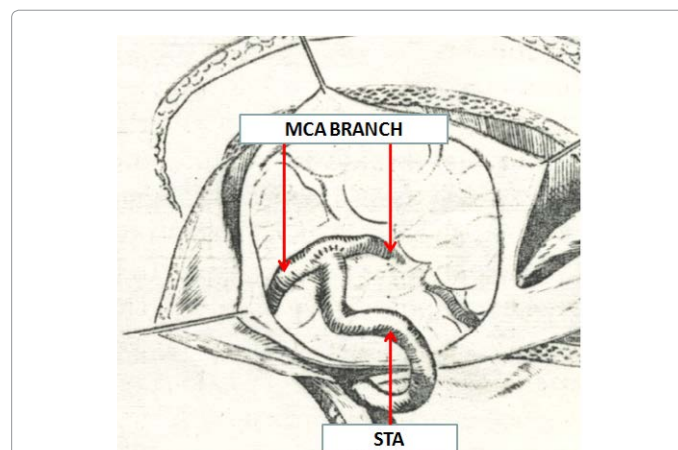


Figure 4: Classic anastomosis superficial temporal artery-middle cerebral artery branch.

In the immediate post-operative stage, hemodynamic monitoring is critical. The main complications of this procedure are intracranial hypertension and increased cerebral perfusion, which can cause leakage between nodes of the anastomosis and consequently a subdural hematoma at the site of the bypass. Conversely, hypotension may cause occlusion and ischemia, triggering a clinical complication that requires an emergency angiography and review of the bypass surgery. Another extremely rare but potential complication is cerebrospinal fluid fistula, which may occur if the dura is not closed under appropriate tension. On the first postoperative day, one may restart aspirin as a form of platelet antiaggregant therapy.

## Indirect Bypass Surgery

### Encephalo-duro-arterio-synangiosis (EDAS)

The EDAS, described by Matsushima et al. [23,27] is an alternative to the STA-MCA bypass. EDAS is an indirect way to increase collateral blood flow to the ischemic brain. This indirect technique does not increase cerebral blood flow immediately. Rather, indirect techniques are most often used in cases of cerebral ischemia and are associated with revascularization between 6 to 12 months following intervention, especially in cases that occur with cerebral ischemia [15,23,32,33,35].

In this surgical technique, the STA is dissected, as in the technique described above, but the vessel is left in continuity, not sectioned. Then, an incision is made over the temporalis muscle. A diamond-shaped or biconvex craniotomy is performed with 2 holes using an automatic drill and with the directionality of the craniotomy site mirroring the direction of the underlying STA.

Taking care to not damage vessels of the extra-intracranial collateral circulation, some authors advocate creating little windows [18,31] in the dura mater and pia-arachnoid to allow for greater, closer contact between the area of the STA and the cerebral cortex.

Next, the cuff of connective tissue surrounding the STA is sutured to the edges of the dura mater with monofilament 5-0 interrupted sutures. It is necessary to be careful that the path of the artery, sutured to the dura mater, is not curved on the edges of the craniotomy, which must be lowered to prevent this complication. Topical papaverine may be used to prevent mechanical vasospasm and Doppler imaging can be used once the craniotomy has been repositioned to verify that there is adequate distal flow through the artery. After fixation of the craniotomy, the temporalis muscle, galea, and skin are sutured in a conventional manner (Figures 5 and 6).

The authors advocate that in the EDAS temporary clipping over the branches of the MCA is not required. The extra-intracranial spontaneous anastomoses that develop through the dura mater generally have good patency, and this procedure is technically much easier to perform than the STA-MCA procedure [32,33,15]. Furthermore, EDAS can be performed in cases where a donor or recipient artery of appropriate size is not available, which may occur as a function of the underlying disease.

Matsushima et al. reported their results treating Moyamoya disease in 38 pediatric cases (70 hemispheres), and in his experience, 100% of revascularization was obtained, with most patients showing improvement in their symptoms due to cerebral ischemia [32,33].

### Encephalo-myo-synangiosis (EMS)

In the Encephalo-myo-synangiosis, a flap of the temporalis muscle

is sutured to the edges of the dural surgical opening so that the muscle is positioned closer to the brain surface.

As in the EDAS, a fronto-temporal craniotomy is performed and the arachnoid over the brain surface in question is opened as widely as possible. Next, the edges of the dura mater are sutured to the edges of the muscle flap.

Neovascularization occurs from muscle to the brain parenchyma, providing greater collateral blood flow to the brain. As in the EDAS, the EMS is technically simpler to perform than the direct STA-MCA bypass and does not require identification of a recipient artery. Additionally, the EMS can be combined with a direct STA-MCA bypass in some patients [23,35] (Figure 7).

However, this procedure has been associated with an increased risk of some patients to developing an epileptogenic focus [23,34,35]. Yet, several series have shown that EMS improves the clinical condition of

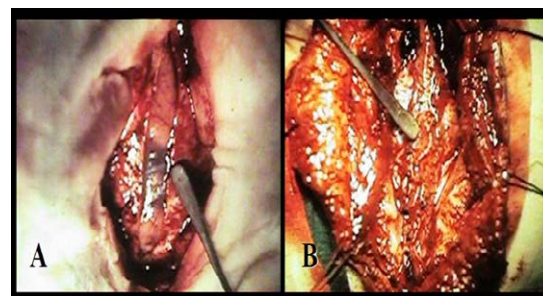


Figure 5: EDAS. A) Dural opening B) Suture of STA with galea edges to the edges of the dura.

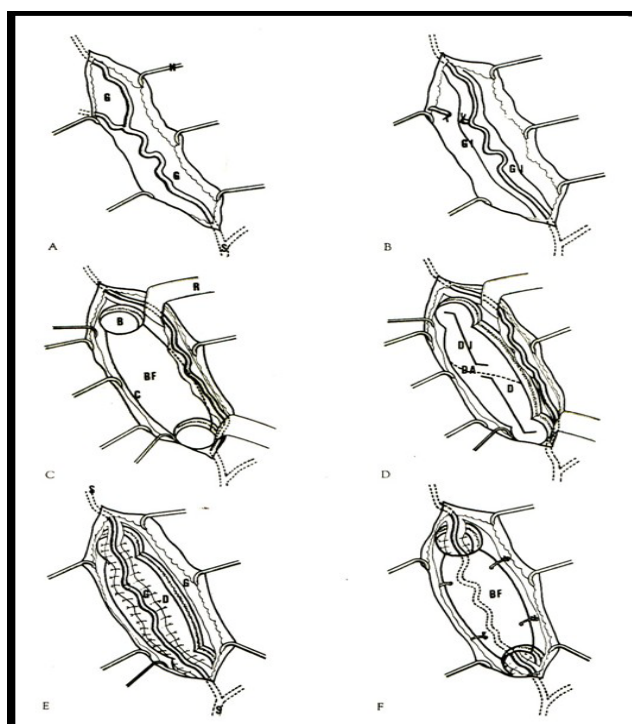


Figure 6: Shows the stages of EDAS [32].

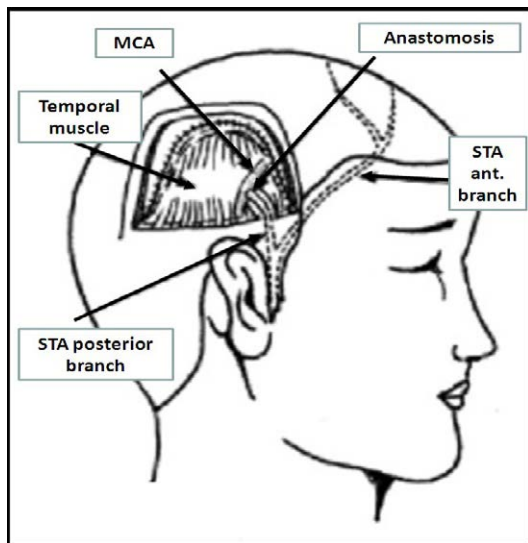


Figure 7: EMS, Diagram shows the temporal muscle flap sutured to the edges of the dura and an STA-MCA anastomosis [23].

patients and promotes revascularization in the region of the MCA in 70 to 80% of all patients [26,34].

### EDAS plus encephalo-galeo-synangiosis (EGS)

The EDAS is performed according to the technique described by Matsushima and Inaba [33]. This surgery is performed in 2 stages, initially on the more hemo dynamically affected cerebral hemisphere, with an average time between the first and second procedure being 6 to 8 months. To further increase collateral circulation in the territory of the anterior cerebral arteries, EDAS is performed with encephalo-galeo-synangiosis (EGS) in the bifrontal region as detailed below [38].

The scalp is incised twice, once for the EDAS and again for the EGS. At the site of the EGS, an elongated S-shaped, 2-cm incision is made anterior to the coronal suture. Then, the galea and/or the periosteum are dissected and are incised in a Roman S-shape in the anteroposterior direction, like a zigzag.

A craniotomy is performed of approximately 4 to 8 cm in length, crossing the superior longitudinal sinus. Then, the dura mater is incised in both hemispheres, with two separate flaps down to the venous sinus. Next, the arachnoid surface is removed to expose the underlying brain. Galeal flaps and/or periosteum is overlaid on the cerebral cortex and inserted into the deepest possible interhemispheric fissure, suturing it to the dura mater.

Finally, the craniotomy is fixed, and the skin and galea are closed via a conventional technique [39] (Figure 8).

### Revascularization using Omentum

The omentum can be surgically used as a traditional flap nourished by the gastroepiploic vessels directly or as a free flap, autotransplanted and vascularized from arteries and veins of the scalp. In both cases, the omentum is obtained through a median supraumbilical laparotomy.

### Omental transplantation

A median supraumbilical laparotomy with careful dissection and isolation of the gastroepiploic artery and vein exposes the omentum and preserves the vascular gastroepiploic pedicle.

The omentum is separated from its vascular pedicle immediately before the autotransplantation to preserve omentumal perfusion as long as possible. The autograft is preserved wet. The gastroepiploic artery and vein are sectioned and irrigated with heparinized saline to prevent intraluminal thrombosis.

The STA (or the occipital artery) are dissected as described above. For omentumal transplant, however, one must dissect the superficial temporal vein (STV) (or occipital vein). A craniotomy is performed over the region where the revascularization is desired.

Using microsurgical techniques, end-to-end anastomoses or end-to-side anastomoses between the STA (or occipital artery) and the gastroepiploic artery, as well as between the STV (or occipital vein) and the gastroepiploic vein are established, using 10-0 monofilament suture. First, arterial anastomosis is performed. Next, a temporary clip is placed on the donor artery during venous anastomosis. After this set of anastomoses has been secured, the omentum is spread over the cerebral surface and under the edges of the exposed dura mater. The graft is sutured to the edges of the dura mater, and the craniotomy plate is fixed, taking care not to compress the vascular pedicle [30] (Figure 9).

### Omental transposition

This surgical technique involves extending the omentum in order to reach the skull, while it remains attached to its natural vascular pedicle. Advantages to such an approach include preserving lymphatic drainage and avoiding an additional vascular anastomosis. The omentum's gastroepiploic pedicle is left to its normal anatomy and the omentum is able to reach the skull by dividing the elongated omentum with incisions in the form of an "L" (Figure 10).

The omentum is then tunneled subcutaneously, passing through the subcutaneous chest, neck, and scalp, including behind the ear. The omentum, with its pedicle, must not be under tension after the tunneling, nor should it be angled in any segment of the subcutaneous tunnel. Thus, several incisions are made in the skin along the tunnel to

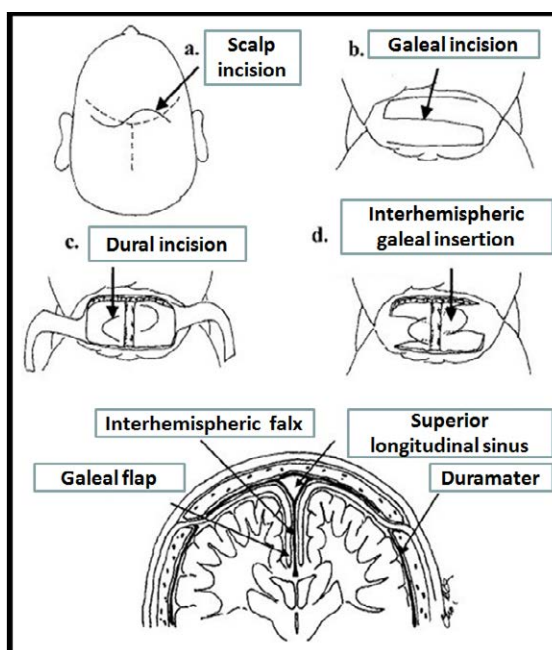
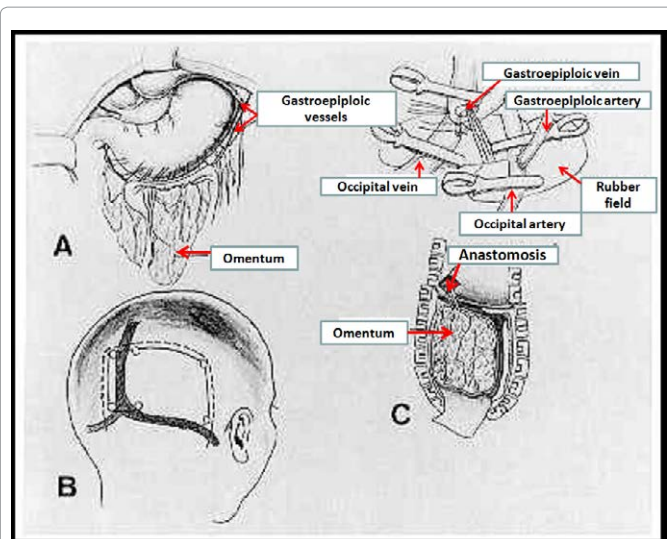
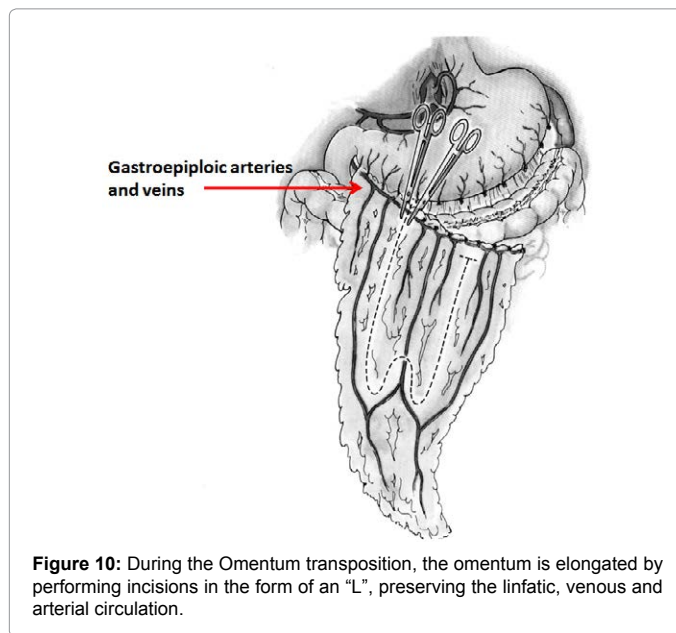


Figure 8: EDAS and-encephalic galeosinangiosis [39].



**Figure 9:** Omentum auto graft, exhibit A) Piece of a graft with omentum. B) Occipital Craniotomies right with region to be treated. C) Anastomosis of gastroepiploic artery and vein to occipital artery and vein.



**Figure 10:** During the Omentum transposition, the omentum is elongated by performing incisions in the form of an "L", preserving the linfatic, venous and arterial circulation.

facilitate graft passage. Once inside the skull, the omentum is placed on the brain surface under the edges of the exposed dura mater. The graft is sutured to the edges of the dura mater, and the craniotomy plate is fixed, taking care not to compress the vascular pedicle [31] (Figure 11).

### Multiple burr-holes operation

This operation is performed under general anesthesia and is technically similar to the creation of burr holes for the placement of external ventricular drainage systems.

To avoid injury to the STA over the burr holes, the trajectory of the STA is located by Doppler. After creating four to six burr holes over each cerebral hemisphere, the dura mater and arachnoid are widely opened, preserving the meningeal arteries with the use of a microscope.

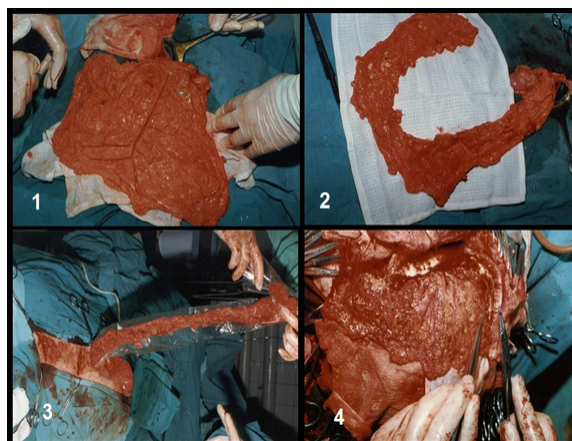
Then, the skin is sutured tightly closed with 2-0 monofilament [28,29] (Figure 12).

### Surgical Complications

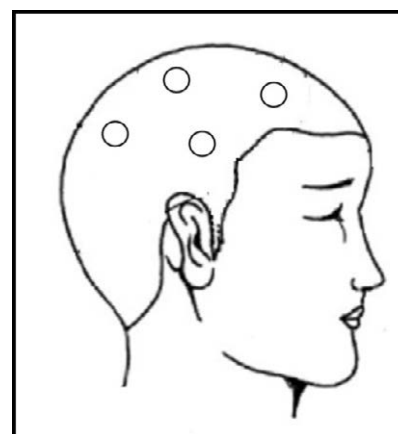
With the reviewed surgical techniques, the incidence of surgical complications is very low; however, the incidence of complications is not zero. Postoperative complications include bleeding from the surgical site (subcutaneous, epidural, subdural, and intracerebral), anemia, cerebral infarction (due to perioperative hypotension, hypocapnia due to hyperventilation, and prolonged, temporary clipping of arteries), transient ischemic attacks, scalp necrosis, surgical wound infection, and convulsive seizures [19,23,33,35].

The benefits of operating usually do not appear immediately. However, the frequency of ischemic events tend to be reduced gradually [23,27,29,33,34,35]. The postoperative course of patients is variable and depends upon individual increase in cerebral blood flow and the method of operation, among other factors.

General anesthesia for Moyamoya disease has been associated with



**Figure 11:** Transposition of omentum. 1) Presentation of omentum through a midline supraumbilical laparotomy. 2) Extension of the omentum through L-shaped incisions, preserving vascularization. 3) Pass the omentum, tunneled through the subcutaneous tissue from the abdomen to the skull. 4) Suture the edges of the omentum to the edges of the dura.



**Figure 12:** Revascularization through burr holes. Outline of the burr hole sites (4 to 6) to achieve indirect revascularization.

a relatively low risk of a new stroke, both during bypass surgery as well as during cerebral angiography, in adults [26,27,33,34,35].

## General Results of the Surgical Bypass

The purpose of using surgical anastomoses, either directly or indirectly is to prevent recurrent cerebrovascular disease, not to reverse the effects of already completed strokes.

In cases of ischemic stroke, most neurosurgeons with experience in the field believe that bypass presents an important modifier of the natural history of Moyamoya disease. Indeed, many Moyamoya patients with a history of ischemic events experience a reduction or disappearance of symptoms following surgery, correlated in the majority of series with good to excellent revascularization on imaging [26,27,33,34,35].

In cases of hemorrhagic stroke, the purpose of the anastomosis is to prevent rebleeding. The benefits of surgery in such cases are more unclear and controversial compared to the benefits seen following surgical intervention for Moyamoya patients with ischemic disease.

## References

1. Suzuki J, Takaku A (1969) Cerebrovascular "moyamoya" disease. Disease showing abnormal net-like vessels in base of brain. *Arch Neurol* 20: 288-299.
2. Takeuchi K, Shimizu K (1957) Hypogenesis of bilateral internal carotid arteries. *No To Shinkei* 9: 37-43.
3. Kudo T (1968) Spontaneous occlusion of the circle of Willis. A disease apparently confined to Japanese. *Neurology* 18: 485-496.
4. Suzuki J (1986) Epidemiology and Symptomatology. In: Jiro S (ed.) *Moyamoya Disease*. Springer-Verlag Berlin Heidelberg.
5. Yamaguchi T, Tashiro T, Minematsu K, Kitamura K (2000) Linkage of Familial Moyamoya Disease (Spontaneous Occlusion of the Circle of Willis) to Chromosome 17q25.
6. Higashi K, Hatano M, Maza T (1974) Disease with abnormal intracranial vascular network complicated with intracerebral haematoma. *J Neuro Neurosurgery Psychiatry* 37: 365-369.
7. Hori T, Fukushima T, Tsuchida T, Ishijima B, Manaka S (1971) Case of cerebral juxta-basal telangiectasia with cerebral hematoma. *No To Shinkei* 23: 1403-1408.
8. Hayasaki K (1970) A case of schizophrenic state combined with intracranial rete mirabile vascularity. *Brain Nerve(Tokyo)* 22: 1319-1323.
9. Hirano M, Sakurai S (1972) Psychiatric symptoms and signs associated with spontaneous occlusion of the circle of Willis. *Psychiatr Med (Tokyo)* 14: 329-338.
10. Yamada I, Suzuki S, Matsushima Y (1995) Moyamoya disease: comparison of assessment with MR angiography and MR imaging versus conventional angiography. *Radiology* 196: 211-218.
11. Katz DA, Marks MP, Napel SA, Bracci PM, Roberts SL (1995) Circle of Willis: evaluation with spiral CT angiography, MR angiography, and conventional angiography. *Radiology* 195: 445-449.
12. Takanashi JI, Sugita K, Niimi H (1998) Evaluation of magnetic resonance angiography with selective maximum intensity projection in patients with childhood moyamoya disease. *Eur J Paediatr Neurol* 2: 83-89.
13. Fujiwara H, Momoshima S, Kuribayashi S (2005) Leptomeningeal high signal intensity (ivy sign) on fluid-attenuated inversion-recovery (FLAIR) MR images in moyamoya disease. *Eur J Radiol* 55: 224-230.
14. Yamada I, Matsushima Y, Suzuki S (1992) Moyamoya disease: diagnosis with three-dimensional time-of-flight MR angiography. *Radiology* 184: 773-778.
15. Quintana L (2004) Experiencia de 20 años en el Manejo de la Enfermedad Moyamoya. *Rev Chil Neurocirug* 23: 30-36.
16. Fukuyama Y, Umezumi R (1985) Clinical and cerebral angiographic evolutions of idiopathic progressive occlusive disease of the circle of Willis ("moyamoya" disease) in children. *Brain Dev* 7: 21-37.
17. Ikesaki K, Matsushima T, Kubawara Y, Suzuki S, Nomura T et al. (1994) Cerebral circulation and oxygen metabolism in childhood moyamoya disease: A perioperative positron emission tomography study. *J Neurosurg* 81: 843-850.
18. Takeuchi S, Tanaka R, Ishii R, Tsuchida T, Kobayashi K, et al. (1985) Cerebral hemodynamics in patients with moyamoya disease. A study of regional cerebral blood flow by the <sup>133</sup>Xe inhalation method. *Surg Neurol* 23: 468-474.
19. Wanifuchi H, Takeshita M, Izawa M, Aoki N, Kagawa M (1993) Management of adult moyamoya disease. *Neurol Med Chir (Tokyo)* 33: 300-305.
20. Abdulrauf SI, Furlan AJ, Awad I (1999) Primary intracerebral hemorrhage and subarachnoid hemorrhage. *J Stroke Cerebrovasc Dis* 8: 146-150.
21. McDonald C, Carter BS (2002) Medical management of increased intracranial pressure after spontaneous intracerebral hemorrhage. *Neurosurg Clin N Am* 13: 335-338.
22. Scott RM, Smith ER (2009) Moyamoya disease and moyamoya syndrome. *N Engl J Med* 360: 1226-1237.
23. Houkin K, Ishikawa T, Yoshimoto T, Abe H (1997) Direct and indirect revascularization for moyamoya disease- surgical techniques and perioperative complications. *Clin Neurol Neurosurg* 99: 142-145.
24. Yasargil MG, Yonekawa Y (1977) Results of microsurgical extra-intracranial arterial bypass in the treatment of cerebral ischemia. *Neurosurgery* 1: 22-24.
25. Karasawa J, Kikuchi H, Furuse S, Kawamura J, Sakaki T (1978) Treatment of moyamoya disease with STA-MCA anastomosis. *J Neurosurg* 49: 679-688.
26. Fukui M (1997) Guidelines for the diagnosis and treatment of spontaneous occlusion of the circle of Willis ('moyamoya' disease). Research Committee on Spontaneous Occlusion of the Circle of Willis (Moyamoya Disease) of the Ministry of Health and Welfare, Japan. *Clin Neurol Neurosurg* 99 Suppl 2: S238-240.
27. Adelson PD, Scott RM (1995) Pial synangiosis for moyamoya syndrome in children. *Pediatr Neurosurg* 23: 26-33.
28. Endo M, Kawano N, Miyasaka Y, Yada K (1989) Cranial burr hole for revascularization in moyamoya disease. *J Neurosurg* 71: 180-185.
29. Kawaguchi T, Fujita S, Hosoda K, Shose Y, Hamano S, et al. (1996) Multiple burr-hole operation for adult moyamoya disease. *J Neurosurg* 84: 468-476.
30. Karasawa J, Touho H, Ohnishi H, Miyamoto S, Kikuchi H (1993) Cerebral revascularization using omental transplantation for childhood moyamoya disease. *J Neurosurg* 79: 192-196.
31. Goldsmith HS (1994) Brain and spinal cord revascularization by omental transposition. *Neurol Res* 16: 159-162.
32. Matsushima Y, Fukai N, Tanaka K, Tsuruoka S, Inaba Y, et al. (1981) A new surgical treatment of moyamoya disease in children: a preliminary report. *Surg Neurol* 15: 313-320.
33. Matsushima Y, Inaba Y (1984) Moyamoya disease in children and its surgical treatment. Introduction of a new surgical procedure and its follow-up angiograms. *Childs Brain* 11: 155-170.
34. Karasawa J, Kikuchi H, Furuse S, Sakaki T, Yoshida Y (1977) A surgical treatment of "moyamoya" disease "encephalo-myo synangiosis". *Neurol Med Chir (Tokyo)* 17: 29-37.
35. Matsushima T, Inoue T, Katsuta T, Natori Y, Suzuki S, et al. (1998) An indirect revascularization method in the surgical treatment of moyamoya disease-various kinds of indirect procedures and a multiple combined indirect procedure. *Neurol Med Chir (Tokyo)* 38: 297-302.
36. Crowell RM (1977) Direct Brain Revascularization. In: Schmiedek HH, Sweet WH (eds) *Current Techniques in Operative Neurosurgery*. Grune & Stratton Inc.
37. Yonekawa Y, Yasargil MG (1976) Extra-Intracranial Arterial Anastomosis: Clinical and Technical Aspects. Results. In: Krayenbühl H (ed.) *Advances and Technical Standards in Neurosurgery*. Springer-Verlag, Zürich, Wien, New York.
38. Little JR, Salerno TA (1978) Continuous suturing for microvascular anastomosis. Technical note. *J Neurosurg* 48: 1042-1045.
39. Kim SK, Wang KC, Kim IO, Lee DS, Cho BK (2002) Combined Encephaloduroarteriosynangiosis and Bifrontal Encephalogaleo (periostal) synangiosis in Pediatric Moyamoya Disease. *Neurosurgery* 50: 88-96.