

# Microsurgical Treatment of Ischemic Necrosis after Segmental Le Fort I Osteotomy: A Case Report

Cholakis AK<sup>1</sup>, McFadden LR<sup>2</sup> and Elgazzar RF<sup>2\*</sup>

<sup>1</sup>Program Director, Periodontology Division, DDSS, Faculty of Dentistry, University of Manitoba, Canada

<sup>2</sup>Oral and Maxillofacial Surgeon, DDSS, Faculty of Dentistry, University of Manitoba, Canada

## Abstract

Although it is uncommon, ischemic necrosis after Le Fort I osteotomy, especially with segmentalization of the maxilla, represents a challenge for both clinician and patient. The objective of this study was to review the literature and present a case of microsurgical reconstruction of maxillary ischemic necrosis that occurred after a Le Fort I segmental osteotomy. A 30 year old female patient underwent bimaxillary surgery for the correction of her dentofacial deformity. Surgery in the maxilla involved segmenting the maxilla into three pieces with osteotomies completed between the cuspid and first bicuspid teeth bilaterally. Few weeks later, examination of the affected site revealed necrotic bone and a deep residual defect in the buccal aspect of the maxillary right first premolar and canine. This defect was successfully reconstructed using a sequence of buccal advancement flap and soft tissue palatal graft.

**Keywords:** Orthognathic surgery; Ischemic necrosis; Segmental Le Fort I Osteotomy; Microsurgery

## Introduction

The Le Fort I osteotomy is a commonly performed orthognathic surgical procedure for the correction of dentofacial deformities. Generally, provided that the surgeon is well-trained in the procedure and standard methods are followed, the complication rate is low, ranging from 6.4% to 27% [1-3]. Vascular compromise of the maxilla after orthognathic surgery has rarely been reported [4,5]. Complications, especially with segmentalization of the maxilla, may include segmental loss of bone and teeth, devitalization of teeth, osteonecrosis, formation of fistulas, and the formation of periodontal or mucogingival defects. Although reports of periodontal complications following orthognathic surgery have been published [6], the soft tissue restoration in many cases is less than ideal resulting in residual recession defects and in many cases ongoing sensitivity to cold.

The use of magnification, especially in surgical operating microscopes, has become more widespread in several fields of dentistry over the last 20 years [7]. Microscope-enhanced periodontal surgical procedures have been well documented in the literature. In a controlled clinical trial of 24 patients comparing soft tissue surgery with or without a microsurgical technique, significantly better scarring and marginal profile was noted in the group that underwent the microsurgical procedure [8].

This report illustrates a case of severe bone and soft tissue loss in the area of an osteotomy site and its subsequent soft tissue microsurgical management.

## Case Report

Following 16 months of presurgical orthodontic treatment, a 30 year old female patient underwent bimaxillary surgery for the correction of her dentofacial deformity (Figure 1A). Her deformity consisted of vertical maxillary excess with transverse maxillary and mandibular deficiencies.

Surgery in the maxilla involved segmenting the maxilla into three pieces with osteotomies completed between the cuspid and first bicuspid teeth bilaterally. The surgery was accomplished without incident. The patient was seen six days post operatively and was felt to be doing well. Two days later the patient called with a chief complaint that she had felt something pop. Re-evaluation at that time showed

white gingiva overlying the maxillary cuspid as well as the first bicuspid tooth on the right side with recession. Intermaxillary elastics were discouraged and she was started on an oral antibiotic, instructed on oral hygiene of the area and advised to avoid biting pressure on these. After discussion with the periodontist, she was referred for treatment of the bony and soft tissue defect.

Few weeks later, examination of the affected site revealed necrotic bone and a 10 mm residual defect in the buccal aspect of the maxillary right first premolar and a 6.5 mm defect in the buccal aspect of the canine (Figure 1B). The patient was unable to perform adequate oral hygiene in the area due to extreme sensitivity to pressure hot and cold. There was a total absence of keratinized tissue at the apical aspect of the defect of the right first bicuspid. Electric and cold pulp tests were performed on both teeth to determine their vitality. Both teeth tested vital.

The first surgical procedure took place 3 months following the examination. The area was anesthetized with a maxillary block and palatal infiltration (Lidocaine 2%, 1:100:000 epinephrine), the premolar was thoroughly debrided, removing all necrotic bone and debris. The exposed root was root planed utilizing hand instrumentation and disinfected utilizing a 2% doxycycline solution. A congenital groove was noted on the buccal aspect of the root and was instrumented, so as to eliminate it, with hand and rotary instruments.

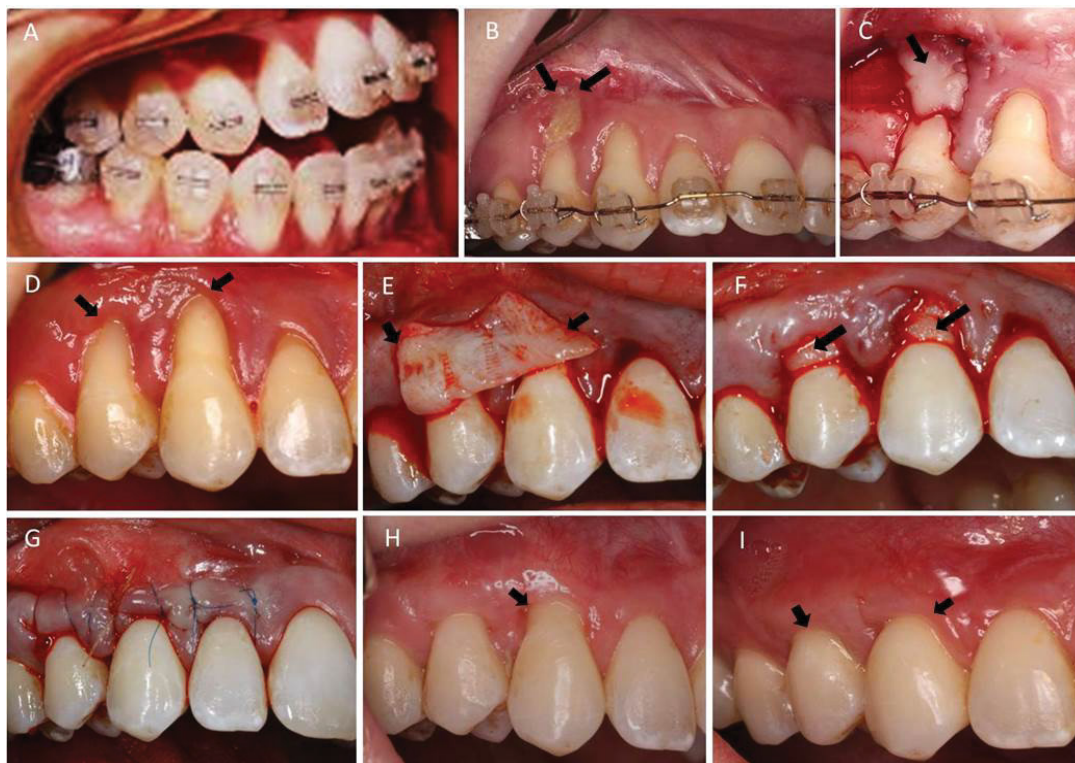
A partial thickness pedicle flap was prepared with a vertical releasing incision at the level of the second bicuspid (Figure 1C). The flap was sutured with 6-0 chromic gut on the vertical aspect and 6-0 polypropylene sutures on the coronal. The area was allowed to heal for 3 months (Figure 1D). The apical aspect of the first maxillary right

**\*Corresponding author:** Reda Fouad Elgazzar, Dental Diagnostic and Surgical Sciences Faculty of Dentistry, University of Manitoba, 790 Bannatyne Avenue, Winnipeg, Manitoba, R3E 0W2, Canada, Tel: +1 (204) 789 3634; Fax: +1 (204) 272 3077; E-mail: [reda\\_elgazzar@yahoo.co.uk](mailto:reda_elgazzar@yahoo.co.uk), [reda.elgazzar@umanitoba.ca](mailto:reda.elgazzar@umanitoba.ca)

**Received** August 09, 2018; **Accepted** August 15, 2018; **Published** August 20, 2018

**Citation:** Cholakis AK, McFadden LR, Elgazzar RF (2018) Microsurgical Treatment of Ischemic Necrosis after Segmental Le Fort I Osteotomy: A Case Report. Dentistry 8: 506. doi:10.4172/2161-1122.1000506

**Copyright:** © 2018 Cholakis AK, et al. This is an open-access article distributed under the terms of the Creative Commons Attribution License, which permits unrestricted use, distribution, and reproduction in any medium, provided the original author and source are credited.



**Figure 1 (A-I):** A sequence of intraoral photographs showing: posterior maxillary excess and anterior open bite (A); buccal bone necrosis related to teeth number 14 & 13 (B); intraoperative (C) & postoperative (D) pedicled advanced buccal flap; palatal connective tissue flap was tailored to the site (E), adapted around the teeth roots within the overlying mucoperiosteal flap (F), and then sutured in place (G); one month postoperative showing complete healing with a 3 mm defect at tooth number 13 (H) which was treated with another connective tissue graft; final healing 4 weeks postoperatively (I).

bicuspid had now acquired a band of attached keratinized tissue, which facilitated subsequent soft tissue grafting. Following the first surgery the patient was de-banded and a fixed retainer was luted to the palatal aspect of the maxillary teeth to ensure stability of the teeth during subsequent surgeries.

A connective tissue graft (15 mm × 1.5 mm) was harvested from the anterior hard palate at the level of the first and second bicuspid on the same side. The epithelium was removed from the graft and the tissue was tailored to conform to the defect (Figure 1E). A full thickness mucoperiosteal pouch was created extending beyond the two involved teeth mesially and distally. The graft was placed in the pouch (Figure 1F). Every effort was made to cover the graft by coronally positioning the pouch. A small tear that occurred during the elevation of the pouch was sutured with 6-0 chromic gut suture. Suturing was performed with 7-0 Polypropylene circumferential continual sling sutures (Figure 1G). The graft and flap were sutured separately. The palatal donor site was sealed with cyanoacrylate. The patient was advised to follow a soft diet and use a 0.12% chlorhexidine solution twice a day. Suture removal was performed at two weeks. There were no post-operative complications and healing was uneventful.

At 1 month post-operatively, the premolar area exhibited full coverage while the canine had 3mm of residual recession (originally 6.5 mm) (Figure 1H). A final subepithelial soft tissue graft of the canine was performed (as previously described) in order to obtain full root coverage of both teeth (Figure 1I). All symptoms of sensitivity to temperature and pressure discomfort were completely alleviated and the patient was able to proceed with regular oral homecare efforts.

## Discussion

Ischemic bone necrosis and loss of teeth is a disastrous outcome after an elective procedure to correct an aesthetic and functional problem of the facial skeleton. It is unusual after a one-piece advancement. In a retrospective review of complication rates associated with segmental maxillary surgery, in 85 patients treated from 1995 to 2009, Ho et al. [2] found the overall complication rate to be 27%. Of them, three patients (4%) had devitalization of teeth, three (4%) developed minor periodontal defects, and one had tooth loss. Kahnberg et al. [9] however in a retrospective study of 138 osteotomies found a very low incidence of marginal bone loss, root resorption or osteolytic processes. This case illustrates the management of an adverse outcome resulting in the loss of the buccal alveolar plate in the area of an osteotomy, resulting in extensive soft tissue mucogingival defects. Lanigan et al. [10] have studied the ischemic necrosis following maxillary osteotomies, and they concluded that rupture of the descending palatine artery during surgery, postoperative vascular thrombosis, perforation of palatal mucosa when splitting the maxilla into segments, or partial stripping of palatal soft tissues to increase maxillary expansion may impair blood supply to the maxillary segments [6]. This may lead to loss of tooth vitality, development of periodontal defects, tooth loss, or loss of major segments of alveolar bone or the entire maxilla [1,10]. In the current case the descending palatine vessels were not severed, the overlying palatal mucosa was not stripped nor violated and there was enough space between the roots of the cuspid and bicuspid before segmentation; however, avascular necrosis took place. According to Lanigan 1990, this might be due to stagnation of blood and/or unnoticed thrombosis of the feeder vessel.

Soft tissue grafting in the form of connective tissue grafts or pedicle grafts has been extensively described in the periodontal literature [11,12] for coverage of exposed root surfaces. The more recent use of dental microscopes and the ability to decrease tissue trauma and achieve better passive primary wound closure has further enhanced the field of periodontal plastic surgery [7]. A recent study by Francetti et al. [8] found significant better scarring and soft tissue profiles in patients having undergone a microsurgical procedure when compared to controls. This was supported by another split mouth clinical trial that compared root coverage outcomes, post-operative morbidity and esthetic outcomes of subepithelial grafts performed with and without a dental microscope. At 12 months the test group exhibited higher means of root coverage than the control group, as well as less post-operative sensitivity [13]. In conclusion, this case report outlines a sequence of microsurgical soft tissue procedures that can be performed in cases of ischemic buccal bone necrosis following a segmental Le Fort I osteotomy.

### Ethical Approval

Ethical approval was granted from the Bannatyne Research ethics Board at the University of Manitoba.

### Acknowledgement

We acknowledge the Department of Dental Diagnostic and Surgical Sciences, Faculty of Dentistry, University of Manitoba in which this study was conducted.

### References

1. Kramer FJ, Baethge C, Swennen G, Teltzrow T, Schulze A, et al. (2004) Intra- and perioperative complications of the LeFort I osteotomy: a prospective evaluation of 1000 patients. *J Craniofac Surg* 15: 971-977.
2. Ho MW, Boyle MA, Cooper JC, Dodd MD, Richardson D (2011) Surgical complications of segmental Le Fort I osteotomy. *Br J Oral Maxillofac Surg* 49: 562-566.
3. de Mol van Otterloo JJ, Tuinzing DB, Greebe RB, van der Kwast WA (1991) Intra- and early postoperative complications of the Le Fort I osteotomy. A retrospective study on 410 cases. *J Craniomaxillofac Surg* 19: 217-222.
4. Parnes EI, Becker ML (1972) Necrosis of the anterior maxilla following osteotomy. *Oral Surg Oral Med Oral Pathol* 33: 326-330.
5. Westwood RM, Tilson HB (1975) Complications associated with maxillary osteotomies. *J Oral Surg* 33: 104-115.
6. Omnell ML, Tong DC, Thomas T (1994) Periodontal complications following orthognathic surgery and genioplasty in a 19-year-old: a case report. *Int J Adult Orthodon Orthognath Surg* 9: 133-139.
7. Shanellec DA (2003) Periodontal microsurgery. *Esthet Restor Dent* 15: 402-407.
8. Francetti L, Del Fabbro M, Calace S, Testori T, Weinstein RL (2005) Microsurgical treatment of gingival recession: a controlled clinical study. *Int J Periodontics Restorative Dent* 25: 181-188.
9. Kahnberg KE, Vannas-Löfqvist L, Zellin G (2005) Complications associated with segmentation of the maxilla: a retrospective radiographic follow up of 82 patients. *Int J Oral Maxillofac Surg* 34: 840-845.
10. Lanigan DT, Hey JH, West RA (1990) Aseptic necrosis following maxillary osteotomies: Report of 36 cases. *J Oral Maxillofac Surg* 48: 142-156.
11. Aroca S, Molnár B, Windisch P, Gera I, Salvi GE, et al. (2013) Treatment of multiple adjacent Miller class I and II gingival recessions with a Modified Coronally Advanced Tunnel (MCAT) technique and a collagen matrix or palatal connective tissue graft: a randomized, controlled clinical trial. *Clin Periodontol* 40: 713-720.
12. Chambrone L, Pannuti CM, Tu YK, Chambrone LA (2012) Evidence-based periodontal plastic surgery II. An individual data meta-analysis for evaluating factors in achieving complete root coverage. *J Periodontol* 83(4): 477-90.
13. Bittencourt S, Del Peloso Ribeiro E, Sallum E, Nociti F, Casati M (2012) Surgical microscope may enhance root coverage with subepithelial connective tissue graft: a randomized-controlled clinical trial. *J Periodontol* 83(6): 721-730.