

## Management of Class III Malocclusion with Missing a Maxillary Central Incisor (A Case Report)

Fidan Alakus Sabuncuoğlu<sup>1\*</sup>, Erkan Özcan<sup>2</sup> and Seyda Ersahan<sup>3</sup>

<sup>1</sup>Orthodontics Department, Maresal Cakmak Military Hospital Dental Center, Erzurum, Turkey

<sup>2</sup>Periodontology Department, Maresal Cakmak Military Hospital Dental Center, Erzurum, Turkey

<sup>3</sup>Beytepe Military Hospital, Ahlatlıbel Mh., 06640 Ankara, Turkey

\*Corresponding author: Fidan Alakus Sabuncuoğlu, DDS, Ph.D., Orthodontics Department, Maresal Cakmak Military Hospital Dental Center, Erzurum, Turkey, Tel: + 90 442 317 2665; Fax: + 90 442 317 2263; E-mail: [fidansabuncuoglu@yahoo.com.tr](mailto:fidansabuncuoglu@yahoo.com.tr)

Rec Date: Sep 13, 2014; Acc Date: Oct 16, 2014; Pub Date: Oct 23, 2014

Copyright: © 2014 Sabuncuoğlu FA et al., This is an open-access article distributed under the terms of the Creative Commons Attribution License, which permits unrestricted use, distribution, and reproduction in any medium, provided the original author and source are credited.

### Abstract

**Aim:** The present case report describes the orthodontic treatment of a patient with a missing maxillary right central incisor and a skeletal Class III jaw relationship due to a retrognathic maxilla.

**Materials and Methods:** Treatment was conducted in two phases, with a removable appliance and Delaire's facemask used in the first phase and a fixed appliance used in the second phase. Mesial movement of the maxillary canine, first premolar, second premolar and first molar was achieved sequentially over the two phases of treatment. After 36 months, the anterior space was closed, and good intercuspatation and interproximal contacts and satisfactory root parallelism were achieved. Finally, interproximal spaces were closed orthodontically, the crown of the upper right lateral incisor was anatomically modified to imitate a central incisor, the right maxillary canine was reshaped slightly along the incisal edge, and a gingivectomy was performed in the maxillary canine area to achieve normal vertical crown proportions.

**Results:** Post-treatment intraoral photographs show satisfactory dental alignment and acceptable overjet and overbite. The patient was satisfied with her teeth and profile.

**Conclusion:** The combination of maxillary protractor and fixed appliance successfully corrected the skeletal Class III malocclusion and achieved forward mesial movement of the maxillary posterior teeth.

**Keywords:** Class III malocclusion; Missing maxillary central tooth; Space closure

### Introduction

Class III malocclusion has long been viewed as one of the most severe facial deformities. While most Class II patients can be successfully treated by orthodontic means alone, a Class III relationship in the growing patient presents a greater challenge.

Skeletal Class III anomalies may be associated with maxillary retrusion, mandibular protrusion, or both. In such cases, orthodontic treatment is needed to correct the skeletal discrepancy. If left untreated, the malocclusion tends to worsen [1-3] and these untreated patients will ultimately comprise a substantial percentage of that seeking orthognathic surgical treatment as adults [4,5].

Congenitally missing teeth affect the occlusal relationship between the maxilla and mandible. A Class III malocclusion occurs most frequently among subjects with missing maxillary teeth only, whereas a Class II malocclusion is seen most often in connection with the absence of mandibular teeth only [6]. The issue of how to treat maxillary central agenesis with a skeletal Class III jaw relationship is always a matter of some controversy, mainly with regard to the length of time and difficulty of treatment, which can be performed in a variety of ways [6].

The present case report describes orthodontic treatment of a patient with a missing maxillary right central incisor due to accident and a skeletal Class III jaw relationship caused retropositioned maxilla.

### Case Report

A 9-year, 1-month-old female patient was brought to the clinic by her parents, who were concerned about the child's protruded mandible and maxillary anterior teeth due to accidental loss of right maxillary central incisor. Extraoral examination showed a concave profile with good facial symmetry, a retruded upper lip and a protruded lower lip. Intraoral examination showed the patient to be in a stage of mixed dentition with a Class III molar relationship, a -1 mm overjet and a -2 mm overbite. A panoramic radiograph showed the absence of the right maxillary central incisor (Figure 1). Lateral cephalometric measurements (Table 1) showed a skeletal Class III jaw relationship (ANB) with a retropositioned maxilla (SNA), proclined upper incisors and normal position lower incisors. The patient had a small maxilla and a large mandible, but despite a reduced mandibular plane angle, her vertical facial proportions were balanced.

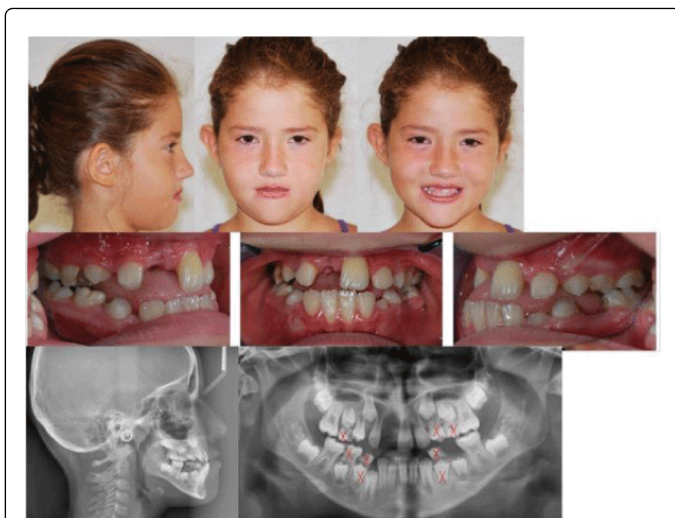

Figure 1: Pre-treatment extraoral - intraoral views and radiographs

Measurement	Normal	Pre-treatment	Post-treatment
SNA	82°±2	77 °	80 °
SNB	80°±2	79°	79 °
ANB	+2°	-2°	1°
NV-A	0 mm	-2 mm	+1 mm
NV-Pog Vertical relationships	-4/-6 mm	+2 mm	-1 mm
SN/Go-Gn	32 °	29 °	31 °
N-Me	-	111 mm	113 mm
ANS-Me	-	61 mm	63 mm
S-Go	-	70 mm	71 mm
S-Go/N-Me relationships	Dentobasal %62-65	63%	62%
1/SN	103 °	104 °	106 °
1-NA	4 mm	4 mm	5 mm
1/NA	22 °	23 °	25 °
1/Go-Gn	93 °	90 °	89 °
1-NB	4 mm	3 mm	3 mm
1/NB	25 °	23 °	21 °

Table 1: Cephalometric analysis of care

### Treatment Plan

The parents were informed that because of the patient's skeletal disharmony, surgical-orthodontic treatment might be necessary if any significant mandibular growth occurred in the future. At the same time, they were also informed of a possible nonsurgical approach. The parents showed a strong preference for a nonsurgical approach, and

considering that the overclosed mandible might influence potential maxillary growth, and because the patient was in mixed dentition, treatment was tentatively begun non-surgically, with the understanding that this approach would be reassessed based on the response to treatment.

Treatment objectives were as follows: (1) correct the crossbite, (2) establish acceptable overbite and overjet, (3) close the anterior space, (4) align the teeth and harmonize the arches, (5) improve gingival health, and (6) improve the patient's facial and dental aesthetics.

### Treatment Progress

Treatment began with the extraction of five deciduous teeth and the left and right permanent mandibular first premolars and left permanent maxillary first premolar for align the teeth, harmonize the arches and establish acceptable overbite and overjet. Following these initial extractions, treatment was conducted in two phases. In the first phase, a removable appliance and Delaire's facemask with a force of 500 g on each side directed nearly 30° downward and forward was used for 12 hours a day as an anchorage for both maxillary advancement and mesial movement of the posterior maxillary teeth. The treatment response was favorable, and after an 8-month period, the second phase of treatment was begun. In this phase, a fixed appliance was used to achieve sequential mesial movement of the maxillary canine, first premolar, second premolar and first molar teeth (Figure 2). Fixed appliance treatment was initiated with a .014" NiTi archwire, followed by .016" NiTi, .017"×.025" NiTi, .018" stainless steel and .018"×.025" stainless steel. Mesial movement of the first molar was achieved using a maxillary protractor with edgewise appliances and Class III elastics. In addition, a tip-back bend was given to the .017"×.025" stainless steel arch wire to prevent mesial tipping, and the wire was reduced for easy movement. Closure of the anterior space was achieved after 12 months of treatment, and by maintaining torque control during retraction of the mandibular incisors, good incisor inclination was also achieved. Finally, the right canine was lightly grinded to slightly reshape the incisal edge, and composite resin was bonded to both the mesial and distal sides of the lateral incisor to simulate the central incisor morphology. A gingivectomy was performed in the maxillary canine area to achieve aesthetic gingival contours. The fixed appliance was debonded, and lingual retainer constructed from .017" multistranded wire (Coaxial, 3M Unitek, Monrovia, Calif) was placed in the maxillary arch and a Hawley appliance was given to the patient for the mandibular arch. Total treatment time was 36 months (Figure 3). Two years after retention, an acceptable occlusion was maintained without any marked relapse in occlusion, which indicates long-term stability of the occlusion (Figure 4).

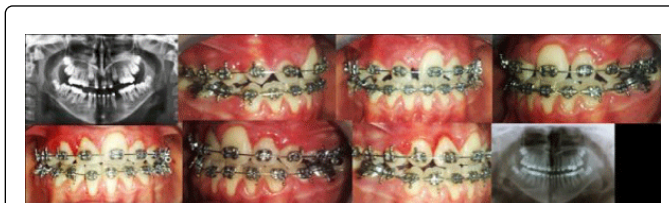
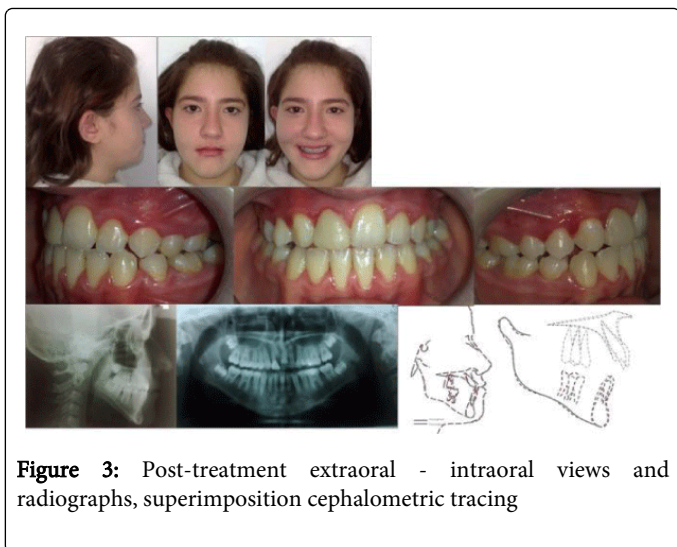


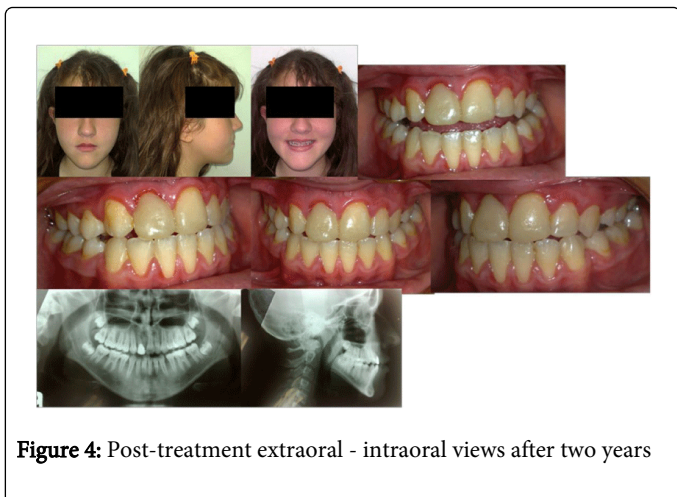Figure 2: Treatment phase



**Figure 3:** Post-treatment extraoral - intraoral views and radiographs, superimposition cephalometric tracing

### Results

Post-treatment extraoral photographs show a general improvement in the facial profile. Facial aesthetics were improved by reducing the prominence of the lower lip. Maxillary incisor proclination resulted in protrusion of the upper lip. Post-treatment intraoral photographs show satisfactory dental alignment and acceptable overjet and overbite. The patient was satisfied with her teeth and profile. Good intercuspation, interproximal contacts and satisfactory root parallelism were achieved (Figure 4).



**Figure 4:** Post-treatment extraoral - intraoral views after two years

### Discussion

It is widely accepted that early treatment of Class III patients with midface deficiencies is required in order to achieve the greatest possible response from maxillary protraction therapy. Due to the maturation of the circummaxillary sutures, the skeletal effect of protraction therapy diminishes with increasing age, with the best skeletal effect obtained during either primary or early-mixed dentition [7]. Delaire [8] has shown that forward positioning of the skeletal maxilla can be achieved with reverse headgear if treatment is started at an early age, and he suggested that in order to be successful, forward positioning of the maxilla must be completed before 8 years of age, because after this age, orthodontic tooth movement tends to replace

skeletal movement. According to McNamara [9], the best time to begin early Class III treatment is during early mixed dentition, which coincides with the eruption of the permanent maxillary central incisors. Proffit and Fields [10] recommended that children with maxillary deficiencies undergo a full evaluation as early as possible. In a study of 46 patients with mixed dentition, Baccetti et al. [11] found more significant maxillary modification in the early phases of mixed dentition than in the later phases, whereas we prefer to initiate treatment slightly later, towards the end of growth, in order to achieve more stable results. In the case presented here, phase 1 treatment began during the period of early permanent dentition and we treated the patient by a growth modification treatment with a facemask for mesial movement of the maxillary posterior teeth and correct the crossbite. Not only is a patient often more capable of cooperation during this period, this timing makes it possible to begin fixed-appliance treatment immediately after protraction therapy, thereby eliminating the problem of maintaining the results achieved in the first phase of treatment and shortening the overall treatment time.

Our patient was diagnosed with an absent maxillary central incisor due to accident and a skeletal Class III jaw relationship caused by retropositioned maxilla. Treatment achieved enough posterior maxillary teeth movement to close the anterior space with no tipping of the posterior crowns. Some authors [12-14] have expressed preference for an implant or prosthesis because of a number of perceived disadvantages related to space closure. In choosing between an implant/prosthesis or closing the space caused by maxillary central incisor agenesis, the dentist must take into consideration differences in important variables such as color, shape and size of the lateral canine; root prominence; and height of the gingival scallops. Carlson [12] described a procedure for physically closing the space caused by a missing maxillary central incisor without orthodontic treatment; however, this procedure can only be used if the patient's facial configuration will not be adversely affected. Moreover, in a follow-up survey of patients who received either orthodontic or prosthodontic treatment to close the space caused by a congenitally absent maxillary incisor, Nordquist et al. [13] reported no difference in occlusal function between the two groups, but found patients treated by space closure had healthier periodontia. For these reasons, in the present case, we chose to close the space left by the congenitally missing tooth by forward movement of the premolars using maxillary protraction with edgewise appliances. This treatment entailed the mesial movement of the maxillary molars as well as the maxillary premolars, and a Class I molar relationship with tight interdigitation was achieved as a result.

The maxillary first premolar may serve as an appropriate substitute for the canine, both functionally and aesthetically [14]; in such a case, in addition to aesthetic considerations, it is important that the lingual cusp of the first premolar and the tooth should be rotated mesially without causing discomfort to the patient, with minimum or no clinical and radiographic reaction in the long term.

Treatment of this case also highlights the need to re-evaluate the substitution of a maxillary lateral incisor for a missing central incisor in light of recent developments in dental adhesives and restorative materials. When modifying a lateral incisor to simulate a missing central incisor, the narrower cervical region of the lateral incisor when compared to the central tooth results in a triangular space in the midline, and over-contouring of the final restoration to hide this space may lead to trapped plaque and poor gingival health and appearance. Moreover, unilateral closure of the central incisor space often results



in some degree of loss in the dental midline. In the case presented here, by restoring both the mesial and distal side of the tooth, better aesthetics were achieved with a less bulky restoration, enabling the patient to maintain very good oral hygiene.

The case presented here resulted in the acceptable correction of a skeletal Class III malocclusion and closure of the space created by a congenitally absent maxillary incisor through forward movement of the maxillary posterior teeth using a combination of maxillary protractor and fixed appliance treatment. The patient was pleased with her smile and appearance and was happy not to have required a prosthetic device.

## Conclusion

A combination of maxillary protractor and fixed appliance was effective in correcting the skeletal Class III malocclusion as well as achieving forward movement of the maxillary posterior teeth in a patient with both a Class III malocclusion and a congenitally missing maxillary central incisor.

## References

1. Campbell PM (1983) The dilemma of Class III treatment. Early or late? *Angle Orthod* 53: 175-191.
2. Guyer EC, Ellis EE III, McNamara JA, Behrents RG (1986) Components of Class III malocclusion in juveniles and adolescents. *Angle Orthod* 56: 7-30.
3. McNamara JA Jr, Brudon WL (1993) *Orthodontic and Orthopedic Treatment in the Mixed Dentition*. Ann Arbor, Mich: Needham Press 117-129, 283-295.
4. Graber TM (1969) *Current Orthodontic Concepts and Techniques*. Philadelphia, PA: WB Saunders 927-947.
5. Jacobson A, Evans WG, Preston CB, Sadowsky PL (1974) Mandibular prognathism. *Am J Orthod* 66: 140-171.
6. Hirukawa K, Iwata R, Kurosawa M, Kondo T, Goto S (1999) Statistical investigation about the prevalence of congenitally missing permanent teeth. *Nippon Kyosei Shika Gakkai Zasshi* 58: 49-56.
7. Alcan T, Keles A, Erverdi N (2000) The effects of a modified protraction headgear on maxilla. *Am J Orthod Dentofacial Orthop* 117: 27-38.
8. Verdon P (1982) Professor Delaire's facial orthopedic mask. Denver: Rocky Mountain Orthodontic Products.
9. McNamara JA Jr (2000) Treatment of children in the mixed dentition. In: Graber TM, Vanarsdall RL, editors. *Orthodontics: current principles and techniques*. (3rd edn). Saint Louis: Mosby 508.
10. Proffit WR, Fields HW Jr (2000) Orthodontic treatment planning: limitations, controversies, and special problems. In: Proffit WR, Fields HW Jr, editors. *Contemporary Orthodontics* Saint Louis: Mosby.
11. Celikoglu M (2011) *yavuzi.biriskeletselsimf 3 olgununuyuzmaskesivekemikdestekl apareyiledavi of the pendulum (olgusunu me) Atatürk University. Dişhek. Fake. Bull. J Dent Face the Atatürk* 21: 33-38.
12. Carlson H (1952) Suggested treatment for missing lateral incisor cases. *Angle Orthod* 22: 205-216.
13. Nordquist GG, McNeill RW (1975) Orthodontic vs. restorative treatment of the congenitally absent lateral incisor-long term periodontal and occlusal evaluation. *J Periodontol* 46: 139-143.
14. Terada Y, Yamazaki O, Furusawa H, Hirose H, Miyazaki T, et al. (1982) The unusual alignment with unusual extraction in the upper and lower anterior segments. *Nippon Kyosei Shika Gakkai Zasshi* 41: 355-368.