

Jacob's Disease: A Case Report and Literature Review

Daniel Fernando Roscher^{1*}, Alberto Attaguile², Javier Benitez² and Graciela Giannunzio²

¹Department of Oral and Maxillofacial Surgery - University of Buenos Aires, Argentina Marcelo T. De Alvear 2142, Ciudad Autónoma de Buenos Aires, Argentina

²Maxillofacial Surgery Department - Manuel Belgrano General Hospital Buenos Aires, Argentina Av. Constituyentes 3120, Villa Zagala, Buenos Aires, Argentina

Abstract

Although osteochondroma is the most common benign tumor of bone in the axial skeleton, it rarely involves the maxillofacial region. In the latter case, it mainly affects the mandible, particularly the condyle. Very occasionally, it may affect the coronoid process and lead to the formation of a pseudo joint with the zygoma, a condition termed Jacob's disease. This results in restricted mandibular movement and often causes midfacial asymmetry. We herein report the case of an 18 year-old female patient with a history of limited mouth opening for several years. Computed tomography and 3D reconstruction showed an exophytic tumor in the coronoid process, and a close relationship between the coronoid process and the malar and zygomatic arch. Total resection of the tumor and coronoid process was performed. The histopathological diagnosis was osteochondroma, confirming diagnosis of Jacob's disease.

Keywords: Osteochondroma; Coronoid process; Jacob's disease

Introduction

Osteochondroma, or osteocartilaginous exostosis, accounts for 20-50% of all benign tumors and 10-15% of all bone tumors. It is the most common bone tumor of the axial skeleton, and is most frequently found in the metaphysis of long bones. The incidence of osteochondroma in the jaw is very low, but when it occurs in the oral and maxillofacial regions it mainly affects the mandible, especially the condyle, and very rarely develops on the coronoid process.

Although enlargement of the coronoid process was first described in 1853 by von Langenbeck [1], it was Oscar Jacob who first described the formation of a pseudo joint between the coronoid process and the zygoma in 1899 [2]. Later, in 1934, Shackelford reported the first case of osteochondroma of the coronoid process [3].

Osteochondroma of the coronoid process is a bone tumor with a characteristic mushroom shape and cartilage-capped projection, which differentiates it from osteoma [4]. The condition that results when a pseudo joint forms between the tumor and the inner surface of the zygoma is termed Jacob's disease, and may cause displacement of the zygoma and/or zygomatic arch. The most consistent clinical feature is limited mouth opening [5,6], and at more advanced stages the disease can present with severely restricted mandibular movements and midfacial asymmetry resulting from a painless swelling of the zygoma on the affected site [4]. It is more common in men (70%), and generally develops before the age of forty [1,4-6].

Conventional radiographs show enlargement of the coronoid process, but due to superimposition of images, this type of study is often insufficient. Computed tomography and three-dimensional (3D) reconstruction are therefore necessary to determine the relationship between the tumor and the zygoma [4,6].

According to the literature, coronoidectomy through an intraoral approach is the preferred treatment in most cases [1]. Nevertheless, some authors use the Al-Kayat approach and others prefer a hemicoronal approach [7,8].

Case Report

An 18-year old female patient presented for consultation at the Maxillofacial Surgery Department with a ten-year history of progressive restriction of mouth opening and mid facial asymmetry (Figure 1a and 1b).

Clinical examination revealed marked restriction of mandibular movement with no pain, and maximum 20 mm interincisal mouth

opening (Figure 1c). The panoramic radiograph showed the left coronoid process was enlarged, as compared to the contralateral side, and both condyles were normal in shape and structure. Computerized tomography revealed two mushroom-shaped exostoses on the left coronoid process. Three-dimensional reconstruction evidenced erosion and displacement of the zygoma, as well as a close relationship between the zygoma and the tumor, which lead to the formation of a pseudo joint between both structures (Figure 1d).

Based on the clinical evaluation and imaging studies, the presumptive diagnosis was Jacob's disease.

Under general anesthesia and using an intra-oral approach along the anterior border of the ascending mandibular ramus, a mucoperiosteal flap was raised to expose the sigmoid notch, and the coronoid process was held with a wire in order to avoid it being pulled up by the temporalis muscle.

Using a reciprocating saw, the coronoid process was osteotomized and excised (Figure 2a and 2b), achieving an intraoperative interincisal mouth opening of 45 mm. Post-operative physiotherapy was carried out for 2 months, and maximum interincisal mouth opening at 12 months was 41 mm (Figure 2c).

Discussion

Although osteochondroma is the most common bone tumor of the axial skeleton, it occurs very rarely in the jaws, and is even more infrequent on the coronoid process [9]. Jacob's disease is a rare condition, and is characterized by the formation of a pseudo joint between the coronoid process and the inner aspect of the malar and/or zygomatic arch, as a result of osteochondroma on the coronoid process [5]. The disease is asymptomatic in the first stages, and is usually a radiographic finding. In more advanced stages, however,

***Corresponding author:** Daniel Fernando Roscher, Department of Oral and Maxillofacial Surgery - University of Buenos Aires, Argentina Marcelo T. De Alvear 2142, Ciudad Autónoma de Buenos Aires, Argentina, Tel: 4964-1294; E-mail: danielroscher@gmail.com

Received April 10, 2018; Accepted May 07, 2018; Published May 15, 2018

Citation: Roscher DF, Attaguile A, Benitez J, Giannunzio G (2018) Jacob's Disease: A Case Report and Literature Review. Dentistry 8: 485. doi:10.4172/2161-1122.1000485

Copyright: © 2018 Roscher DF, et al. This is an open-access article distributed under the terms of the Creative Commons Attribution License, which permits unrestricted use, distribution, and reproduction in any medium, provided the original author and source are credited.

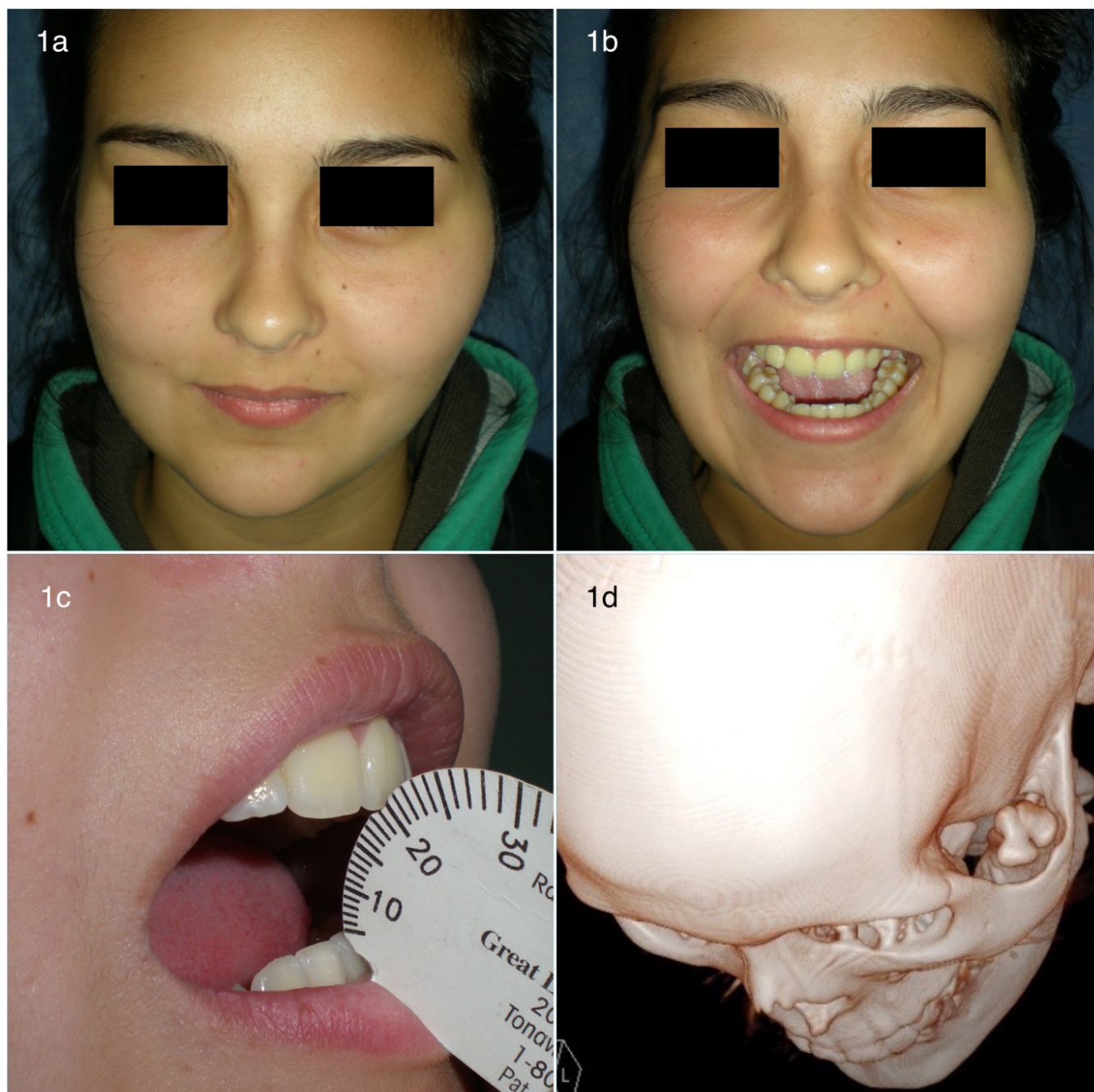


Figure 1: a) Front view of the patient. b) Facial asymmetry and limited mandibular movement. c) Maximum pre-operative interincisal mouth opening. d) 3D computerized tomography. Tumor on the coronoid process and associated with the zygoma.

Jacob's disease causes a decrease in mouth opening and restriction of mandibular movement, as well as mid facial asymmetry resulting from displacement of the zygoma, which is usually painless. Differential diagnosis must be established with temporomandibular joint disorders and myofascial syndromes.

The aim of treatment is to restore mandibular movement by excising the tumor together with the coronoid process. If the size of the tumor is appropriate, an intraoral approach should be used. Although extra-oral

approaches, with or without zygomatic arch osteotomy, have been used, they have been found to cause excessive scarring and to pose a high risk for damage to the branches of the facial nerve. An intra-oral approach eliminates these unwanted complications [10].

Consent

The patient gave her written informed consent to the taking of photographs, and for the medical photographs to be used by Daniel F. Roscher DDS medical publications.

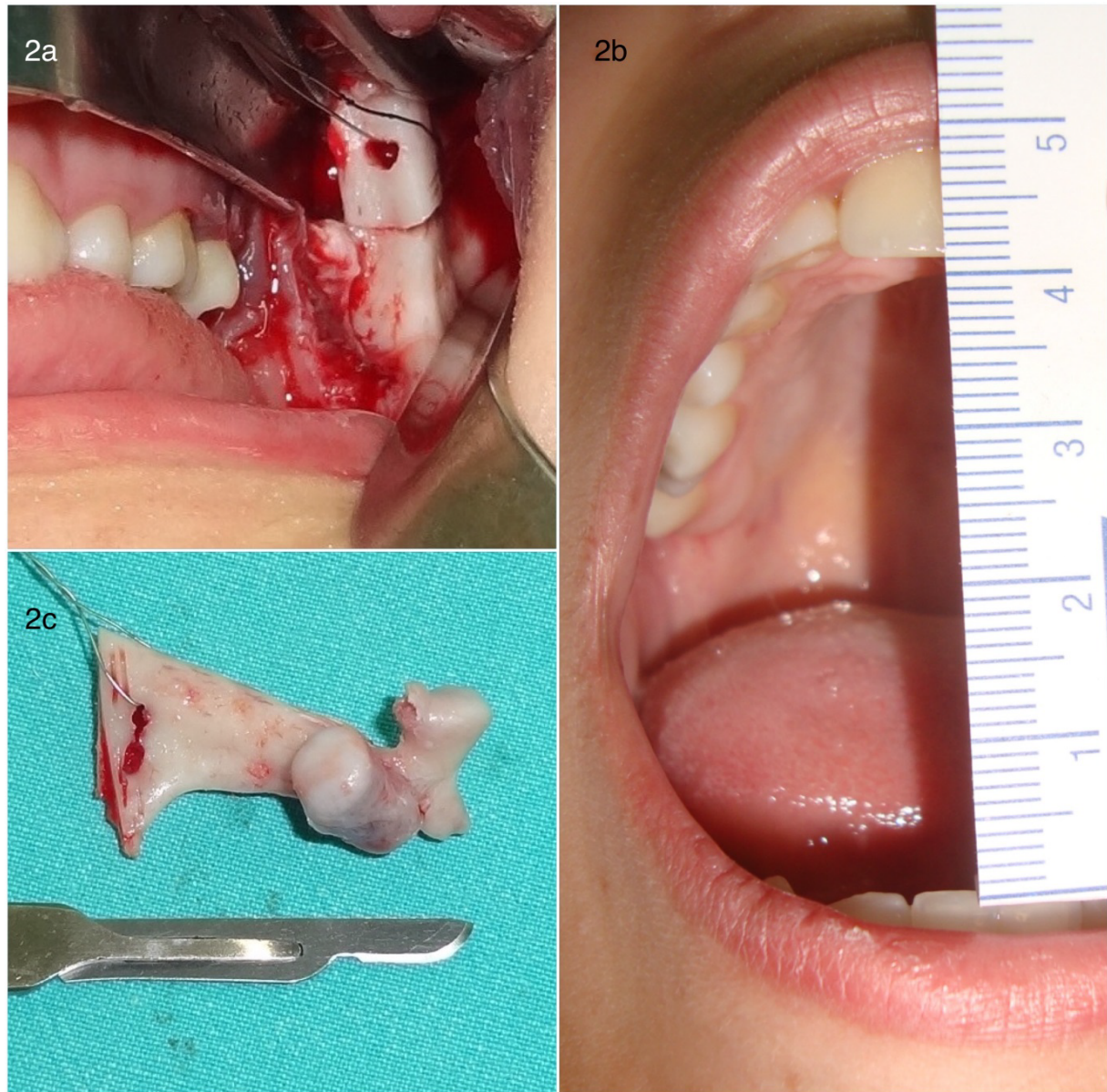

Figure 2: a) Intra-oral osteotomy of the coronoid process. b) Surgical specimen. Coronoid process with the tumor. c) Maximum interincisal mouth opening 1 year post-surgery.

References

1. D'Ambrosio N, Kellman RM, Karimi (2011) Osteochondroma of the coronoid process (Jacob's disease): an unusual cause of restricted jaw motion. *Am J Otolaryngol* 32: 52-54.
2. Jacob O (1899) Cause rare de constriction permanente des machoires. *Bull et Mem de la Société Anatomique de Paris* 1: 917-919.
3. Shackelford RT, Brown WH (1943) Osteochondroma of the coronoid process of the mandible. *Surg Gynecol Obstet* 77: 51-54.
4. Sreeramaneni SK, Chakravarthi PS, Prasad LK, Satish PR, Beeram RK (2011) Jacob's disease: report of a rare case and literature review. *Int J Oral and Maxillofac Surg* 40: 753-757.
5. Kersch A, Piette E, Tideman H, Wu PC (1993) Osteochondroma of the coronoid process of the mandible: Report of a case and review of the literature. *Oral Surg Oral Med Oral Pathol* 75: 559-564.
6. Hernández-Alfaro F, Escuder O, Marco V (2000) Joint formation between an osteochondroma of the coronoid process and the zygomatic arch (Jacob disease): report of case and review of literature. *J Oral Maxillofac Surg* 58: 227-232.
7. Emekli U, Aslan A, Onel D, Çizmeçi O, Demiryont M (2002) Osteochondroma of the coronoid process (Jacob's disease). *J Oral Maxillofac Surg* 60: 1354-1356.
8. Schwartz HC, Liebel DP (1987) Use of a hemicoronal scalp flap to approach an osteochondroma of the coronoid process. *J Oral Maxillofac Surg* 45: 545-547.
9. Roychoudhury A, Gupta YK, Parkash H, Karak AK (2002) Jacob disease: Report of a case and review of the literature. *J Oral Maxillofac Surg* 60: 699-703.
10. Stringer DE, Chatelain KB, Tandon R (2013) Surgical Treatment of Jacob's Disease: A Case Report Involving an Osteochondroma of the Coronoid Process. *Case Rep Surg* 25: 37-40.