

# “IPG” DET Minimal Invasive Sinus Implant Placement and Grafting without Sinus Floor Elevation – The Evolution of New Age Concepts

Panagiotis I Georgakopoulos<sup>1</sup>, Nikos Makris<sup>2</sup>, Maher Almasri<sup>3</sup>, Stavros Tsantis<sup>4\*</sup> and Ioannis P Georgakopoulos<sup>3</sup>

<sup>1</sup>University Alfonso X El Sabio, Dental School, Madrid, Spain

<sup>2</sup>Dentist Education Institute, Athens, Greece

<sup>3</sup>BPP University, School of Health, London, UK

<sup>4</sup>Technological Education Institution of Athens, Department of Biomedical Engineering, Athens, Greece

\*Corresponding author: Stavros Tsantis, Technological Education Institution of Athens, Department of Biomedical Engineering, Athens, Greece, Tel: +30 6977635864; Fax: +30 2132028608; E-mail: stsantis@teiath.gr

Rec date: Apr 08, 2016; Acc date: May 09, 2016; Pub date: May 16, 2016

Copyright: © 2016 Georgakopoulos PI, et al. This is an open-access article distributed under the terms of the Creative Commons Attribution License, which permits unrestricted use, distribution, and reproduction in any medium, provided the original author and source are credited.

## Abstract

**Background:** Dental implantology is considered as the most widely treatment employed in edentulous patients. So far, cases with vertical alveolar ridge deficiencies of the posterior areas of the upper jaw are treated primarily with sinus floor elevation in order to achieve successful and stable dental implantation.

**Method:** Employment of the “IPG” DET technique for the placement of forty-eight (48) implants in the posterior areas of the maxilla of twenty-seven (27) patients. Implant placement was made by means of a flapless approach – in which implants are entered both the sinus cavities – by intentional perforation of the Schneiderian membrane. Concentrated growth factors, as well as Alos-Block bone grafting material – were also utilized in this study, following a certain and precise protocol suggested by the authors.

**Results:** Cone Beam Computed Tomography exams were employed at two distinct temporal stages of Osseo-integration (0 and 8 months) and have proven the increment and bone structure growth formed bilaterally each implant and over the sinus floor. In addition, the primary stability of all implants was estimated with Implant Stability Quotient parameter showing high values that are suggestive of high implant stability.

**Conclusions:** Radiographic and clinical data support the concept of a one-step atraumatic procedure in implant placement with intentional perforation of the sinus membrane when there is ridge deficiency by means of the proposed technique.

**Keywords:** Dental implants; Osseo-integration; CBCT; Sinus floor elevation; Intentional sinus perforation

## Introduction

Contemporary oral treatment planning of partially or completely edentulous patients mainly involves dental implants employment. It is currently considered as routine procedure that has been proven successful by several clinical studies and has become acceptable by the majority of patients. Out dated techniques such as removable dentures are becoming less and less acceptable due to inherent mobility of the periodical ligament compared to the direct contact of the endosseous implant to the bone [1].

Despite promising clinical results of dental implants employment, implant stability is considered as prerequisite towards long term aesthetic results in dental implantology treatment procedure. A well designed treatment planning primarily involves bone augmentation and/or bone transplantation so as to accomplish optimal alveolar ridge dimensions [2,3]. Patients suffering from alveolar ridge deficiencies are treated either with extensive bone transplantation procedures or Sinus Floor Elevation (SFE) in order to accomplish a successful and stable dental implantation.

However, several clinical studies have reported maxillary sinusitis occurrence reaching a 20% of patients’ undergone SFA treatment procedure [4]. The latter unfortunate SFA consequence is considered as the main cause of implant and graft failure. Moreover, several other complications due to SFE employment have been presented in literature such as delayed wound healing which sequentially causes bone sequestration and haematoma [5-7]. The aforementioned limitations of the SFE procedure necessitate the introduction of alternative methods that could provide more accurate and reproducible results and can augment patient’s comfort and decrease operational cost.

Under that framework the recently introduced “IPG” DET8 – called the Ioannis P Georgakopoulos Dentist Education Institute Technique – has been proven a solid and reliable alternative to SFE [8].

“IPG” DET is a well-established and efficient dental implantation protocol that combines Concentrated Growth Factors (CGF with stem cells CD34+) along with bone grafting and intentional perforation of sinus membrane towards a rapid implant insertion. With “IPG” DET, sinus gains the ability to adapt to new conditions and form new bone bilaterally to implant thus avoiding an SFA procedure. Two implant placement techniques can be employed subsequent to “IPG” DET: the surgical approach or the flapless technique [9].

For the purposes of this study a new and greater clinical dataset has been utilised in order to evaluate the performance of "IPG" DET. All patients with implants placed in both sinuses have been examined by means of radiographic (Cone Beam Computed Tomography – CBCT scans) and clinical evaluation (by Osstell measurements) after an 8-month follow-up period so as to assess and measure implant stability.

## Material and Methods

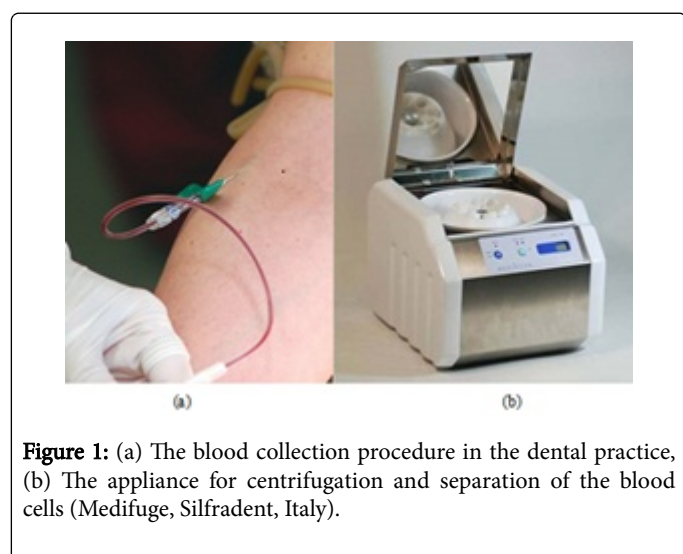
### Clinical dataset

Clinical material includes twenty-seven (27) patients (12 men and 15 women) acquired from March 2014 to September 2015, with mean age 54.4 years, and age ranging from 38 to 67 years. Exclusion criteria for participating in to the study were mainly diabetes, osteoporosis, cardiac and thoracic diseases, smoking and cancerous patients. All patients that were finally chosen had maxillary tooth loss and had chosen the surgical implant solution as advised by the dentists conducting this study. A total of 48 implants were placed employing "IPG" DET to the patients. They had all been informed of the requirements for participation in the study. The present study was performed in accordance to the ethical guidelines of the Helsinki Declaration while written informed consent was obtained from every patient participating in the study. CBCT scans confirmed the alveolar ridge deficiency in the majority of patients participated in the study.

Implants placement procedure has been performed atraumatically using the flapless technique which was preferred over the traditional surgical approach in order to eliminate postoperative infections and provide less discomfort to the patient [10].

### Surgical procedure and CGF

The initial step of "IPG" DET protocol involves the preparation of CGF with stem cells CD34+, in all its various forms [11]. At first, blood was drawn from the patient utilizing eight sterile tubes (9 ml each) and centrifuged in a special centrifuge device (Medifuge, Silfradent srl, St. Sofia, Italy) for approximately 14 minutes (Figures 1a and 1b).

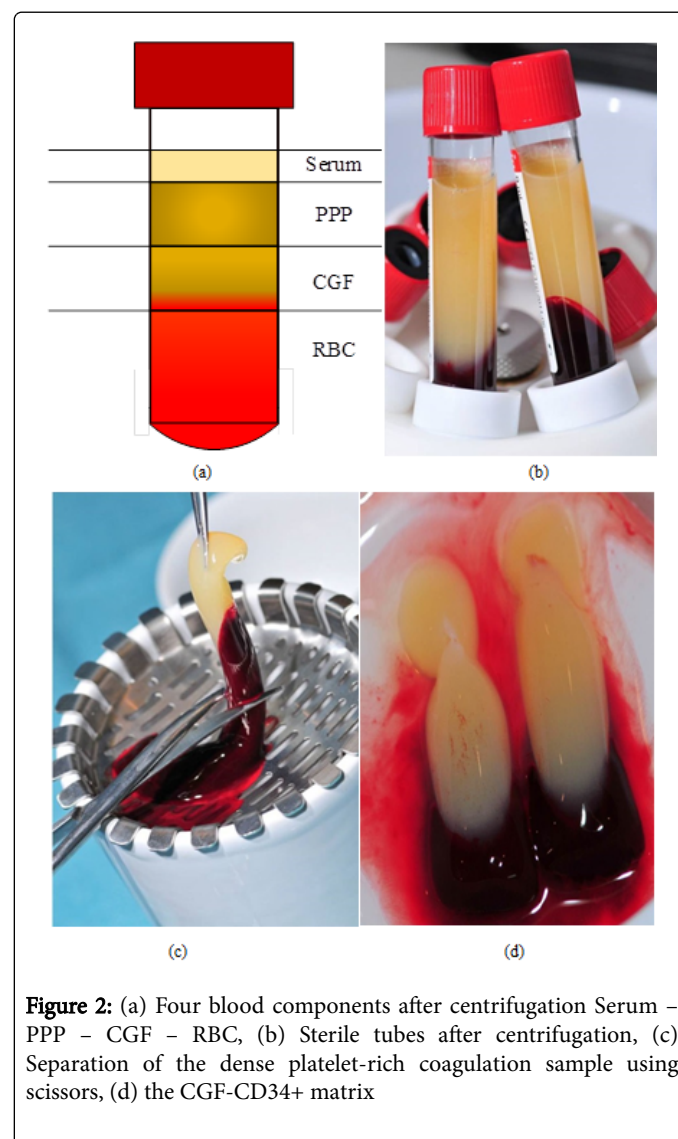


**Figure 1:** (a) The blood collection procedure in the dental practice, (b) The appliance for centrifugation and separation of the blood cells (Medifuge, Silfradent, Italy).

For optimum quality of CGF matrices the blood samples were centrifuged immediately after the blood was drawn. After centrifugation, in each sterile tube four components can be easily

identified from top to bottom: the superior phase represented by the serum (blood plasma without fibrinogen and coagulation factors). The interim phase represented a very large and dense polymerized fibrin buffy coat divided in two distinct intermediate phases: the upper Platelet Poor Plasma (PPP), and the lower fibrin rich gel with aggregated platelets and Concentrated Growth Factors (CGF). And, at the bottom of the tube the Red Blood Cell portion (RBC) (Figure 2a) [11,12]. A large number of growth factors and stem cells CD34+ are aggregated between the lower middle layer (CGF) and the upper 3-4 mm of red blood corpuscles mass of the bottom layer (Figures 2a and 2b). It has been shown that the number of CD34 positive cells in 10 high-power fields for ten sections, was approximately ten-times higher in the CGF with respect to the RBC layer [11]. Current research involves the clinical implication of CD34 positive cells within the CGF network.

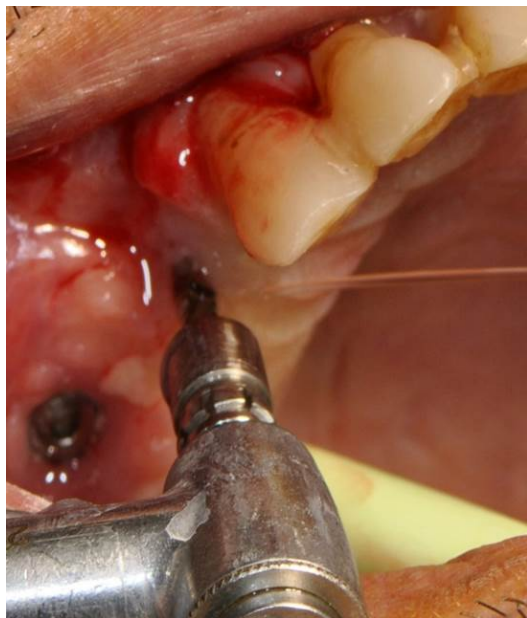
This growth factors-rich segment is separated from the rest of the red corpuscles using scissors (Figure 2c) in order to obtain the CGF-CD34+ matrix (Figure 2d).



**Figure 2:** (a) Four blood components after centrifugation Serum – PPP – CGF – RBC, (b) Sterile tubes after centrifugation, (c) Separation of the dense platelet-rich coagulation sample using scissors, (d) the CGF-CD34+ matrix

Following the the preparation of CGF with stem cells CD34+, povidine-iodine solution (Betadine) was employed extra-orally to

disinfect the surgical site to reduce microbial contamination probability. Infiltration was then performed using a 2% lidocaine solution containing a ratio of 1:100,000 epinephrine. In each predetermined site, the osteotomy was extended all the way through the whole bone height available, until the sinus membrane was intentionally perforated (Figure 3).



**Figure 3:** Intentional perforation of the sinus membrane

The CGF matrix, created in the previous process of blood centrifugation, was placed within the osteotomy site in two distinct consecutive stages. At first stage, one half of the matrix was inserted through the osteotomy site and into the sinus by means of the fibrin injector (Silfradent-Italy), which proved to be a great tool for the swift insertion of the fibrin gel block (Figure 4a).

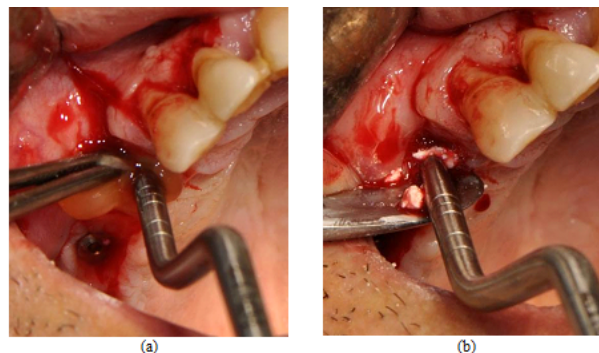
The remaining half of CGF matrix (highly CGF and stem cells) was then cut into small pieces and mixed with a small quantity of the alloplastic bone grafting material Alos Block (0.5 ml, by Medirel-Italy). This mixture is then placed within the osteotomy site (Figure 4b) – stage 2.

"IPG" DET protocol involves one additional step for faster osseointegration of the implants. Each implant was immersed into a Liquid Phase of the Concentrated Growth Factors (LPCGF) in order to create a "bioactive" membrane around it. The LPCGF was prepared by squeezing some of the remaining seven CGF-CD34+ matrices by means of the CGF-forceps (Silfradent, Italy – Figure 5a) and was collected in a sterilized container.

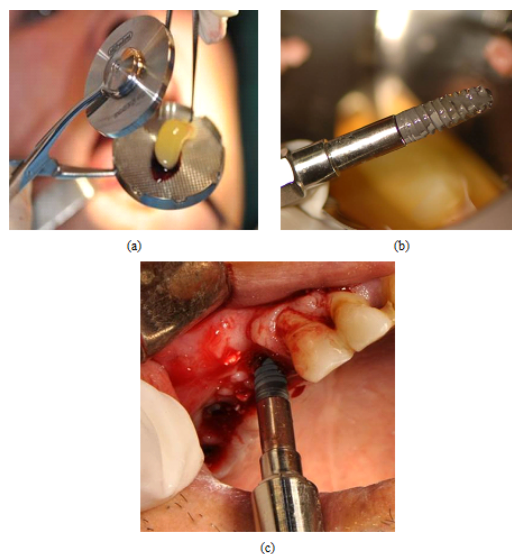
Each implant was carefully and fully immersed into the liquid phase CGF (Figure 5b). All implants were then placed using a hand wrench with a measured insertion torque between 20-25 N/cm<sup>2</sup> (Figure 5c). Low insertion torque values are expected due to the small bone heights at all the implant sites.

Following the "IPG" DET protocol application, certain clinical guidelines are given to each patient. They are forbidden to blow their

nose for the first three to five days and keep their nose open by means of Otrivin nasal drops.



**Figure 4:** (a) Insertion of the fibrin gel block within the osteotomy site by means of Fibrin injector, Silfradent-Italy, (b) placement in the osteotomy site of highly CGF, stem cells CD34+ mixed with bone grafting material.



**Figure 5:** (a) Process of LPCGF with CD34+ production utilizing the CGF-forceps, (b) Implant immersions into LPCGF, towards the creation of a CGF bio-energetic membrane around its surface, (c) initial implant placement with minimal invasive procedures during "IPG" DET employment.

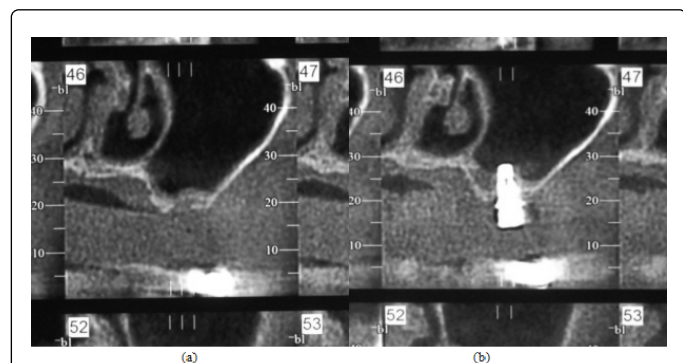
## Results

The Osseointegration procedure was evaluated and measured both visually in terms of Radiographic scans and clinically via stability values derived from Osstell readings.

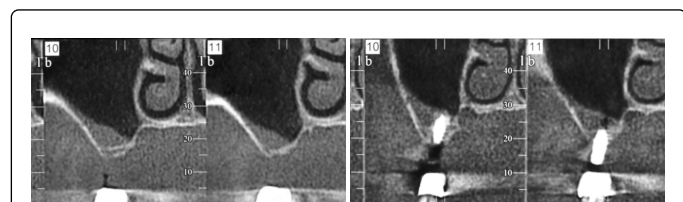
## Radiographic evaluation

Figures 6 and 7 show CBCT scans at various tooth areas depicting extensive bone formation at the implant surgical site. In both figures

bone formation within the sinus cavity and bilaterally of the implant are indicative of the "IPG" DET high performance.



**Figure 6:** (a) Implant in tooth areas #46-47 in which the ridge height did not exceed 2 mm. (b) The same site 8 months after the implant placement following the proposed. Bone regeneration in the sinus, around the implant is apparent.



**Figure 7:** (a) Implant in tooth areas #10-11. (b) The same site 8 months after the implant placement following the proposed. Bone regeneration in the sinus, around the implant is also apparent.

### Clinical evaluation

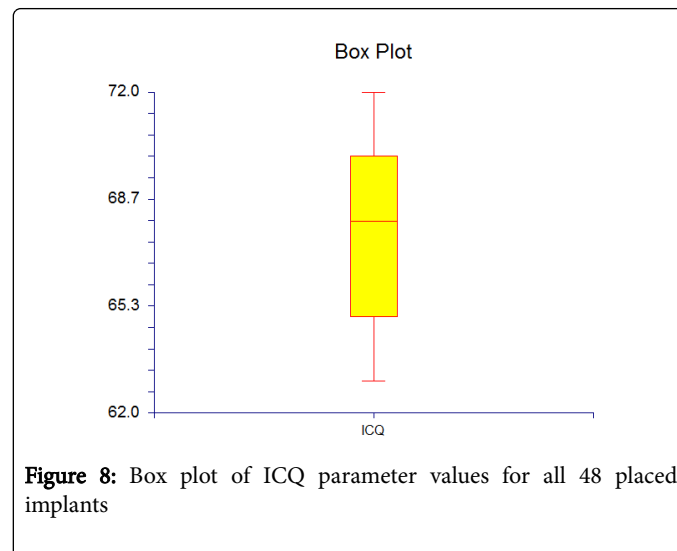
Clinical evaluation held in this study was made by means of stability values provided by Resonance Frequency Analysis (RFA) employing Osstell equipment in each inserted implant [13]. RFA is mainly a bending test employed at the bone to implant interface. It measures the frequency of a vibrating device. A resonant frequency comparison is made depending that different frequencies correspond to different stabilities. High stability values provide high frequencies. The Osstell procedure involves a sensor placement on top of the implant that is stimulated by magnetic pulses from a handheld electronic device. Due to stimulation, the sensor vibrates for a short period of time. In cases of high implant stability (stiffness of the bone to implant interface) the vibrating frequency increases accordingly. The parameter measured is named Implant Stability Quotient (ISQ). It ranges from 0 to 100 ISQ units, with high values indicating high stability of the implant. It considered as an indirect measurement of Osseo-Integration.

ISQ values derived from the clinical evaluation procedure made in all placed implants ranged between 63 and 72 (Figure 8). When ISQ values range between 60 and 70, micro-mobility decreases approximately 50% [13].

### Discussion

Periodontal tissues with decreased aesthetics and functional ability along with alveolar dysfunction are considered as indicative of future

tooth loss. Several Osseo-regenerative methods are widely employed to restore the alveolar process so as to ensure the aesthetic and functional integrity of the implants inserted.



**Figure 8:** Box plot of ICQ parameter values for all 48 placed implants

Alveolar ridge deficiencies are treated primarily with SFA regenerative procedures. Nevertheless SFA is considered responsible for several side effects such as delayed wound healing and maxillary sinusitis. It also must be mentioned that SFA procedures also are cost and time effective and highly dependable on the operator's experience. Despite the aforementioned complications, SFA has gain the acceptance of the majority of patients, especially when no alternatives are given by the dentists. If informed otherwise most patients would have chosen an alternative non-surgical, non-invasive and painless option.

Throughout this study and in a greater clinical dataset, "IPG" DET has been proven as a solid and reliable alternative to SFE. Key points of "IPG" DET are the integration of concentrated growth factors (CGF with stem cells CD34+) along with bone grafting and intentional perforation of sinus membrane towards a rapid implant insertion. The two-stage insertion of CGF-CD34+ is also an innovative procedure providing a more solid environment for the implant to be placed combined with the regenerative ability of the sinus membrane.

Also, the ability given to place the dental implant atraumatically without having to perform SFA is considered as a major advantage. The obvious bone Osseo-integration procedure depicted by CBCT scans and high stability values provided by Osstell readings have constitute "IPG" DET as stable and reproducible dental implant method. Moreover, none of the patients participated in the current study has demonstrated any kind of complication or infection proving that "IPG" DET can be considered as safe procedure.

No significant symptoms have been observed throughout the first days of the "IPG" DET employment. The atraumatically dental placement is considered as the primary cause for the asymptomatic behavior of the patients. Minor pain and swelling has been reported in less than 12% of the participated patients that has been addressed medically.

A nine (9) period of time was selected for the fixed partial denture insertion in order for the Osseo-integration procedure to mature and provide a stable environment. In older cases treated with the proposed technique the bone height augmentation is still maintained.

## Conclusion

The results of "IPG" DET support the concept of a one-stage, flapless – whenever possible – implant placement. However adequate training on how to perform this technique is considered of value before any effort made to perform the presented technique.

## References

1. Buser D, Janner SF, Wittneben JG, Brägger U, Ramseier CA, et al. (2012) 10-year survival and success rates of 511 titanium implants with a sandblasted and acid-etched surface: A retrospective study in 303 partially edentulous patients. *Clin Implant Dent Relat Res* 14: 839-851.
2. Ravald N, Dahlgren S, Teiwik A, Gröndahl K (2013) Long-term evaluation of Astra Tech and Brånemark implants in patients treated with full-arch bridges. Results after 12-15 years. *Clin Oral Implants Res* 24: 1144-1151.
3. Buser D, Martin W, Belser UC (2004) Optimizing esthetics for implant restorations in the anterior maxilla: anatomic and surgical considerations. *Int J Oral Maxillofac Implants* 19 Suppl: 43-61.
4. Santagata M, Guariniello L, Rauso R, Tartaro G (2010) Immediate loading of dental implant after sinus floor elevation with osteotome technique: a clinical report and preliminary radiographic results. *J Oral Implantol* 36: 485-489.
5. Summers RB (1994) The osteotome technique: Part 3--Less invasive methods of elevating the sinus floor. *Compendium* 15: 698, 700, 702-704 passim.
6. Timmenga NM, Raghoebar GM, Boering G, van Weissenbruch R (1997) Maxillary sinus function after sinus lifts for the insertion of dental implants. *J Oral Maxillofac Surg* 55: 936-939.
7. Timmenga NM, Raghoebar GM, van Weissenbruch R, Vissink A (2001) Maxillary sinusitis after augmentation of the maxillary sinus floor: a report of 2 cases. *J Oral Maxillofac Surg* 59: 200-204.
8. Georgakopoulos IP, Gialidis SN, Tsantis S, Georgakopoulos P, Itziou PV, et al. (2014) A case-Study of Seven Implants Placed in the Maxillary Sinus With Intentional Schneiderian's Membrane Perforation. *Journal of Implant and Advanced Clinical Dentistry* 6: 9-19.
9. Campelo LD, Camara JR (2002) Flapless implant surgery: a 10-year clinical retrospective analysis. *Int J Oral Maxillofac Implants* 17: 271-276.
10. Toffler M (2004) Minimally invasive sinus floor elevation procedures for simultaneous and staged implant placement. *N Y State Dent J* 70: 38-44.
11. Rodella LF, Favero G, Boninsegna R, Buffoli B, Labanca M, et al. (2011) Growth factors, CD34 positive cells, and fibrin network analysis in concentrated growth factors fraction. *Microsc Res Tech* 74: 772-777.
12. Sohn DS, Heo JU, Kwak DH, Kim DE, Kim JM, et al. (2011) Bone regeneration in the maxillary sinus using an autologous fibrin-rich block with concentrated growth factors alone. *Implant Dent* 20: 389-395.
13. Sennerby L, Meredith N (2000) Implant stability measurements using resonance frequency analysis: biological and biomechanical aspects and clinical implications. *Periodontol* 47: 51-66.