

# Incidence of *Isospora belli* in Leukemic Children in Erbil City

Wisam Mahdi Al-Saeed<sup>1\*</sup>, Hussein Mahmoud Abdullah<sup>2</sup>

<sup>1</sup>Department of Microbiology, College of Medicine, Mustansiriyah University, Baghdad, Iraq; <sup>2</sup> Department of nursing, Erbil Medical Technical Institute, Erbil Polytechnic University, Kurdistan, Iraq

## ABSTRACT

This study was conducted in Erbil city to investigate the incidence of *Isospora belli* infection among leukemic children, by laboratory examination of stool samples obtained from 26 children suffering from leukemia using different methods like N. saline, Iodine fecal smears, Sheathers flotation and modified Ziel-Neelson techniques. *Isospora belli* was detected in only one out of 26 (3.8%) ill children. To investigate the rate of infection with *Isospora belli* in children suffering from diarrhea especially the immunocompromised and leukemic group.

**Keywords:** *Isospora belli*; Leukemic Children; Isosporiasis

## INTRODUCTION

*Isospora belli* is a coccidian protozoan parasite related to the phylum Apicomplexa that parasitizes epithelium of upper small intestine of humans and causes diarrheal disease [1]. It is taxonomically related to *Cryptosporidium spp.*, *Cyclospora spp.* and *Toxoplasma* [2]. Infections of this parasite are cosmopolitan in distribution, but more common in tropical, subtropical regions, Middle East, and areas with poor sanitation [3], it is associated with outbreaks of diarrhea in mental wards and daycare centers [2]. This organism is the only member of the genus that infect human, and transmitted through contaminated water and food [4].

Most of the infections are asymptomatic. Symptomatic isosporiasis is mainly characterized by watery diarrhea, abdominal pain, vomiting, dehydration, malabsorption, weight loss, and peripheral eosinophilia. Although, chronic and severe illness in infants, young children, and healthy adults has been reported [5], in healthy hosts the illness is typically self-limiting. However, in patients with immunodeficient states and acute lymphoblastic leukemia, the illness is chronic and may be associated with severe dehydration and debilitation [3].

As with other Coccidian, *I. belli* has both sexual and asexual life cycle. The infection is acquired through the ingestion of sporulated oocysts. Sporozoites were released in the intestinal lumen and invade intestinal epithelial cells, within the epithelial cells the parasite undergoes a round of merogony process (asexual stage) leading to the production of merozoites.

The released merozoites reinvade intestinal epithelial cells and can undergo additional rounds of merogony or develop into either

micro- or macrogamonts (sexual stage). Microgametes will fertilize the macrogametes to form a zygote which develops into the oocyst. Immature oocysts are passed in the feces and maturation to the infectious sporulated oocysts occurs in the environment. Recognizable stages during this maturation (i.e., sporogony) include oocysts with a single sporoblast, oocysts with two sporoblasts, and the mature oocyst with two sporocysts, each with four sporozoites [2,3].

Detection of *Isospora* is made by direct or concentrated wet smears of fresh or preserved stool specimens, rather than permanent stained smears. In wet smears, oocysts are pale transparent, oval, measures 20 to 33 µm by 10 to 19 µm, and generally contain only one or two immature sporoblasts [6]. The acid-fast stain is another detection method, by which the oocyst stained red [7].

For the treatment of isosporiasis, trimethoprim-sulfamethoxazole is the drug of choice. Ciprofloxacin also used but it is less effective [8].

## METHODOLOGY

This study was conducted among 26 leukemic child from Nanakali hospital of Malignant diseases in Erbil City, during June 2010. Ten of them had acute myeloid leukemia (AML) and 16 had acute lymphocytic leukemia (ALL).

Stool specimens were collected from ill children in a tightly covered wide mouth, disposable plastic containers. These were labeled with a number, date and name of each subject. Macroscopic examination was done for evaluating the consistency, color, presence of pus, mucus or blood in the stool samples.

**Correspondence to:** Wisam Mahdi Al-Saeed, Department of Microbiology, College of Medicine, Mustansiriyah University, Baghdad, Iraq, Tel: +9647724731339; E-mail: wisam.alsaheed@yahoo.com

**Received:** August 26, 2019; **Accepted:** September 09, 2019; **Published:** September 19, 2019

**Citation:** Al-Saeed WM, Abdullah H (2019) Incidence of *Isospora belli* in Leukemic Children in Erbil City. J Bacteriol Parasitol. 10:361. doi: 10.35248/2155-9597.19.10.361.

**Copyright:** © 2019 Al-Saeed WM, et al. This is an open-access article distributed under the terms of the Creative Commons Attribution License, which permits unrestricted use, distribution, and reproduction in any medium, provided the original author and source are credited.

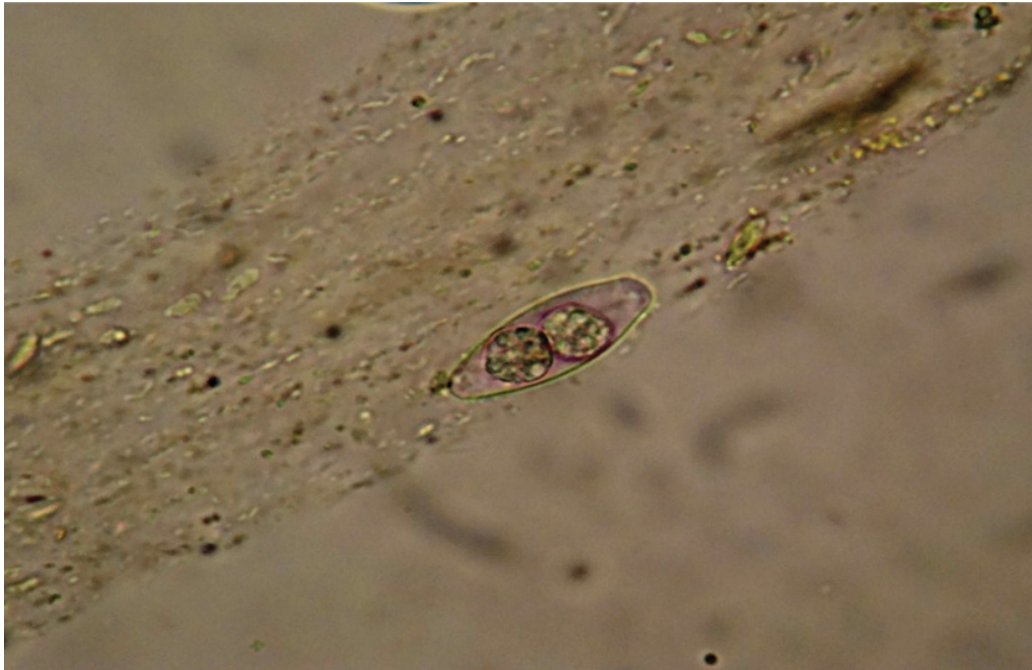


Figure 1: *Isospora belli* (mature oocyst containing two sporocysts) using Sheather 's sugar flotation technique (40X).

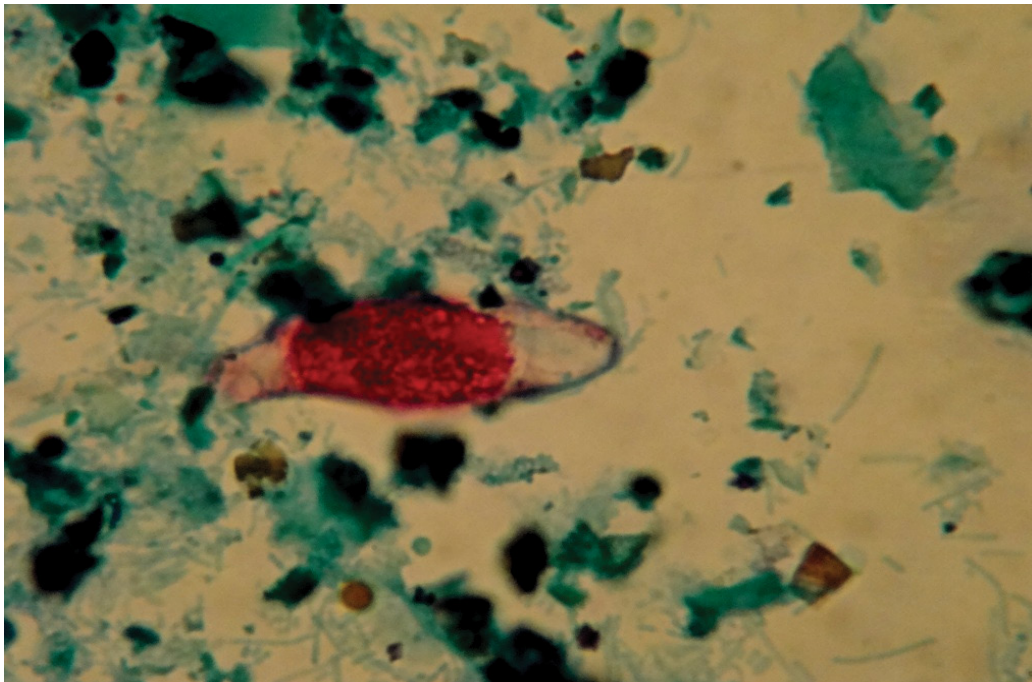


Figure 2: *Isospora belli* (immature oocyst containing a sporoblast) Stained with modified Ziehl-Neelson stain.

### Direct saline and iodine mount

A drop of N. saline was placed in the left half, and another drop of lugols iodine was placed in the right half of the slide.

With an applicator stick a small portion of stool specimen was picked up and mixed with N. saline, and another small amount was picked up and mixed with iodine. The two smears (saline and iodine) were covered with cover slip. Preparation was examined under microscope using objective lens 10X then 40X magnification power.

In iodine mount *Isospora* oocysts appear light brown ovoidal bodies with dark brown wall. Sheathers sugar flotation technique were also used as a concentration method in scanty infection (Figure 1).

Modified Ziehl-Neelson technique was used in the positive sample to confirm diagnosis (Figure 2).

### RESULTS AND DISCUSSION

*Isospora belli* was detected only in one (3.8%) out of 26 leukemic children, which was mixed with *G. lamblia*.

For the first time in Erbil city *Isospora belli* was detected in one case (3.4%) among children suffering from leukemia which was mixed with *Giardia* infection. This finding is similar to that recorded in Ethiopia, in a study done by adamu et.al., whom found (2.3%) of children under five years of age suffering from diarrhea [9-12].

*Isospora belli* is known to be a rare cause of childhood diarrhea. For example, in India, Mirdha et al. detected only (0.17%) of the

symptomatic isosporiasis among children with diarrhea and in Iran Nahravanian, Assmer detected only one case among 23 AIDS patients 4.3%.

## CONCLUSION

Inspite the isosporiasis is rare infection but there is a few records in children those whom received immunosuppressive drugs or anticancer treatment and should be kept in mind when we search for the causative agent of diarrhea in children.

## REFERENCES

1. Singh A, Houpt E, Petri WA. Rapid diagnosis of intestinal parasitic protozoa, with a focus on *Entamoeba histolytica*. *Interdiscip Perspect Infect Dis*. 2009. pp: 1-8.
2. Marshal MM, Noumovtz D, Ortega Y, Sterling CR. Waterborne protozoan pathogens. *Clin Microbiol Rev*. 1997;10(1):67-85.
3. Lindsay DS, Dubey JP, Blagburn BL. Biology of *Isospora* spp. from humans, nonhuman primates, and domestic animals. *Clin Microbiol Rev*. 1997;10(1):19-34.
4. Escobedo AA, Almira P, Alfonso M, Cimerman S, Rey S, Terry SS. Treatment of intestinal protozoan infections in children. *Arch Dis Child*. 2009; 94(6):478-482.
5. Meamar AR, Rezaian M, Zare Mirzaei A, Zahabiun F, Faghihi AH, Oormazdi H. Severe diarrhea due to *Isospora belli* in a patient with thymoma. *J Microbiol Immunol Infect*. 2009;42(6):526-529.
6. Wittner M, Tanowitz HB, Weiss LM. Parasitic infectin in AIDS patients. Cryptosporidiosis, isosporiasis, microsporidiosis, cyclosporiasis. *Infect Dis Clin North Am*. 1993;7(3):569-586.
7. Mannheimer SB, Soave R. Protozoal infections in patients with AIDS, Cryptosporidium, isosporiasis, cyclosporiasis and microsporidiosis. *Infect Dis Clin North Am*. 1994;8(2):483-498.
8. Sears CL, Kirkpatrick BD. Cryptosporidiosis and Isosporiasis. In: Gillespie SH, Pearson RD. (Eds) *Principles and practice of clinical parasitology*. John Wiley & Sons Ltd. England. 2001. pp: 139-164.
9. Adamu H, Endeshaw T, Teka T, Kifle A, Petros B. The prevalence of intestinal parasites in pediatric diarrheal and immunocompromised patients in the Islamic Republic of Iran. non- diarrheal patients in Addis Ababa hospitals, with special emphasis on opportunistic parasitic infections and with insight into the demographic and socio-economic factors. *Ethiop J Health Dev*. 2006;20(1):39-46.
10. Al Braiken FA, Amin A, Beeching NJ, Hommel M, Hart CA. Detection of *Cryptosporidium* amongst diarrheic and asymptomatic children in Jeddah, Saudi Arabia. *Annals Trop Med & Parasitol*. 2003;97(5):505-510.
11. Mirdha BR, Kabra SK, Samantray JC. Isosporiasis in children. *Indian*