

Iatrogenic Urinomas Identified by ^{99m}Tc DTPA Renal Scintigraphy

Padma Subramanyam*, Shanmuga Sundaram Palaniswamy, Anshu Tewari and Praveen Kumar SLG

Department of Nuclear Medicine and PETCT, Amrita Institute of Medical Sciences, Cochin, Kerala, India

Abstract

Urine leaks can occur from the kidney, ureter, bladder, and urethra, and is usually attributed to an iatrogenic cause. Urinomas are collection of extravasated urine that may be initially occult and may lead to complications such as abscess formation and electrolyte imbalances if not promptly diagnosed and appropriately managed. It is important not only to diagnose urine leaks but also to determine their cause and extent, thus imaging specialists play a key role. We present two iatrogenic cases of urinomas, one from the ureter and the other from the kidney that were diagnosed by ^{99m}Tc Technetium Diethylene triamine penta acetic acid (^{99m}Tc DTPA) renogram. Initially contrast enhanced computed tomography reported the first case to be a large ovarian cyst, while the other case was reported to be a pyogenic abscess. ^{99m}Tc DTPA renogram is a highly reliable, non invasive investigation with a physiological basis. It can be used not only for diagnosing urine leaks but also for assessing individual renal function as there may be an underlying renal disarrangement in such patients.

Keywords: Tc DTPA renogram; Urine leak; Urinoma; Iatrogenic cause

Introduction

Urine leaks and urinomas result from disruption of the urinary tract, potentially occurring at any level from the renal calyx to the urethra [1]. Clinical presentation may vary according to their extent and location. Small loculated collections may simply present as a cystic intra abdominal mass, with or without abdominal pain, while large collections may produce anuria and symptoms due to mass effect on neighbouring structures like rectum etc. Based on these factors, there is a high chance to misdiagnose this condition as ordinary ascites, abdominal or pelvic abscesses or hematomas, cystic masses, or pancreatic pseudocysts [2]. Urinomas may occur either after an injury to the upper urinary tract, renal or at urethral level or at times may occur spontaneously. The former can be traumatic or iatrogenic during, e.g. pyelolithotomy, pyeloplasty, ureterolithotomy, vaginal or abdominal hysterectomy, rectal dissection, or percutaneous urological interventional procedures [1]. Spontaneous extravasation occurs if there is a distal obstruction, e.g. a ureteric calculus [2], peri-ureteric masses or papilloma of the renal pelvis [3,4], and is generally caused by fornical rupture. When the amount of urine exceeds the capacity of lymphatic clearance, a perirenal fluid is generated [5,6]. Diagnostic imaging plays a crucial role in promptly identifying these leaks and determining their cause and extent. We present two iatrogenic cases of urinomas, one from the ureter and the other from the kidney that were diagnosed by ^{99m}Tc DTPA renogram.

Case 1

She is a 43 years old patient under evaluation for primary infertility. Patient underwent multiple diagnostic and therapeutic laparoscopies for endometriosis. She also had right hydronephrosis and underwent ureteric reimplantation. On 10th postoperative day, patient presented with abdominal pain and acute urinary retention. After urinary catheterization, abdominal multidetector contrast enhanced computed tomography (MDCT) revealed a large ovarian cyst with mass effect over the uterus. The multi septated cystic lesion (Figure 1a) measures 12×11 cm in its maximum transaxial dimension and was seen posterior to uterus and urinary bladder compressing and displacing the same anteriorly. Magnetic Resonance Imaging (MRI) of pelvis (Figure 1b) showed a large pelvic multiloculated cystic lesion

exerting mass effect over the rectum and bladder with moderate right hydronephrosis. As patient had a sudden elevation of serum creatinine levels, she was referred to our department to investigate a post-renal/obstructive cause of renal failure and was scheduled for a DTPA renogram.

DTPA renogram (Figure 1c) was performed with 4 mCi of intravenous ^{99m}Tc DTPA. Anterior and posterior dynamic images revealed a urine leak from the right ureter, apparently from the anastomotic site. The cystic lesion detected by CT and MRI was actually an urinoma. Dynamic DTPA images in the anterior projection shows progressive DTPA accumulation compatible with an urinoma probably from a ureteric origin (marked by an arrow). Renal function is preserved and total Glomerular Function Rate (GFR) is 73 ml/min. GFR is defined as the volume of fluid filtered from the kidney i.e. glomerular capillaries into the Bowman's capsule per unit time. This abnormal pelvic collection of tracer was found to communicate with the right ureter suggesting a significant urine leak. Surgical exploration was accomplished at the site of leakage.

Case 2

A 41 year old diabetic female with right uretero-pelvic junction obstruction by renal calculi underwent Endo-pyelotomy and ESWL (Extracorporeal shock wave lithotripsy) about two years ago. Subsequently an open pyelolithotomy and right pyeloplasty were performed on year after. About 7 months later, she developed right sided loin pain, vomiting and fever.

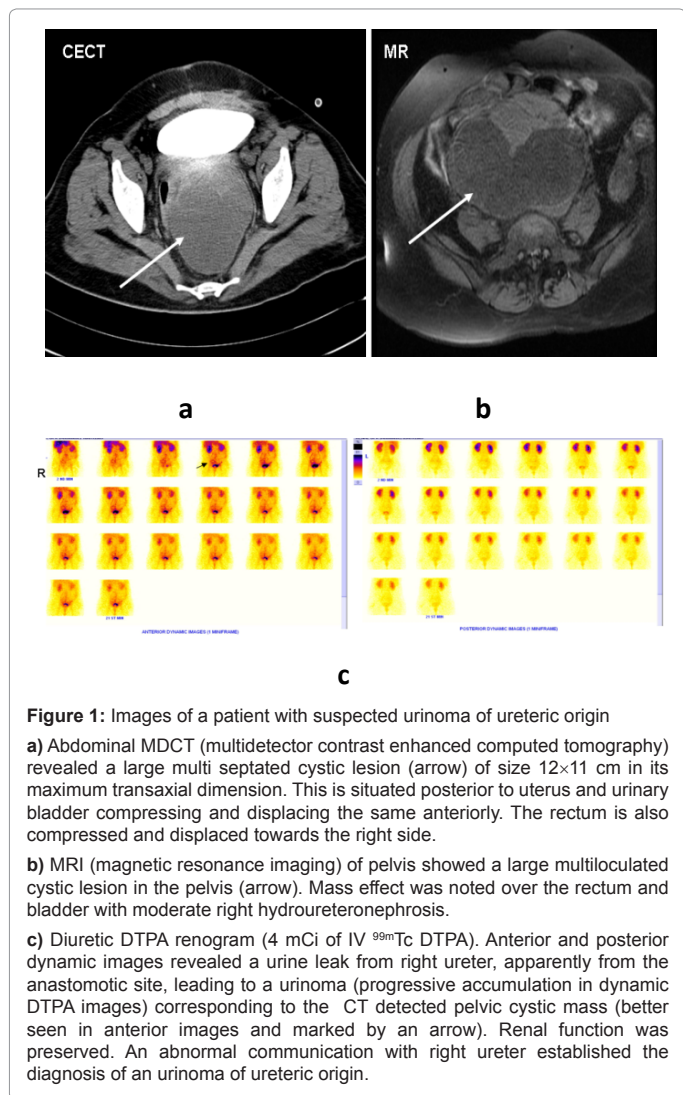
At physical examination she was afebrile, presenting a surgical

***Corresponding author:** Padma S, Clinical Professor, Department of Nuclear Medicine and Pet Ct, Amrita Institute of Medical Sciences and Research Centre, Cochin-682041, Kerala, India, Tel: 91-484-2852001; Fax: 91-484-2852003; E-mail: padmas@aims.amrita.edu

Received January 28, 2013; Accepted July 17, 2013; Published July 22, 2013

Citation: Subramanyam P, Palaniswamy SS, Tewari A, Praveen Kumar SLG (2013) Iatrogenic Urinomas Identified by ^{99m}Tc DTPA Renal Scintigraphy. Trop Med Surg 1: 131. doi:10.4172/2329-9088.1000131

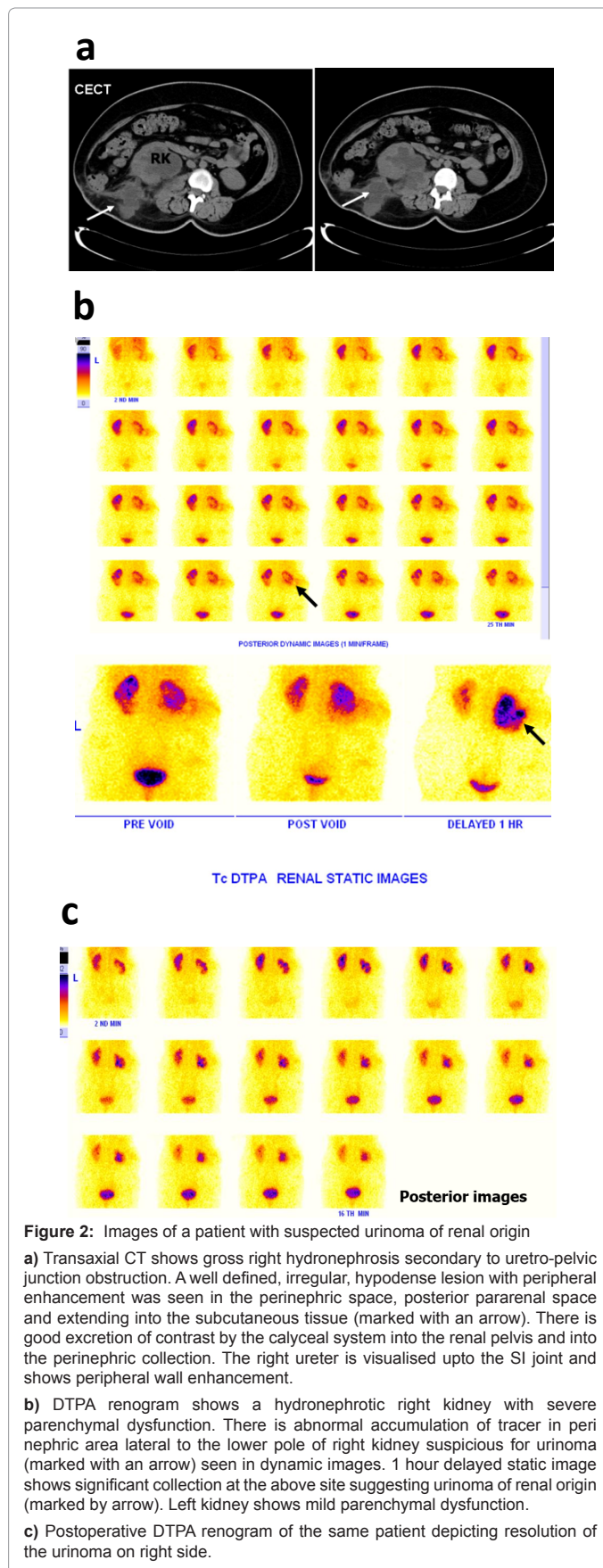
Copyright: © 2013 Subramanyam P, et al. This is an open-access article distributed under the terms of the Creative Commons Attribution License, which permits unrestricted use, distribution, and reproduction in any medium, provided the original author and source are credited.



scar on her right abdominal flank with palpation presenting evidence of a tender mass on the right renal fossa. CT demonstrated (Figure 2a) a gross right hydronephrosis secondary to right Uretero-Pelvic Junction obstruction (UPJ). A well defined, irregular, hypodense lesion with peripheral enhancement was seen in the right perinephric space (marked with an arrow). DTPA renogram (Figure 2b) revealed a right hydronephrosis with severe right parenchymal dysfunction. There was an abnormal accumulation of tracer in the peri nephric area adjacent to lower pole of right kidney, suspicious for urinoma of renal origin. Left kidney revealed mild parenchymal dysfunction. Patient underwent surgical re exploration and postoperative DTPA renogram (Figure 2c) showed complete resolution of the right urinoma.

Discussion

Urine leaks and urinoma usually result from blunt or penetrating renal trauma that may occur as a disruption of the calyces, infundibulum or renal pelvis. Also there should be a high clinical suspicion in postoperative cases of renal disorders to diagnose urinomas in that context. Although physical examination is frequently normal, a fluctuant mass with abdominal pain can be present at times. Imaging modalities used for diagnosis include abdominal radiograph, ultrasonography, DTPA renogram and CT. Abdominal radiography is



not very sensitive but may show a pararenal opacity with obliteration of the ipsilateral psoas shadow or renal outline [7]. Ultrasonography or CT of the abdomen will only detect a fluid collection or a cystic mass but may not differentiate haematoma, abscess, seroma, urinoma or lymphocele [8]. DTPA being a glomerular agent identifies subtle early glomerular dysfunction apart from highlighting the presence of any associated pelviureteric or vesicoureteric obstruction [2,9]. If a urine leak is suspected, Intravenous Urography (IVU) may indicate the site and provide an estimate of the rate of leakage. Although it exposes the patient to a relatively high dose of radiation, has to be used with caution in patients with compromised renal function and associates the risk of contrast medium-induced nephropathy and allergic reactions. Management of these urine leaks is purely surgical and dependent on the location and extent of the injury level in the urinary tract [10,11].

Conclusion

Urine leaks are infrequent but notorious cause of loss of renal function due to hydronephrosis or abscess formation. As symptoms may be non-specific, patients may present at various time frames, early diagnosis and prompt management are deemed necessary. DTPA renogram is a simple, non-invasive, outpatient procedure which is safe in all age groups and even in patients with poor renal function. It produces no adverse effects and carries minimal radiation exposure to patients. By delineating the site of leakage and estimating the rate of leakage, it helps to formulate the optimal management strategy and is valuable in selecting a conservative or surgical approach. It can also help to select the most appropriate site for surgical exploration.

References

1. McInerney D, Jones A, Roylance J (1977) Urinoma. Clin Radiol 28: 345-351.
2. Padhy AK, Gopinath PG, Mehta SN, Tiwari DC, Dhawan IK (1989) Technetium-99m DTPA renal transplant imaging in the diagnosis of urinoma. Clin Nucl Med 14: 769-771.
3. Clarke H (1955) Spontaneous rupture of the kidney pelvis. Br J Urol 27: 162-164.
4. Southwell PB (1971) Spontaneous renal extravasation with urinary retention. Case report. Australas Radiol 15: 246-247.
5. Clayman RV, McDougall EM, Figenshan R (1996) Endourology of the upper urinary tract: non calculus applications. In Spirnak PS, Resnick MI, eds. Adult and Paediatric Urology, 3rd edn. London: Mosby-Yearbook Inc 815-817.
6. Karayalcin B, Karayalcin U, Gungor F, Aslan S, Yildiz A (1992) The value of ^{99m}Tc-DTPA renal scintigraphy in the evaluation of post-traumatic abdominal fluid collection. Ann Nucl Med 6: 199-202.
7. Gayer G, Zissin R, Apter S, Garniek A, Ramon J, et al. (2002) Urinomas caused by ureteral injuries: CT appearance. Abdom Imaging 27: 88-92.
8. Moyle PL, Kataoka MY, Nakai A, Takahata A, Reinhold C, et al. (2010) Nonovarian cystic lesions of the pelvis. Radiographics 30: 921-938.
9. al-Janabi MA, Ahmad R, Kumar KA, Critchley M (1995) Case report: renal scintigraphy in the diagnosis of urinary extravasation. Br J Radiol 68: 1251-1253.
10. Ghali AM, El Malik EM, Ibrahim AI, Ismail G, Rashid M (1999) Ureteric injuries: diagnosis, management, and outcome. J Trauma 46: 150-158.
11. Gray RJ, Intriore L, Dolmatch BL, Edson M, Fischer J (1992) Combined retrograde-antegrade ureteral stent passage: salvage procedure for a ureteral leak. J Vasc Interv Radiol 3: 557-558.