

Hydroa Vacciniforme-like Photosensitization after Scorpion Sting: A Case Report

J El Benaye^{1*} and M El Haouri¹

¹Department of dermatology, My Ismail Military Hospital, Meknès, Morocco

*Corresponding author: J El Benaye, Department of dermatology, My Ismail Military Hospital, Meknès, Morocco; Tel: +212 649 281 889; Email: jalalelbenaye@gmail.com

Received date: December 09, 2015; Accepted date: December 22, 2015; Published date: December 29, 2015

Copyright: © 2015 Benaye JE, et al. This is an open-access article distributed under the terms of the Creative Commons Attribution License, which permits unrestricted use, distribution, and reproduction in any medium, provided the original author and source are credited.

Abstract

Scorpion stings are a public health problem in many countries including Morocco. Cutaneous manifestations are rare, mainly local or loco-regional, exceptionally generalized. We report a case of photosensitization mimicking hydroa vacciniforme after scorpion sting, not yet described in the literature.

Keywords: Scorpion; Sting; Photosensitization; Hydroa vacciniforme

Introduction

Scorpion bites are a public health problem in the third world countries, especially in tropical and subtropical areas including Morocco. Each year, hundreds of bites are reported, responsible for various events ranging from asymptomatic bite to death, through cardiac or neurologic, systemic involvement [1].

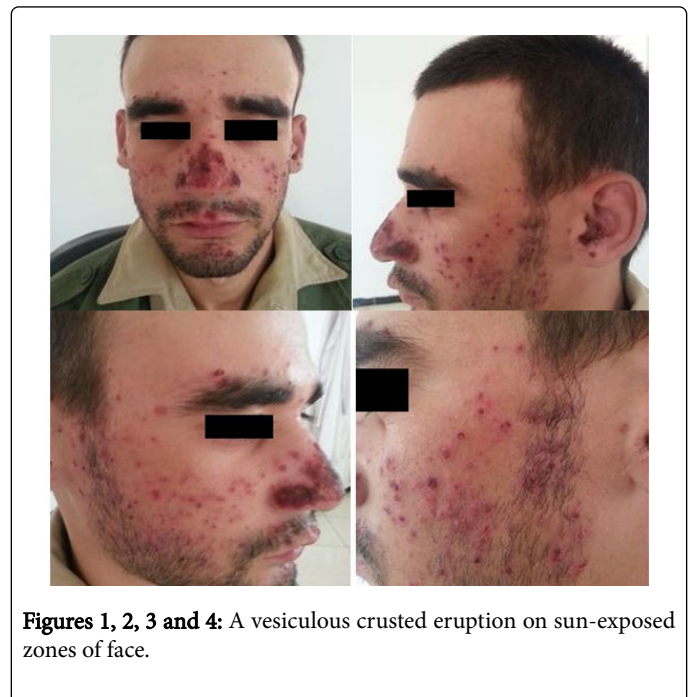
Photosensitization is a skin reaction due to the interaction between a photosensitizing substance in the skin and a determinate effective wavelength light radiation. This substance may be either endogenous (resulting from metabolic disorders) or exogenous (by contact or systemic introduction). Most often, it is drug-induced. In some cases, this substance is indeterminate. The photosensitization is then called idiopathic photodermatitis which hydroa vacciniforme (HV) [2].

We report a case of photosensitivity occurred after a scorpion sting whose the clinical presentation is mimicking HV.

Case Presentation

A 23 year old man, with no particular medical history; specially no facial herpes infection, no practice of a violent sport and no notion of photosensitivity; consulted in November for a non- febrile acute facial rash, more stinging than itchy. There was no drug intake or other administered substance (herbs and medicinal plants...), or topical application. However, patient reported that just 36 hours before the start of the eruption, he was stung by a scorpion in his left foot, for which he was received local care (antiseptic {Hexamidine}) with a simple monitoring; the scorpion's genre seems to be a *Buthus*, widespread scorpion's type in southern Morocco.

The dermatological examination find monomorphic erythematous umbilicated vesiculous-crusted lesions, bilateral and symmetric arranged, strictly localized on sun-exposed areas (nose, cheeks, ears, eyebrows and chin). The orbital region, nasolabial folds and under chin area (photo - protected areas) were intact.



Figures 1, 2, 3 and 4: A vesiculous crusted eruption on sun-exposed zones of face.

Furthermore, there are no local or regional signs on the site of the bite except a local pain. The rest of the physical examination and biological analysis are absolutely normal.

The diagnosis of an extended herpes or herpes gladiatorum was discussed but quickly dismissed because of medical history, clinical presentation with unreached mucous and negativity of Tzanck's cystodiagnosis and PCR in crusts. An acute eczema and Systemic Lupus were eliminated because clinical presentation and negativity of antinuclear and anti DNA antibodies.

The diagnosis of a photodermatitis seems to be the most likely despite no histological exam or photo test.

A Juvenile Spring eruption appeared to be unlikely because it was the first and only episode, occurring in winter. The clinical presentation was highly suggestive of HV, however, neither age nor

evolution were for; especially as Epstein Barr Virus (EBV) serology was negative.

Finally, photosensitivity to scorpion venom was retained, based on the eruption's characteristics, compatible chronology with scorpion sting and etiological negativity.

Management was first consisted of solar eviction with photoprotection. Crusts were eliminated by using a moisturizing cream 3 times daily, giving a complete remission without scars in a few days. No recurrence was observed for 2 years.

Discussion

Our case is very interesting and deserves to be discussed several sides.

In our knowledge, it's the first observation of a photodermatosis as cutaneous manifestation of scorpionism in particular and any envenomation in general; No case of photosensitization in scorpion venom has been reported to date. Moreover, no observations indicating photosensitization related envenomation has yet been described.

Cutaneous manifestations of scorpionism are poorly reported in the literature [3]. It is mainly a local or loco regional reaction such as erythematous macula, purpura, edema, bubble or an indurated plaque, sometimes progressing to necrosis [4]. Exceptionally, the reaction may be generalized and dangerous, sometimes involving life-threatening like anaphylactic shock, or giving evidence of an interaction between the organism and the venom such pallor, sweating.

On another side the described photodermatosis looks in clinical presentation like HV but it differs from it by the field and the evolution. Indeed, HV is a rare photodermatosis, affecting mostly children and spontaneously regressing to adolescence. Clinically, it is in the form of recurrent vesiculous-crusted papules, sitting on the photo-exposed areas on the face, becoming necrotic, and leaving varioliform scars [5]. In our case, it was the first episode, without any recurrences, occurring in a young man and completely resolved with no varioliform scars.

In the literature, a rash mimicking HV has been reported on several occasions [6] and is linked to a latent infection with EBV. It differs from a HV by the association with systemic signs and the evolution towards NK lymphoma. According to some authors, it would be part of

a continuous spectrum whose first event would hypersensitivity to mosquito bites [7,8].

Our patient had not presented any sensitivity to mosquito bites, had no systemic symptoms and EBV serology was negative [9].

Conclusion

This first case of photosensitization mimicking an HV secondary to scorpion sting merits to be reported discussed and should be confirmed by further observations especially in endemic by scorpions and sunny countries.

References

1. Khattabi A, Soulaymani-Bencheikh R, Achour S, Salmi LR (2011) Scorpion Consensus Expert Group. Classification of clinical consequences of scorpion stings: consensus development. *Trans R Soc Trop Med Hyg* 105: 364-369.
2. De Argila D, Aguilera J, Sánchez J, García-Díez A (2014) Study of idiopathic, exogenous photodermatoses. Part 1: pathophysiology and technical aspects of photobiologic studies. *Actas Dermosifiliogr* 105: 112-121.
3. Desoubeaux G, Bailly É, Andres CR, Guiguen C, Chandenier J (2015) Management of the cutaneous reaction induced by scorpion sting: thinking about treatment and means of prevention. *Presse Med* 44: 466-468.
4. Pipelzadeh MH, Jalali A, Taraz M, Pourabbas R, Zaremirakabadi A (2007) An epidemiological and a clinical study on scorpionism by the Iranian scorpion *Hemiscorpius lepturus*. *Toxicon* 50: 984-992.
5. Haddad JM, Monroe HR, Hardin J, Diwan AH, Hsu S (2014) Hydroa vacciniforme: a rare photodermatosis. *Dermatol Online J* 20.
6. Hijazi M, Malek J, Nabulsi M, Ghosn S (2015) Atypical hydroa vacciniforme mimicking dermatomyositis : A case report in a lebanese girl. *JAAD Case Rep* 1: 63-5.
7. Yamamoto T, Tsuji K, Suzuki D, Morizane S, Iwatsuki K (2007) A novel, noninvasive diagnostic probe for hydroa vacciniforme and related disorders: detection of latency-associated Epstein-Barr virus transcripts in the crusts. *J Microbiol Methods* 68: 403-407.
8. Yamamoto T, Tsuji K, Suzuki D, Morizane S, Iwatsuki K (2007) A novel, noninvasive diagnostic probe for hydroa vacciniforme and related disorders: detection of latency-associated Epstein-Barr virus transcripts in the crusts. *J Microbiol Methods* 68: 403-407.
9. Chiu TM, Lin YM, Wang SC, Tsai YG (2014) Hypersensitivity to mosquito bites as the primary clinical manifestation of an Epstein-Barr virus infection. *J Microbiol Immunol Infect* .