

## Evaluation of Duodenal Angioectasia with Portal Hypertension

Takahiro Sato\*, Sho Kitagawa and Mutsuimi Kimura

Department of Gastroenterology, Sapporo Kosei General Hospital, Sapporo, Japan

### Abstract

**Background:** A few studies have investigated duodenal lesions in patients with portal hypertension. Aim is to investigate duodenal angioectasia in patients with portal hypertension.

**Methods:** Sixty patients with duodenal angioectasia and portal hypertension were investigated between April 2009 and March 2012. The subjects were 29 males and 31 females ranging in age from 50 to 84 years (mean: 67.5). Endoscopic findings of duodenal angioectasia were investigated. We evaluated the therapeutic strategy for cases of bleeding duodenal angioectasia.

**Result:** The underlying pathologies of portal hypertension were liver cirrhosis in 56 patients, idiopathic portal hypertension in three patients and extrahepatic portal vein obstruction in one patient. Forty-one of the 60 patients had previously received endoscopic injection sclerotherapy for esophageal varices and the other nineteen patients had a coexistent high risk of esophageal varices. Gastric antral vascular ectasia was discerned in 29 cases. The location of the duodenal angioectasia was the duodenal bulb in 30 cases, descending portion in 13 cases and both the duodenal bulb and descending portion in 17 cases. Endoscopic findings of duodenal angioectasia were classified as follows: punctulate erythema (<1 mm), with or without oozing, and patchy erythema (a few mm), with or without oozing. Endoscopically, bleeding from the duodenal angioectasia was observed in 16 of 60 (26.7%) patients: punctulate erythema in 6 cases and patchy erythema in 10 cases. Bleeding from the patchy erythema type was discerned in 10 of 16 patients (62.5%). However, there was no bleeding in 43 cases of punctulate erythema involving the bulb. Argon plasma coagulation was successfully performed for 6 of 16 cases of bleeding duodenal angioectasia and the other 10 cases were followed-up with endoscopic observations.

**Conclusions:** Duodenal angioectasia in patients with portal hypertension is considered to be one of the lesions of portal hypertensive duodenopathy.

**Keywords:** Duodenal angioectasia; Portal hypertension; Portal hypertensive duodenopathy; Argon plasma coagulation

### Introduction

Portal hypertension can result in either the reopening of collapsed embryonic channels or reversal of the flow within existing adult veins [1]. Whilst esophagogastric varices are the most common complication in patients with portal hypertension, ectopic varices defined by large portosystemic venous collaterals occurring anywhere in the gastrointestinal tract, other than the esophagogastric region, are less common and account for between 1% and 5% of all variceal bleeding [2,3]. Ectopic varices that are not esophagogastric are located predominantly in the duodenum, jejunum, ileum, colon, rectum, and enterostomy stoma. Bleeding from ectopic varices, which is rare in patients with portal hypertension is generally massive and life threatening. In addition, other mucosal lesions such as portal hypertensive gastropathy (PHG) [4-6], Portal Hypertensive Duodenopathy (PHD), And Portal Hypertensive Colopathy (PHC) may develop and cause bleeding in patients with portal hypertension.

A few studies have investigated duodenal lesions in patients with portal hypertension. Data on the frequency of PHD and clinical significances are scarce. Gupta et al. reported that PHG and PHD are distinct clinical and endoscopic entities [7]. Duodenal erosion in patients with portal hypertension have been reported to be one of the lesions of PHD [8].

The aim of this study is to assess duodenal angioectasia on endoscopy and its clinical characteristics in patients with portal hypertension.

### Methods

This was a retrospective study of patients diagnosed with portal hypertension from 2009 to 2012 at the Sapporo Kosei Hospital. The

study was designed to evaluate the assessment of duodenal angioectasia on endoscopy and its clinical characteristics in patients with portal hypertension.

Between April 2009 and March 2012, 60 patients with portal hypertension were diagnosed with duodenal angioectasia by routine upper endoscopy at Sapporo Kosei General Hospital. These 60 consecutive patients were studied (29 males and 31 females, ranging in age from 50 to 84 years [mean: 67.5]).

Endoscopic findings of duodenal angioectasia were classified as, punctulate erythema (<1 mm), with or without oozing (type-1a) (Figure 1A), or patchy erythema (a few mm), with or without oozing (type-1b) (Figure 1B) [9]. We evaluated the location and the endoscopic classification of duodenal angioectasia, with or without bleeding. The past therapeutic histories of esophageal varices and endoscopic findings of PHG and Gastric Antral Vascular Ectasia (GAVE) were reviewed. We evaluated the therapeutic strategy for cases of bleeding duodenal angioectasia.

The study was performed according to the tenets of the Declaration

**\*Corresponding author:** Takahiro Sato, Department of Gastroenterology, Sapporo Kosei General Hospital, Japan, Tel: +81 11 261 5331; Fax: +81 11 261 6040; E-mail: [taka.sato@ja-hokkaidoukouseiren.or.jp](mailto:taka.sato@ja-hokkaidoukouseiren.or.jp)

**Received** October 30, 2013; **Accepted** December 03, 2013; **Published** December 11, 2013

**Citation:** Sato T, Kitagawa S, Kimura M (2013) Evaluation of Duodenal Angioectasia with Portal Hypertension. J Liver 2: 140. doi:10.4172/2167-0889.1000140

**Copyright:** © 2013 Sato T. This is an open-access article distributed under the terms of the Creative Commons Attribution License, which permits unrestricted use, distribution, and reproduction in any medium, provided the original author and source are credited.

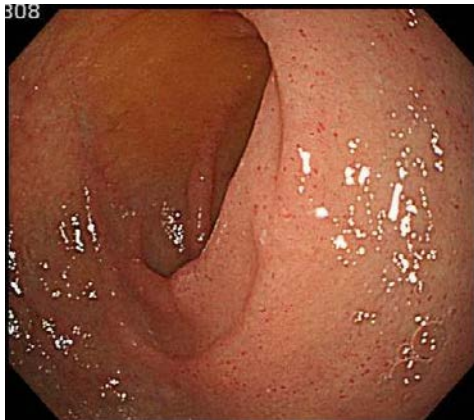


Figure 1A: Type 1a-punctulate erythema (<1 mm), with or without oozing.

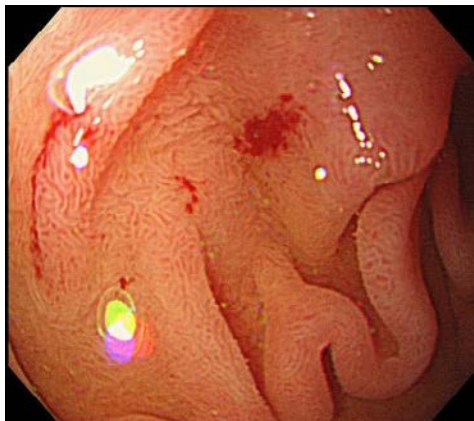


Figure 1B: Type 1b-patchy erythema (a few mm), with or without oozing.

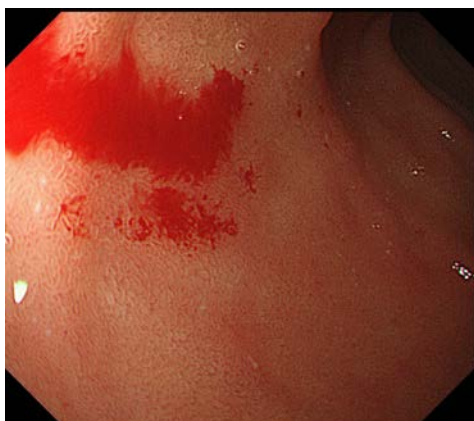

Figure 1C: Bleeding Type 1b duodenal angioectasia.

of Helsinki. Written informed consent was obtained from all patients prior to the procedures. The study was approved by the ethical committee of Sapporo Kosei Hospital.

## Results

The underlying pathologies of portal hypertension were liver cirrhosis in 56 patients, idiopathic portal hypertension in 3 patients and

extrahepatic portal vein obstruction in 1 patient. The liver functions of 56 cirrhotic patients, according to Child-Pugh classification, were: 25 class A, 22 class B and 9 class C. Forty-one of the 60 (68.3%) patients had previously received endoscopic injection sclerotherapy (EIS) for esophageal varices and the other nineteen patients had a coexistent high risk of esophageal varices. EIS had been performed on 11 of the 41 patients during the past year and no case of duodenal angioectasia was found. On the other hand, PHG was discerned in 25 of 60 (41.7%) patients. GAVE was discerned in 29 of 58 (50.0%) cases (except two post resection of the stomach) (Table 1).

The location of the duodenal angioectasia was the duodenal bulb in 30 cases, descending portion in 13 cases and both the duodenal bulb and descending portion in 17 cases. Duodenal angioectasia was discerned in the duodenal bulbs of 47 of the 60 (78.3%) patients. We evaluated the endoscopic findings of duodenal angioectasia and the locations were classified as follows: type-1a of the duodenal bulb in 26 cases, type-1b of the duodenal bulb in 4 cases, type-1a of the descending portion in 3 cases, type-1b of the descending portion in 10 cases, type-1a of the duodenal bulb and descending portion in 15 cases, and a combined type of type-1a of the duodenal bulb and type-1b of the descending portion in 2 cases.

Endoscopically, bleeding from the duodenal angioectasia was observed in 16 of the 60 (26.7%) patients, 3 of 30 in the duodenal bulb, 8 of 13 in the descending portion and 5 of 17 in the duodenal bulb and descending portion. In the 5 patients with involvement of the duodenal bulb and descending portion, bleeding was observed in the descending portion. Endoscopic classification of duodenal angioectasia and its bleeding rates was showed in Table 2. Bleeding was most common from the descending portion and in type 1b angioectasia. Next, we evaluated the relationship between the types of angioectasia and endoscopic findings. The bleeding frequency was as follows: in 0/43 (0%) of type-1a from the duodenal bulb, in 3/4 (75.0%) of type-1b from the duodenal bulb, in 6/18 (33.3%) of type-1a from the descending portion and in 7/12 (58.3%) of type-1b from the descending portion. There was no bleeding among 43 type-1a cases involving the bulb.

Endoscopic treatment was performed for 6 of 16 bleeding duodenal angioectasia (Figure 1C), and the other 10 cases were followed-up with endoscopic observations because of the amount of bleeding was small. Argon plasma coagulation (APC) in 5 of 6 cases, and APC plus endoscopic clipping in the remaining case, was performed successfully for these 6 bleeding patients.

## Discussion

PHD was first reported as congestive gastroenterology by

Gender (male/female)	29/31
Age	67.5 ± 9.1
Cause of portal hypertension (LC/IPH/EHO)	56/3/1
Child-Pugh (A/B/C)	25/22/9
Therapeutic history of EV	41/60 (68.3%)
Therapeutic history of EV within one year	11/60 (18.3%)
PHG	25/60 (41.7%)
GAVE*	29/58 (50.0%)

LC: Liver Cirrhosis; IPH: Idiopathic Portal Hypertension; EHO: Extrahepatic Portal Obstruction; EV: Esophageal Varices; PHG: Portal Hypertensive Gastropathy; GAVE: Gastric Antral Vascular Ectasia  
\*: except gastrectomy

Table 1: Clinical characteristic features of duodenal angioectasia.

	Duodenal bulb	Descending portion	Total
Type 1a	0/43(0%)	6/18(33.3%)	6/61(9.8%)
Type 1b	3/4(75.0%)	7/12(58.3%)	10/16(62.5%)
Total	3/47(6.4%)	13/30(43.3%)	16/77(20.8%)

Type 1a: punctulate erythema (< 1mm), with or without oozing

Type 1b: patchy erythema (a few mm), with or without oozing

**Table 2:** Endoscopic classification of duodenal angioectasia and its bleeding rates.

Thiruvengadam et al. [10] and its frequency varies, ranging from 8.4% to 51.7% of portal hypertensive patients [7,8,11,12]. Menchen et al. diagnosed PHD as a congestive vascular pattern of the duodenum and reported that it was found in 8.4% [13]. On the other hand, Barakat et al. found PHD in 51.4% of portal hypertensive patients, including erythema, erosions, ulcers, telangiectasia, exaggerated villous pattern, duodenal varices, and mixed lesions [14]. The hepatic reserve function was assessed by the Child-Pugh classification. In this study, there was no relationship between the grade with Child's grade A, B or C and duodenal angioectasia, similar to previous reports [7,11,13].

Findings of PHD have been observed more frequently in patients after EIS for esophageal varices [8,13] but several articles reported no direct association between EIS and an increased prevalence of PHD [7,12]. In this study, 41 of our 60 (68.3%) patients had previously received EIS for esophageal varices and the other nineteen patients had co existent high risk esophageal varices. Duodenal angioectasia was diagnosed in 11 of 41 patients within one year of EIS and we suspect a relationship between EIS and the progression of duodenal angioectasia. This may imply that EIS cause artificial occlusion of the esophageal varices, leading to elevation of the portal pressure. El-Khayat et al. also has reported the worsening of PHG and PHE (including PHD) with endoscopic findings and pathological analysis after endoscopic variceal ligation of esophageal varices [15].

Several reports on the clinical features of patients with PHG have indicated that: 1) PHG was more frequently observed among patients with esophagogastric varices [16]. 2) the incidence of PHG increased with the portal pressure [17] and 3) the grade of PHG advanced after EIS for esophageal varices [18]. These findings indicate a relationship between elevation of portal pressure and PHG. PHG was discerned in 25 of 60 (41.7%) patients in our study and this finding indicates the advanced portal hypertension in many cases of this study.

The etiology of GAVE remains unknown, and it is thought to encompass a variety of conditions. The majority of GAVE patients have underlying cirrhosis and portal hypertension. Ikeda et al. reported that the development of GAVE associated with cirrhosis was dependent on the temporal progression of the disease [19]. On the other hand, Spahr et al. [20] reported that GAVE is not directly related to portal hypertension. Duodenal angioectasia and GAVE have a similar endoscopic appearance but the pathogenesis differs. In this study, GAVE was discerned in 50.0% of cases, however, of the 11 patients in whom duodenal angioectasia was not present before EIS, only two patients (20.0%) developed GAVE within one year of EIS. These findings may indicate no relationship between an elevation of portal pressure and GAVE.

Barakat et al. reported that PHD was documented as the cause of overt or occult bleeding in 9.5% of patients, and endoscopically, 10 (18.5%) of 54 patients had blood clots overlying the PHD and the episodes of overt bleeding were not severe. In this study, bleeding from the duodenal angioectasia was observed endoscopically in 16 of 60 (26.7%) patients. Bleeding was seen in 3 of 47 (6.4%) from the duodenal bulb and in 13 of 30 (43.3%) from the descending portion, and in 6 of

61 (9.8%) of type-1a and in 10 of 16 (62.5%) of type-1b. Bleeding was most common in the descending portion and in type 1b angioectasia. The bleeding was overt in 6 of 16 patients (37.5%), manifested as anemia and/or melena, and APC was successfully performed for these 6 patients. APC is a modality of non-contact electro coagulation that applies high frequency electronic energy into tissue to cause defined thermal effects, which can be used for thermal devitalization of the tissue as well as hemostasis [21]. The argon plasma seeks precisely the tissue surface with the lowest electrical impedance. Therefore, the tissue is coagulated to an even depth across the entire surface, and the danger of perforation is lower than with conventional coagulation procedures or YAG laser [22]. YAG laser has become the effective therapy for GAVE [23]. However, it has several disadvantages over APC. It has a higher set-up cost, and it is more bulky and more dangerous to perforate than APC. The depth of mucosal injury is limited with APC [22,24]. APC has been performed successfully to treat GAVE, and results in good temporary control of GAVE-associated hemorrhage [24-27]. In this study, APC was a safe and effective treatment for bleeding duodenal angioectasia.

The other 10 cases were followed-up with endoscopic observations because of small amount of bleeding and this is appropriate for cases in which anemia is not worsening. Piccinni et al. diagnosed an atypical endoscopic picture of PHD and described an approach using APC [28].

On endoscopic examination, PHD shows various types, including redness, erosion, ulcers and telangiectasia, in the duodenal mucosa. In conclusion, duodenal angioectasia in patients with portal hypertension is considered to be one type of PHD, and its frequency increases with presence of esophageal varices and after EIS. Duodenal angioectasia can cause occult bleeding in some cases and APC is a useful treatment for its bleeding. However, the sample size in this report is small and more investigations are necessary in larger numbers of patients by a long-term analysis.

#### Acknowledgement

We thank Dr Katsu Yamazaki for advice. Author contributions: Takahiro Sato wrote the paper. Sho Kitagawa analyzed data. Mutsuimi Kimura designed research.

#### References

- Walsh G, Williams MP (1995) Case report: Giant pararectal varices-computed tomographic appearances. *Br J Radiol* 68: 203-204.
- Kinkhabwala M, Mousavi A, Iyer S, Adamsons R (1977) Bleeding ileal varicosity demonstrated by transhepatic portography. *Am J Roentgenol* 129: 514-516.
- Norton ID, Andrews JC, Kamath PS (1988) Management of ectopic varices. *Hepatology* 28: 1154-1158.
- McCormack TT, Sims J, Eyre-Brook I, Kennedy H, Goepel J, et al. (1985) Gastric lesions in portal hypertension: Inflammatory gastritis or congestive gastropathy? *Gut* 26: 1226-1232.
- Maruyama T (1995) Study of gastric mucosal lesion in portal hypertension. *Jpn J Gastroenterol* 92: 1121-1132.
- Sarin SK, Sreenivas DV, Lahoti D, Saraya A (1992) Factors influencing development of portal hypertensive gastropathy in patients with portal hypertension. *Gastroenterology* 102: 994-999.
- Gupta R, Saraswat VA, Kumar M, Naik SR, Pandey R (1996) Frequency and factors influencing portal hypertensive gastropathy and duodenopathy in cirrhotic portal hypertension. *J Gastroenterol Hepatol* 11: 728-733.
- Shudo R, Yazaki Y, Sakurai S, Uenishi H, Yamada H, et al. (2002) Duodenal erosions, a common and distinctive feature of portal hypertensive duodenopathy. *Am J Gastroenterol* 97: 867-873.
- Yano T, Yamamoto H, Sunada K, Miyata T, Iwamoto M, et al. (2008) Endoscopic classification of vascular lesions of the small intestine (with videos). *Gastrointest Endosc* 67: 169-172.

10. Thiruvengadam R, Gostout CJ (1989) Congestive gastroenteropathy-an extension of nonvariceal upper gastrointestinal bleeding in portal hypertension. *Gastrointest Endosc* 35: 504-507.
11. Vigneri S, Termini R, Piraino A, Scialabba A, Bovero E, et al. (1991) The duodenum in liver cirrhosis: endoscopic, morphological and clinical findings. *Endoscopy* 23: 210-212.
12. Nagral AS, Joshi AS, Bhatia SJ, Abraham P, Mistry FP, et al. (1993) Congestive jejunoathy in portal hypertension. *Gut* 34: 694-697.
13. Menchén L, Ripoll C, Marín-Jiménez I, Colón A, Gómez-Camarero J, et al. (2006) Prevalence of portal hypertensive duodenopathy in cirrhosis: clinical and haemodynamic features. *Eur J Gastroenterol Hepatol* 18: 649-653.
14. Barakat M, Mostafa M, Mahran Z, Soliman AG (2007) Portal hypertensive duodenopathy: clinical, endoscopic, and histopathologic profiles. *Am J Gastroenterol* 102: 2793-2802.
15. El-Khayat HR, El Khattib A, Nosseir M, Ezz MA, El-Amin H, et al. (2010) Portal hypertensive enteropathy before and after variceal obliteration: an endoscopic, histopathologic and immunohistochemical study. *J Gastrointest Liver Dis* 19: 175-179.
16. D'Amico G, Montalbano L, Traina M, Pisa R, Menozzi M, et al. (1990) Natural history of congestive gastropathy in cirrhosis. *Gastroenterology* 99: 1558-1564.
17. Iwao T, Toyonaga A, Sumino M, Takagi K, Oho K, et al. (1992) Portal hypertensive gastropathy in patients with cirrhosis. *Gastroenterology* 102: 2060-2065.
18. Boldys H, Romanczyk T, Hartleb M, Nowak A (1996) Short-term effects of variceal sclerotherapy on portal hypertensive gastropathy. *Endoscopy* 28: 735-739.
19. Ikeda M, Ishida H, Nakamura E, Shirai Y, Michida T, et al. (1996) An endoscopic follow-up study of the development of diffuse antral vascular ectasia. *Endoscopy* 28: 390-393.
20. Spahr L, Villeneuve JP, Dufresne MP, Tasse D, Bui B, et al. (1999) Gastric antral vascular ectasia in cirrhotic patients: absence of relation with portal hypertension. *Gut* 44: 739-742.
21. Grund KE, Storek D, Farin G (1994) Endoscopic argon plasma coagulation (APC): First clinical experiences in flexible endoscopy. *Endosc. Surg.* 2: 42-46.
22. Wahab PJ, Mulder CJ, den Hartog G, Thies JE (1997) Argon plasma coagulation in flexible gastrointestinal endoscopy. Pilot experiences. *Endoscopy* 29: 176-181.
23. Potamiano S, Carter CR, Anerson JR (1994) Endoscopic laser treatment of diffuse gastric antral vascular ectasia. *Gut* 35:461-463.
24. Yusoff I, Brennan F, Ormonde D, Laurence B (2002) Argon plasma coagulation for treatment of watermelon stomach. *Endoscopy* 34, 407-410.
25. Roman S, Saurin JC, Dumortier J, Perreira A, Bernard G, et al. (2003) Tolerance and efficacy of argon plasma coagulation for controlling bleeding in patients with typical and atypical manifestations of watermelon stomach. *Endoscopy* 35: 1024-1028.
26. Sato T, Yamazaki K, Akaike J (2012) Endoscopic band ligation versus argon plasma coagulation for gastric antral vascular ectasia associated with liver diseases. *Dig. Endosc* 24: 237-242.
27. Fuccio L, Zagari RM, Serrani M, Eusebi LH, Grilli D, et al. (2009) Endoscopic argon plasma coagulation for the treatment of gastric antral vascular ectasia-related bleeding in patients with liver cirrhosis. *Digestion* 79: 143-150.
28. Piccinni G, Angrisano A, Marzullo A, Nacchiero M (2006) Diagnosing and treating bleeding portal hypertensive duodenopathy. *JLAST* 16: 294-296.