

Efficacy of Platelet-Rich Plasma in Reduction of the Resorption of the Alveolar Cleft Bone Graft. A Comparative Study

Ayman F Hegab^{1*} and Mohmmad A Shuman²

¹Al-Azhar University, Cairo, Egypt
²Al-Azhar University, Assiut, Egypt

Abstract

Aims and objectives: The reconstruction of the alveolar cleft is usually achieved through an autologous bone graft and associated with unpredictable results. We sought to analyse the efficacy of platelet-rich plasma in reduction of the resorption of the alveolar cleft bone graft.

Patients and methods: 20 nonsyndromic patients with unilateral alveolar clefts treated with alveolar bone grafting during the period between June 2005 and December 2008 were included in this study. The patients were randomly assigned to two groups: In Group 1: the patients treated by autogenous bone graft with Platelet-Rich Plasma. In Group 2: the patient treated by autogenous bone graft only. Clinical and radiological follow-up examinations were carried out at 1, 6 and 12 months. The osseous resorption method was evaluated with the use of digital panoramic radiograph.

Results: After 1 month, all cases in the two groups showed Grade I bone resorption. After 6 and 12 months, Group 1 showed higher prevalence of Grade I but with no statistically significant difference compared to Group 2. Of the 10 patients in Group 2, three patients with Grade III bone resorption underwent subsequent alveolar bone graft from intraoral sites (mandibular symphysis, lateral cortex of the mandibular ramus or combination of the previous sites), while one case with Grade IV bone resorption (failed bone graft) was treated by intraoral distraction osteogenesis.

Conclusion: Based on the results presented in this study, it is possible to conclude that a more favourable result can be achieved with application of PRP to the alveolar bone graft.

Keywords: Alveolar cleft; Autologous iliac bone graft; Platelet-rich plasma

Introduction

Secondary bone grafting in the cleft area was first reported by Boyne and Sands in the 1970s [1,2]. This procedure is an essential step in the overall management of patients with cleft lip and palate (CLP), and has been accepted as a means of stabilizing the segments of the maxilla, achieving continuity of the dental arch, guiding permanent teeth towards the cleft area, obliterating oronasal fistulae, and enhancing nasal base and facial appearance. Fresh autogenous cancellous bone is ideal for secondary bone grafting due to the supply of living bone cells that integrate fully with the maxilla and are essential for osteogenesis [3-5].

Autologous iliac bone graft is used preferably because of its sufficient quantity and high osteoinductive potential. However, even with iliac bone, insufficient osteo regeneration may occur due to several factors such as the patient's age, cleft width, influence of functional stress, or as a result of bone resorption and others. Different methods for accelerating the speed of bone formation and reducing bone resorption in alveolar cleft bone grafting has been sought for sometime [1,6,7].

In 1998, Platelet-Rich Plasma (PRP) was reported by Marx et al. [8] to promote new bone formation in mandibular continuity defects and to cause faster maturation of autologous bone grafts. Platelet-rich plasma (PRP) extracted from autogenous blood which contains many growth factors, such as platelet-derived growth factor (PDGF), Vascular Endothelial Growth Factor (VEGF) and Transforming Growth Factor beta (TGF- β). PRP can accelerate bone regeneration and enhance bone formation by accompanying autogenous bone graft or bone substitutes. In oral and maxillofacial surgery, PRP effectively influences wound healing, implant placement, and reconstructive surgery of maxillofacial defects. PRP is considered to accelerate bone regeneration, and consequently, it provides a mature and thick bone

bridge following secondary bone graft in the alveolar cleft. Many reports [8-15] have confirmed the effectiveness of PRP in enhancing bone regeneration when added to autologous bone grafts and other bone substitutes, while others have shown no benefit of PRP on bone formation [16-26].

The purpose of the present study was to evaluate the effectiveness of PRP in reduction of the resorption of the secondary autogenous alveolar cleft bone graft.

Patients and Methods

20 nonsyndromic patients with unilateral alveolar clefts treated with alveolar bone grafting during the period between June 2005 and December 2008 were included in this study. All procedures and materials were approved by the local Ethics Committee. Informed consent was obtained from all patients. The patients were randomly assigned to two groups: In Group 1: the patients treated by autogenous bone graft with Platelet-Rich Plasma. In Group 2; the patient treated by autogenous bone graft only.

Preparation of PRP

PRP was extracted during the operation. After anesthesia induction,

***Corresponding author:** Ayman F Hegab, PhD, Faculty of Dental Medicine, Al-Azhar University, Cairo, Egypt, Tel: 0097433310124; 0097477744125; 00201001981112; E-mail: hegab@mail.com

Received September 23, 2012; **Accepted** October 23, 2012; **Published** October 25, 2012

Citation: Hegab AF, Shuman MA (2012) Efficacy of Platelet-Rich Plasma in Reduction of the Resorption of the Alveolar Cleft Bone Graft. A Comparative Study. Dentistry 2:150. doi:10.4172/2161-1122.1000150

Copyright: © 2012 Hegab AF, et al. This is an open-access article distributed under the terms of the Creative Commons Attribution License, which permits unrestricted use, distribution, and reproduction in any medium, provided the original author and source are credited.

50 ml of venous blood was drawn and put into 14 to 16 sterile test tubes (Vacutainer System: Green Vac-Tube™, Green Cross MS) containing sodium citrate as anticoagulant in a quantity equal to 10% of the final volume. The sterile test tubes were centrifuged at 4000 rpm for 15 minutes to separate the platelet poor plasma from red blood cell and puffy coat. After the first centrifugation, the blood was separated into plasma and red blood cells. The red blood cells were removed, and after a further centrifugation of the remaining plasma, the bottom layer, which was rich in platelets and constituted approximately 10% of the total withdrawn blood volume, was collected for use as PRP. To form a gel, a mixture was added to the PRP of equal volume of a sterile saline solution of 10% calcium chloride and then mixed with the patient's serum as a source of autologous thrombin to become activated. The coagulated PRP preparation was achieved in a sticky gel consistency and easy handling.

Surgical procedure

Alveolar bone grafting was performed under general endotracheal anaesthesia. Incisions were made and gingival mucoperiosteal flaps were elevated in the standard fashion for alveolar bone grafting. Autogenous cancellous bone and marrow was harvested from the anterior iliac crest (Figure 1). In group 1, the harvested cancellous iliac bone and PRP were mixed and placed into an injection syringe and packed into the alveolar cleft and the cleft was closed with gingival mucoperiosteal flaps (Figures 2-4). While in group 2, the harvested cancellous iliac bone was packed alone without PRP into the alveolar cleft and the cleft was closed with gingival mucoperiosteal flaps (Figures 5 and 6)

Clinical and radiological evaluation

Clinical and radiological follow-up examinations were carried out at 1, 6, and 12 months. The osseous resorption was evaluated using the method described by Abyholm et al. [27] with the use of digital panoramic radiograph. Here, the extent of the vertical bone height was determined in relation to the interdental bone height and assessed on a 4-point scale: Grade I: 0% to 25% bone loss, Grade II: 25% to 50%

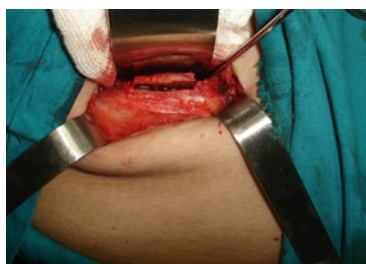


Figure 1: Harvested the cancellous bone and marrow from the anterior iliac crest.

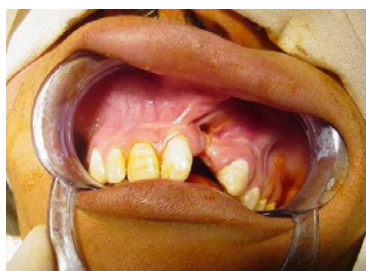

Figure 2: Preoperative intraoral view of the alveolar cleft in group 2.

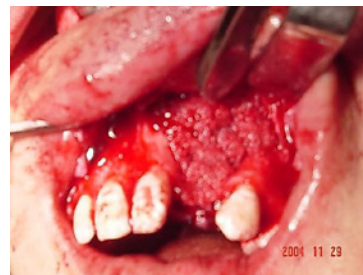


Figure 3: Autogenous cancellous bone and marrow from the anterior iliac crest was used for grafting.

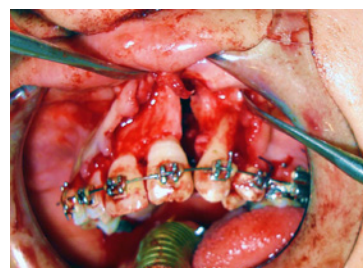


Figure 4: Exposure of the cleft by standard mucoperiosteal flap in group 1.

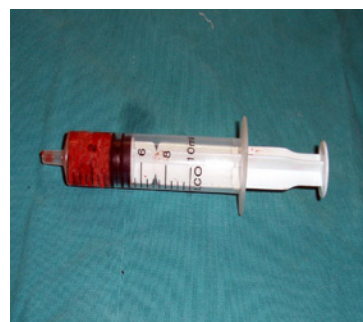

Figure 5: Cancellous iliac bone was harvested, and PRP was mixed with it placed into an injection syringe.

bone loss, Grade III: 50% to 75% bone loss, and Grade IV: 75% to 100% bone loss (Figure 7). Radiographic evaluation repeated at 1, 6 and 12 months postoperatively.

Statistical analysis

Numerical data were presented as mean and Standard Deviation (SD) values. Student's t-test was used to compare between mean ages values in the two groups. Qualitative data were presented as frequencies and percentages. Chi-square (χ^2) test was used to compare between the two groups. The significance level was set at $P \leq 0.05$. Statistical analysis was performed with IBM® SPSS® Statistics Version 20 for Windows.

Results

20 nonsyndromic patients with unilateral alveolar clefts 5 male (25%) and 15 female (75%) with age range from 16 to 27 years (mean age 21.9 years) were enrolled in the study (Table 1).

Wound healing was uneventful in the postoperative period: neither wound dehiscence nor sequestration occurred. All patients had an uneventful course postoperatively. The total resorption rate of the bone

bridge in both groups gradually increased throughout the 12 month period. After 1 month, all cases in the two groups showed Grade I resorption (Figures 8A and 8B). After 6 and 12 months, Group 1 showed higher prevalence of Grade I but with no statistically significant difference compared to Group 2 (Table 2).

There were 3 cases with Grade II resorption representing 30% of the sample in Group 2 but without statistically significant difference compared to Group 1 which shows no cases with Grade II resorption. After 12 months, Group 1 showed higher prevalence of Grade I resorption but without statistically significant difference compared to Group 2. There were 2 cases (20% of the sample) shows Grade II bone resorption in Group 2 opposing 1 case (10% of the sample) in Group 1 but without statistically significant difference between both groups.

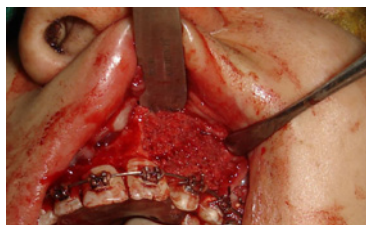


Figure 6: Cancellous iliac bone was harvested, and PRP packed into the alveolar cleft in group 1.

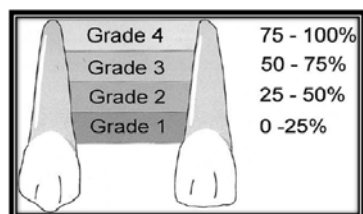


Figure 7: 4-point scale for evaluation of alveolar bone resorption described by Abyholm et al.

Group Variables	Group 1 (PRP)	Group 2 (Control)	P-value
Age (Years) Mean ± SD	21.8 ± 3.6	21.9 ± 3	0.947
Gender (n, %)			
Male	2 (20)	3 (30)	0.606
Female	8 (80)	7 (70)	

Table 1: Mean, standard deviation (SD) of age and sex distribution between the two groups.

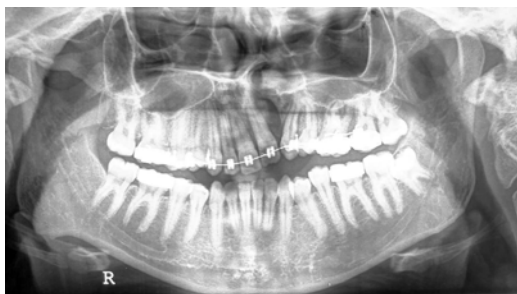

Figure 8a: Preoperative panoramic X-ray of alveolar cleft patient in group 1.

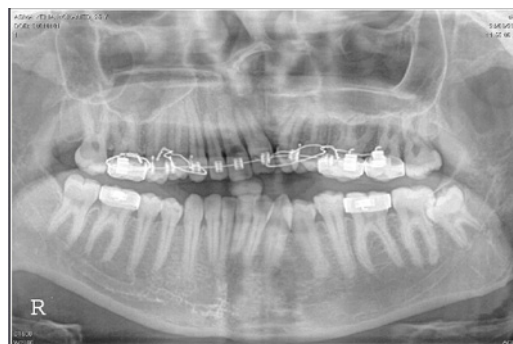

Figure 8b: Panoramic X-ray of alveolar cleft patient in group 1 one year postoperatively showed grade I bone resorption.

Bone resorption level (n, %)	Group		P-value	
	Group 1 (PRP)	Group 2 (Control)		
1 month	Grade I	10 (100)	10 (100)	NC**
	Grade II	0 (0)	0 (0)	
	Grade III	0 (0)	0 (0)	
	Grade IV	0 (0)	0 (0)	
6 months	Grade I	10 (100)	7 (70)	0.060
	Grade II	0 (0)	3 (30)	
	Grade III	0 (0)	0 (0)	
	Grade IV	0 (0)	0 (0)	
12 months	Grade I	9 (90)	6 (60)	0.402
	Grade II	1 (10)	2 (20)	
	Grade III	0 (0)	1 (10)	
	Grade IV	0 (0)	1 (10)	

Significant at $P \leq 0.05$, NC**: Not computed because the variable is constant

Table 2: Difference of bone resorption between both study groups during follow-up period.

There was one case with Grade III bone resorption (10% of the sample) and one case (10% of the sample) with Grade IV bone resorption in Group 2 but without any statistically significant difference compared to the Group 1 which showed no cases with Grade III or IV bone resorption.

All the patients in Group 1 (PRP) and 6 patients in Group 2 obtained retention of the alveolar arch and stabilization of the teeth adjacent to the cleft. All oronasal fistulas were closed. Prosthodontic treatments, such as dental implants, bridges, or partial dentures, are scheduled subsequently.

Of the 10 patients in Group 2, three patients with Grade III underwent subsequent alveolar bone graft from intraoral sites (mandibular symphysis, lateral cortex of the mandibular ramus or combination of the previous sites), while one case with Grade IV (Figures 9A and 9B) bone resorption (failed bone graft) was treated by intraoral distraction osteogenesis. The degree of the resorption rate of

the bone bridge in both the PRP and the non-PRP groups are shown in figure 10. Bone formation was satisfactory in the others patients as no other complications were observed.

Discussion

Alveolar bone grafting is a significant treatment for cleft lip and palate. It may not only induce the tooth eruption but also stabilize the alveolar arch of maxilla. The reconstruction of the alveolar process in patients with cleft lip and palate is well established. Although autogenous bone, mostly from the hip, is used as standard graft material, results of osteoplasty are unpredictable. The current study attempted to determine whether PRP is useful for preventing postoperative resorption of grafted bone in the alveolar cleft. Various evaluation methods for the postoperative course of grafted bone have been reported: dental X-rays, occlusal X-rays, panoramic X-rays and Computed Tomography (CT). In the current study we used the digital panoramic X-rays for measurement of alveolar bone loss.

Iliac cancellous bone is a preferable grafting material because it can be harvested easily and sufficiently and has high osteoinductive potential compared with the other materials. However, even with iliac bone marrow, partial absorption and shortage of reconstructed alveolar height or width may develop postoperatively. The effects of PRP on bone graft are a controversial issue. It has been reported that PRP influences bone regeneration in bone grafting [8,28]. Marx et al. have demonstrated that the maturity of grafted bone combined with PRP is significantly greater than that without PRP, and that grafted bone combined with PRP shows a mature Harversian system and a greater proportion of lamellar phase bone [8].

Different opinions have been expressed by other authors. Klongnoi et al. [22] have reported that PRP application does not have significant benefits on sinus augmentation by autogenous bone graft. The clinical

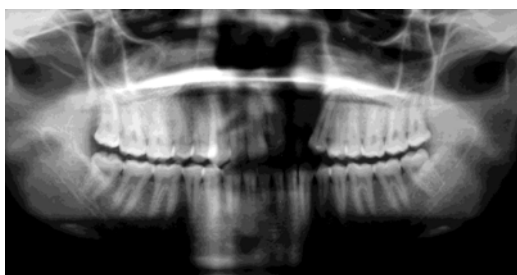


Figure 9a: Preoperative panoramic X-ray of alveolar cleft patient in group 2.

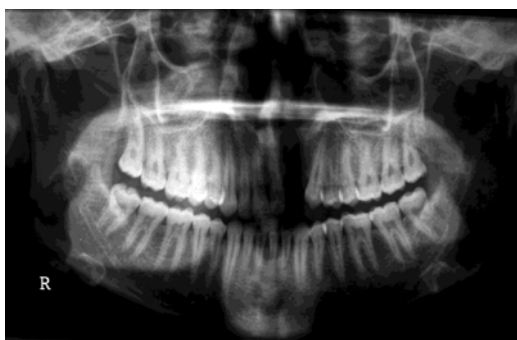

Figure 9b: Panoramic X-ray of alveolar cleft patient in group 2, one year postoperatively showed grade IV bone resorption.

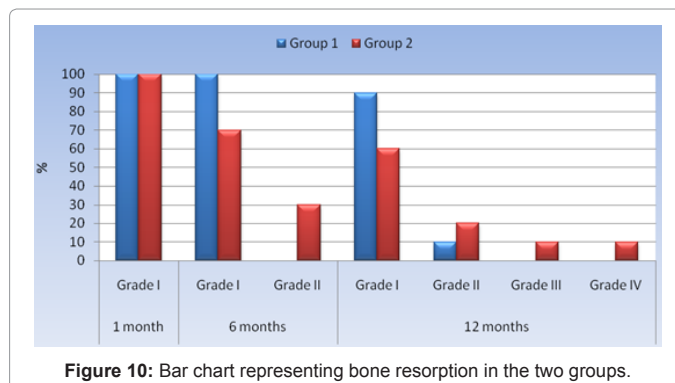


Figure 10: Bar chart representing bone resorption in the two groups.

effects of PRP have not been elucidated, and few well-controlled studies have addressed the effects of PRP on autogenous bone graft in the alveolar cleft. The present study suggests that PRP may decrease the level of bone resorption, and are insufficient to totally prevent postoperative bone resorption following secondary bone graft in the alveolar cleft.

In this study, the effects of PRP on bone resorption were assessed. Regarding the resorption rate of grafted bone, there was no statistically significant difference between the PRP and non-PRP groups throughout the study, but the resorption rate in Group 2 patients tended to be higher than that in patients of Group 1 at 6 and 12 months postoperatively. In the wide cleft, the low volume of grafted bone is susceptible to failure if filled into the alveolar cleft.

In the current study; failure of bone graft (Grade IV) occurred in one patient in Group 2 (without PRP) and Grade III occurred in another one patient which support the influence of PRP in decreased the level of alveolar bone resorption. Even there was no statistically significant difference due to small sample size but there was clinically significant difference between the two groups with higher prevalence of bone resorption in Group 2.

Various prognostic factors for postoperative bone resorption in secondary autogenous bone grafting have been identified [29-31]. Many authors have indicated that age at operation, width of the alveolar cleft, volume of grafted bone, and position of canine teeth, are the major factors that affect bone resorption of the bone bridge. Several authors have emphasized that continuous mechanical stress by the adjacent teeth is the most important factor that influences bone resorption of grafted bone [23,31].

The role of Platelet Rich Plasma (PRP) is subject to much debate. We supposed that PRP might enhance the osteogenesis of autologous bone and lessen post operative bone resorption. Patients in Group 1, grafted with PRP, acquired a markedly low rate of bone resorption in comparison with Group 2.

It appears that the resorption of regenerated bone that occurs postoperatively may be reduced significantly by using PRP. We believe that the fibrin networks of PRP might aid the decrease in postoperative bone resorption. The function of fibrin networks is as an osteoconductive scaffold [32-37], and thus the fibrin gel would have provided a matrix for cell growth and differentiation by enhancing three-dimensional intercellular interactions or cell adhesion, both of which are thought to be good environments for the maturation of osteoblasts [35,37].

Another possible reason why PRP reduces bone resorption is

that PRP accelerates wound healing in soft tissue. The PRP gel not only provides haemostatic adhesion properties but also supplies the wound with valuable growth factors that enhance and promote the healing process. The growth factors in the graft sites may also increase immunomodulatory activity, which enhances the wound healing process. This acceleration of wound healing by PRP may result in a reduction in bone resorption [38-41].

Conclusion

Based on the results presented in this study, it is possible to conclude that a more favourable result can be achieved with application of PRP to the alveolar bone graft. PRP may preserve the height of the graft better than control, making autogenous cancellous bone grafting with PRP more useful for treatment alveolar cleft patients.

References

1. Boyne PJ, Sands NR (1972) Secondary bone grafting of residual alveolar and palatal clefts. *J Oral Surg* 30: 87-92.
2. Boyne PJ, Sands NR (1976) Combined orthodontic-surgical management of residual palato-alveolar cleft defects. *Am J Orthod* 70: 20-37.
3. Amanat N, Langdon JD (1991) Secondary alveolar bone grafting in clefts of the lip and palate. *J Craniomaxillofac Surg* 19: 7-14.
4. Cohen M, Polley JW, Figueroa AA (1993) Secondary (intermediate) alveolar bone grafting. *Clin Plast Surg* 20: 691-705.
5. Dempf R, Teltzow T, Kramer FJ, Hausamen JE (2002) Alveolar bone grafting in patients with complete clefts: a comparative study between secondary and tertiary bone grafting. *Cleft Palate Craniofac J* 39: 18-25.
6. Long RE Jr, Spangler BE, Yow M (1995) Cleft width and secondary alveolar bone graft success. *Cleft Palate Craniofac J* 32: 420-427.
7. Opitz C, Meier B, Stoll C, Subklew D (1999) Radiographic evaluation of the transplant bone height in patients with clefts of the lip/alveolus/palate after secondary bone grafting. *J Orofac Orthop* 60: 383-391.
8. Marx RE, Carlson ER, Eichstaedt RM, Schimmele SR, Strauss JE, et al. (1998) Platelet-rich plasma: Growth factor enhancement for bone grafts. *Oral Surg Oral Med Oral Pathol Oral Radiol Endod* 85: 638-646.
9. Aghaloo TL, Moy PK, Freymiller EG (2002) Investigation of platelet-rich plasma in rabbit cranial defects: a pilot study. *J Oral Maxillofac Surg* 60: 1176-1181.
10. Wiltfang J, Schlegel KA, Schultze-Mosgau S, Nkenke E, Zimmermann R, et al. (2003) Sinus floor augmentation with beta-tricalciumphosphate (beta-TCP): does platelet-rich plasma promote its osseous integration and degradation? *Clin Oral Implants Res* 14: 213-218.
11. Aghaloo TL, Moy PK, Freymiller EG (2004) Evaluation of platelet-rich plasma in combination with anorganic bovine bone in the rabbit cranium: a pilot study. *Int J Oral Maxillofac Implants* 19: 59-65.
12. Merx MA, Fennis JP, Verhagen CM, Stoelinga PJ (2004) Reconstruction of the mandible using preshaped 2.3 mm titanium plates, autogenous particulate cortico-cancellous bone grafts and platelet rich plasma: a report on eight patients. *Int J Oral Maxillofac Surg* 33: 733-739.
13. Schlegel KA, Donath K, Rupprecht S, Falk S, Zimmermann R, et al. (2004) De novo bone formation using bovine collagen and platelet-rich plasma. *Biomaterials* 25: 5387-5393.
14. Graziani F, Ducci F, Tonelli M, El Askary AS, Monier M, et al. (2005) Maxillary sinus augmentation with platelet-rich plasma and fibrinogen cryoprecipitate: a tomographic pilot study. *Implant Dent* 14: 63-69.
15. Hokugo A, Ozeki M, Kawakami O, Sugimoto K, Mushimoto K, et al. (2005) Augmented bone regeneration activity of platelet-rich plasma by biodegradable gelatin hydrogel. *Tissue Eng* 11: 1224-1233.
16. Choi BH, Im CJ, Huh JY, Suh JJ, Lee SH (2004) Effect of platelet-rich plasma on bone regeneration in autogenous bone graft. *Int J Oral Maxillofac Surg* 33: 56-59.
17. Wiltfang J, Kloss FR, Kessler P, Nkenke E, Schultze-Mosgau S, et al. (2004) Effects of platelet-rich plasma on bone healing in combination with autogenous bone and bone substitutes in critical-size defects. An animal experiment. *Clin Oral Implants Res* 15: 187-193.
18. Aghaloo TL, Moy PK, Freymiller EG (2005) Evaluation of platelet-rich plasma in combination with freeze-dried bone in the rabbit cranium. A pilot study. *Clin Oral Implants Res* 16: 250-257.
19. Pryor ME, Polimeni G, Koo KT, Hartman MJ, Gross H, et al. (2005) Analysis of rat calvaria defects implanted with a platelet-rich plasma preparation: histologic and histometric observations. *J Clin Periodontol* 32: 966-972.
20. Pryor ME, Yang J, Polimeni G, Koo KT, Hartman MJ, et al. (2005) Analysis of rat calvaria defects implanted with a platelet-rich plasma preparation: radiographic observations. *J Periodontol* 76: 1287-1292.
21. Raghoebar GM, Schortinghuis J, Liem RS, Ruben JL, van der Wal JE, et al. (2005) Does platelet-rich plasma promote remodeling of autologous bone grafts used for augmentation of the maxillary sinus floor? *Clin Oral Implants Res* 16: 349-356.
22. Klongnoi B, Rupprecht S, Kessler P, Thorwarth M, Wiltfang J, et al. (2006) Influence of platelet-rich plasma on a bioglass and autogenous bone in sinus augmentation. An explorative study. *Clin Oral Implants Res* 17: 312-320.
23. Klongnoi B, Rupprecht S, Kessler P, Zimmermann R, Thorwarth M, et al. (2006) Lack of beneficial effects of platelet-rich plasma on sinus augmentation using a fluorohydroxyapatite or autogenous bone: an explorative study. *J Clin Periodontol* 33: 500-509.
24. Plachokova AS, van den Dolder J, Stoelinga PJ, Jansen JA (2006) The bone regenerative effect of platelet-rich plasma in combination with an osteoconductive material in rat cranial defects. *Clin Oral Implants Res* 17: 305-311.
25. Sarkar MR, Augat P, Shefelbine SJ, Schorlemmer S, Huber-Lang M, et al. (2006) Bone formation in a long bone defect model using a platelet-rich plasma-loaded collagen scaffold. *Biomaterials* 27: 1817-1823.
26. Thorwarth M, Wehrhan F, Schultze-Mosgau S, Wiltfang J, Schlegel KA (2006) PRP modulates expression of bone matrix proteins in vivo without long-term effects on bone formation. *Bone* 38: 30-40.
27. Abyholm FE, Bergland O, Semb G (1981) Secondary bone grafting of alveolar clefts. A surgical/orthodontic treatment enabling a non-prosthetic rehabilitation in cleft lip and palate patients. *Scand J Plast Reconstr Surg* 15: 127-140.
28. Marx RE (2004) Platelet-rich plasma: evidence to support its use. *J Oral Maxillofac Surg* 62: 489-496.
29. Enemark H, Sindet-Pedersen S, Bundgaard M (1987) Long-term results after secondary bone grafting of alveolar clefts. *J Oral Maxillofac Surg* 45: 913-919.
30. Giudice G, Gozzo G, Sportelli P, Gargioli F, De Siate A (2007) The role of functional orthodontic stress on implants in residual alveolar cleft. *Plast Reconstr Surg* 119: 2206-2217.
31. Shima K, Ogata K, Suzuki A, Nakamura N, Honda Y, et al. (1998) Evaluation of postoperative resorption of transplanted bone after secondary autogenous particulate cancellous bone and marrow grafting in alveolar cleft (in Japanese with English abstract). *J Jpn Cleft Palate Assoc* 23: 203-213.
32. Soffer E, Ouhayoun JP, Anagnostou F (2003) Fibrin sealants and platelet preparations in bone and periodontal healing. *Oral Surg Oral Med Oral Pathol Oral Radiol Endod* 95: 521-528.
33. Le Guehennec L, Goyenvalle E, Aguado E, Pilet P, Bagot D'Arc M, et al. (2005) MBCP biphasic calcium phosphate granules and tissucol fibrin sealant in rabbit femoral defects: the effect of fibrin on bone ingrowth. *J Mater Sci Mater Med* 16: 29-35.
34. Segura-Castillo JL, Aguirre-Camacho H, Gonzalez-Ojeda A, Michel-Perez J (2005) Reduction of bone resorption by the application of fibrin glue in the reconstruction of the alveolar cleft. *J Craniomaxillofac Surg* 16: 105-112.
35. Catelas I, Sese N, Wu BM, Dunn JC, Helgerson S, et al. (2006) Human mesenchymal stem cell proliferation and osteogenic differentiation in fibrin gels

-
- in vitro. *Tissue Eng* 12: 2385-2396.
36. Huh JY, Choi BH, Zhu SJ, Jung JH, Kim BY, et al. (2006) The effect of platelet-enriched fibrin glue on bone regeneration in autogenous bone grafts. *Oral Surg Oral Med Oral Pathol Oral Radiol Endod* 101: 426-431.
37. Tajima N, Sotome S, Marukawa E, Omura K, Shinomiya K (2007) A three-dimensional cellloading system using autologous plasma loaded into a porous b-tricalciumphosphate block promotes bone formation at extraskeletal sites in rats. *Mater Sci Eng C* 27: 625-632.
38. Petrunaro P (2001) Platelet-rich plasma for dental implants and soft-tissue grafting. Interview by Arun K. Garg. *Dent Implantol Update* 12: 41-46.
39. Petrunaro PS (2001) Using platelet-rich plasma to accelerate soft tissue maturation in esthetic periodontal surgery. *Compend Contin Educ Dent* 22: 729-732.
40. Kimura A, Ogata H, Yazawa M, Watanabe N, Mori T, et al. (2005) The effects of platelet-rich plasma on cutaneous incisional wound healing in rats. *J Dermatol Sci* 40: 205-208.
41. Eppley BL, Pietrzak WS, Blanton M (2006) Platelet-rich plasma: a review of biology and applications in plastic surgery. *Plast Reconstr Surg* 118: 147e-159e.