

Delayed Implant Placement after Extraction Socket Reconstruction and Ridge Augmentation using Autogenous Tooth Bone Graft Material: Case Reports

Lee EG¹, Lee JY¹, Kim YK^{1*}, Um IW² and Choi JH³

¹Department of Oral and Maxillofacial Surgery, Section of Dentistry, Seoul National University Bundang Hospital, South Korea

²R&D Institute Korea Tooth Bank, Seoul, Korea

³The Hill School, Pottstown, Pennsylvania, USA

Abstract

When the extraction site has insufficient bone height or volume for an implantation, an autogenous tooth bone block for a socket reconstruction and bone graft can be implemented. In these case studies, we obtained outstanding treatment outcomes using autogenous tooth bone block reconstructing extracted socket and ridge augmentation. This study presents its clinical and radiological findings together with reviews of related literature.

Keywords: Autogenous tooth bone block; Extraction socket graft; Ridge augmentation

Introduction

It has been reported that implant therapy for the posterior edentulous area is widely being used and its long term prognosis is outstanding. However, when the bone quality of the implant placement site is poor or the amount of residual bone is insufficient, bone graft is inevitable. In such situations, autogenous, allogenic, xenogenic and synthetic bone can be utilized as bone graft materials, and each of them has its strengths and weaknesses [1]. Allogenic and xenogenic bone have a risk of infectious contamination. Xenogenic and synthetic bone show healing through osteoconduction despite of their relatively affordable prices. Autogenous bone is regarded as the "gold standard" of bone graft due to its biocompatibility; it does not have immune rejection response and displays every function of bone formation, osteogenesis, osteoinduction and osteoconduction, and it also offers high stability and low rate of complications after bone graft. However, the weaknesses of autogenous bone are that the collection of it is limited, additional surgery is required in the donor site and the resorption amount after grafting is high [1-3]. Today, autogenous tooth bone graft material is often used as an alternative bony substitute and its excellence has been proved through many studies [4-10].

We installed the implant after grafting using autogenous tooth block in the patients whose residual bone to inferior alveolar nerve canal was significantly insufficient. The satisfactory clinical outcomes were obtained. We present case reports with literature review.

Case Studies

Case 1 (Figure 1)

A female patient, aged 39, visited the hospital to restore the left mandibular 2nd molar missing area. A year ago, the patient received an intentional replantation, but its outcome was a failure and the tooth was extracted. The extracted tooth was treated as demineralized tooth block and stored. Through panoramic radiography, it was determined that the height of the residual bone to the inferior alveolar canal was significantly insufficient and implant installation was impossible.

Flap elevation under local anesthesia was performed removing residual granulation tissue completely, and then demineralized tooth block was grafted and covered with resorbable collagen membrane (Bio-ARMTM, Collagen Matrix, Inc., USA). About 5 months later, the healing state of the grafted site was good so a short implant (TS III

SA Fixture, 5D/6L, OSSTEM implant Co, Busan, Korea) was placed. Implant primary stability was excellent, and the 2nd surgery was performed 9 months later. Upper prosthetic treatment was performed and 14 months after final prosthetic delivery, the prosthesis continued to function normally without unusual discomfort or complications.

Case 2 (Figure 2)

A male patient, aged 39, visited the hospital to restore his missing teeth in the right mandibular posterior area. There were severe bone loss and multiple teeth mobility due to progressive periodontitis. In particular, vertical alveolar bone resorption was severe in the right mandibular 1st molar area and the distance to inferior alveolar canal was only about 4 mm. First, the maxillary hopeless teeth were extracted and then demineralized tooth bone block and chips were fabricated. Sinus bone graft and ridge augmentation were performed under general anesthesia. In particular, ridge augmentation in the right mandible 1st molar area was performed using demineralized tooth bone block and chips and a barrier membrane was not used. 7 months after the bone graft, flap elevation was performed to place an implant in the right mandible 1st molar tooth region. The consolidation of bone graft was excellent. An implant (Superline Fixture, 5D/8L, Dentium, Seoul, Korea) was installed, xenogenic bone graft material (BioCeraTM, particle size 0.4~0.6 mm, 0.25cc, Seongnam, Korea) was applied around small implant dehiscence defect, and then resorbable collagen membrane (CollaGuideTM, Bioland, Cheongwon, Korea) was covered. Primary stability measured using Osstell Mentor was 75 ISQ. After a three-month healing period, the 2nd implant surgery was performed and the secondary stability measured with 81 ISQ. One week after the 2nd surgery, an impression was taken to manufacture the prosthesis and the upper prosthesis was delivered. Radiographs were taken at 6, 9, 12,

***Corresponding author:** Young-Kyun Kim, Department of Oral and Maxillofacial Surgery, Section of Dentistry, Seoul National University Bundang Hospital, 300 Gumi-dong, Bundang-gu, Seongnam city, Gyunggi-do, Korea, Tel: 82-31-787-7541; Fax: 82-31-787-4068; E-mail: kyk0505@snubh.org

Received November 16, 2013; **Accepted** December 04, 2013; **Published** December 06, 2013

Citation: Lee EG, Lee JY, Kim YK, Um IW, Choi JH (2013) Delayed Implant Placement after Extraction Socket Reconstruction and Ridge Augmentation using Autogenous Tooth Bone Graft Material: Case Reports. Dentistry 3: 174. doi:10.4172/2161-1122.1000174

Copyright: © 2013 Lee EG, et al. This is an open-access article distributed under the terms of the Creative Commons Attribution License, which permits unrestricted use, distribution, and reproduction in any medium, provided the original author and source are credited.

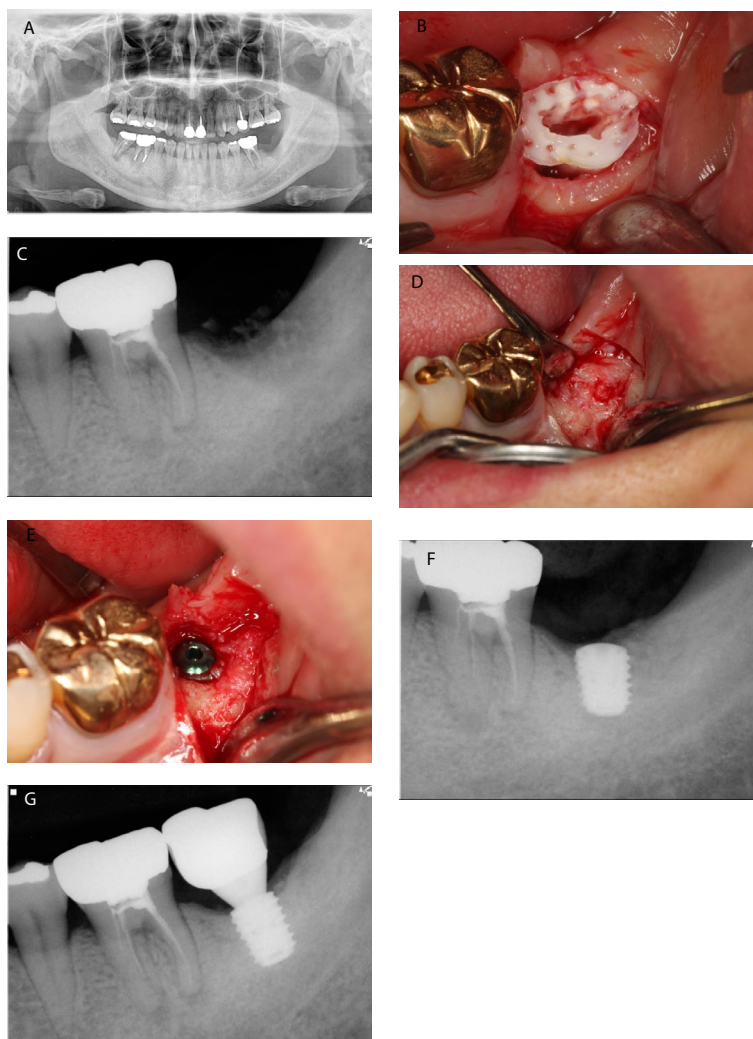


Figure 1: A case of autogenous tooth bone block socket graft followed by implant placement in a 39-year-old female patient.

- A. A panoramic radiograph at the initial examination
- B. Autogenous tooth bone block had been grafted in the tooth extracted site
- C. Postoperative periapical radiograph
- D. 5 months after the graft, well-formed new bones were observed
- E. Short implant was placed at the site
- F. Periapical radiograph after implant placement
- G. Periapical radiograph of the left mandibular second molar 14 months later after prosthetic loading

and 15 months after prosthetic function. The prosthesis continued to function normally without unusual discomfort or complications, in particular, the increased bone density was observed around the implant.

Discussion

Kim et al. have been performing studies of producing bone graft material with extracted human teeth since 1993. However, these studies focused on making powder and block type bone graft materials after burning teeth at high temperatures in order to suppress immune rejection response. These researches have been made with the aim to replace synthetic bones [11-16]. In 2008, Kim et al. developed a method named "autogenous tooth bone graft" which grafted for the patient after extracted tooth of the patient was fabricated into the particulated bone graft material and put to practical use it for clinical application. Autogenous tooth bone graft material was found to possess functions of osteoinduction and osteoconduction both of which display outstanding

bone regeneration. When bone formation is induced with autogenous tooth bone graft material, the tissue specimens displayed outstanding bone regeneration within 3 to 6 months regardless of the barrier membrane. This study discovered that autogenous tooth bone graft material was slowly absorbed as time progressed and newly formed bone grew in great union with the autogenous tooth bone graft material at the resorbed site [10,16-18].

Autogenous tooth bone graft material has two forms; powder type and block type. Powder type is easy for dentists to handle like other bone graft materials, but maintaining the proper form is a challenging obstacle. On the contrary, block type is difficult to fix or produce, but maintaining its form is easy.

When a large amount of bone increase is required for the restoration of severe bone loss or ridge augmentation, autogenous bone graft produces the best outcome. Autogenous bone can be collected from

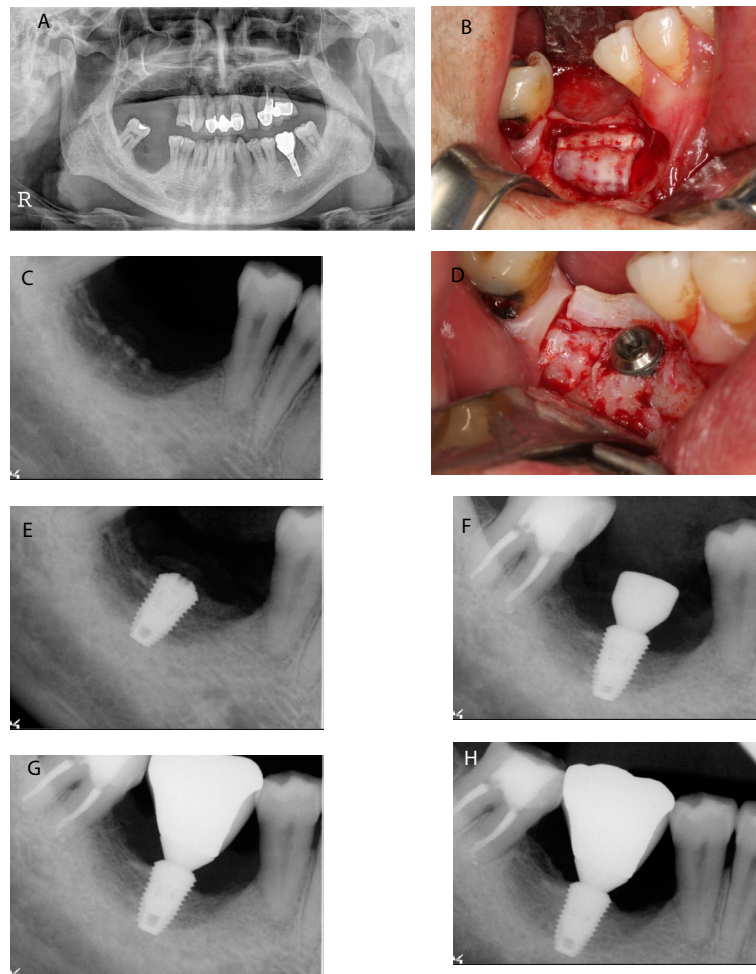


Figure 2: A case of ridge augmentation using autogenous tooth bone block and chips followed by implant placement in a 39-year-old male patient. A. Pretreatment panoramic radiograph. Notice that the absolute short distance between the residual ridge crest and inferior alveolar nerve canal B. Autogenous tooth bone chips and block (sheet-formed) had been grafted in the site C. Postoperative periapical radiograph D. 6 months later, autogenous tooth bone block was still remained on the graft site and no severe graft material resorption was detected. Then the implant fixture was installed E. Periapical radiograph after implant placement F. The 2nd surgery was done after 3 months. Notice that the peri-implant bone density is getting denser G. Periapical radiograph after prosthetic delivery H. Periapical radiograph 15 months after prosthetic loading.

endochondral bones such as ilium, rib and tibia, or intramembraneous bones such as calvaria and facial bone. Endochondral bone is limited in use because its resorption amount after grafting is high and secondary damage occurs at the donor site. On the contrary, intramembraneous bone graft is known for early revascularization and maintenance of bone volume due to slow resorption [19,20]. Kim et al. stated that autogenous tooth bone graft material is a great alternative for free autogenous bone graft, especially when local ridge augmentation is implemented [10]. Autogenous tooth bone block has been mainly used for ridge augmentation or extraction socket restoration. Some studies observed bony healing was fast with abundant lamellar bone formation. Due to such observations, autogenous tooth bone block was regarded as a biocompatible material, which was not resorbed in early stage, capable of bone healing through osteoinduction and osteoconduction [4,5,18].

The extracted 3rd molar or premolar tooth for orthodontic treatment could be utilized as autogenous tooth bone graft material with proper treatment. Deciduous tooth can also be utilized as bone graft material if

proper storage method can be implemented. However, the weakness of autogenous tooth bone graft material is that it can only be implemented when there is a tooth to be extracted and due to this reason, the supply of autogenous tooth bone graft material is limited by numbers. In such case where supply is insufficient, mixing other bone graft materials such as xenogenic bone or synthetic bone may overcome such obstacles. As the amount of residual bone was significantly poor for implant placement in these cases, bone graft procedure had to precede implant placement. By placing implant after a certain period of healing, successful prosthetic treatments were completed. The resorption of marginal bone around the implant was small and the stable outcome was maintained throughout the clinical and radiological assessments. In particular, the radiographic bone density in case 2 continued to gradually increase as time progressed. In this study, however, single short implant was installed at the posterior mandible and crown/implant ratio was not favorable. So the long-term observation of these cases is necessary for the evaluation of the stability of autogenous tooth bone graft and prognosis of short implant.

Acknowledgement

This study was supported by a grant from the Korean Health Technology R & D Project, Ministry for Health and Welfare, Republic of Korea (A102065). The authors reported no conflicts of interest related to this study.

References

1. Hoexter DL (2002) Bone regeneration graft materials. *J Oral Implantol* 28: 290-294.
2. Irinakis T, Tabesh M (2007) Preserving the socket dimensions with bone grafting in single sites: An esthetic surgical approach when planning delayed implant placement. *J Oral Implantol* 33: 156-163.
3. Leonetti JA, Richard K (2003) Localized maxillary ridge augmentation with a block allograft for dental implant placement: Case reports. *Implant Dent* 12: 217-226
4. Kim YK, Kim SG, Kim KW, Um IW (2011) Extraction socket preservation and reconstruction using autogenous tooth bone graft: Case report. *J Korean Assoc Maxillofac Plast Reconstr Surg* 33: 264-269.
5. Kim YK, Kim SG, Um IW (2011) Vertical and horizontal ridge augmentation using autogenous tooth bone graft materials: Case report. *J Korean Assoc Maxillofac Plast Reconstr Surg* 33: 166-170.
6. Hara S, Mitsugi M, Kanno T, Tatmoto Y (2013) Bone transport and bone graft using auto-tooth bone for alveolar cleft repair. *J Craniofac Surg* 24: e65-68.
7. Kim YK, Kim SG, Yun PY, Yeo IS, Jin SC, et al. (2012) Autogenous teeth used for bone grafting: a comparison with traditional grafting materials. *Oral Surg Oral Med Oral Pathol Oral Radiol*.
8. Kim YK, Lee J, Um IW, Kim KW, Murata M, et al. (2013) Tooth-derived bone graft material. *J Korean Assoc Oral Maxillofac Surg* 39: 103-111
9. Kim YK, Lee JK, Kim KW, Um IW, Murata M (2013) Healing mechanism and clinical application of autogenous tooth bone graft material. InTech, Rijeka, Croatia.
10. Kim YK, Kim SG, Byeon JH, Lee HJ, Um IU, et al. (2010) Development of a novel bone grafting material using autogenous teeth. *Oral Surg Oral Med Oral Pathol Oral Radiol Endod* 109: 496-503.
11. Kim YK, Yeo HH, Ryu CH, Lee HB, Ur B, et al. (1993) An experimental study on the tissue reaction of toothash implanted in mandible body of the mature dog. *J Korean Assoc Maxillofac Plast Reconstr Surg* 14: 129-136.
12. Kim YK, Yeo HH, Yang IS, Seo JH, Cho JO (1994) Implantation of toothash combined with plaster of paris: experimental study. *J Korean Assoc Maxillofac Plast Reconstr Surg* 16: 122-129.
13. Kim YK (1996) The experimental study of the implantation of toothash and plaster of paris and guided tissue regeneration using lyodura. *J Korean Assoc Oral Maxillofac Surg* 22: 297-306.
14. Kim YK, Yeo HH (1997) Transmitted electronic microscopic study about the tissue reaction after the implantation of toothash. *J Korean Assoc Oral Maxillofac Surg* 23: 283-289.
15. Kim YK, Kim SG, Lee JH (2001) Cytotoxicity and hypersensitivity test of toothash. *J Korean Assoc Maxillofac Plast Reconstr Surg* 23: 391-395.
16. Kim YK, Kim SG, Lee JG, Lee MH, Cho JO (2001) An experimental study on the healing process after the implantation of various bone substitutes in the rats. *J Korean Assoc Oral Maxillofac Surg* 27: 15-24.
17. Lee JY, Lee J, Kim YK (2013) Comparative analysis of guided bone regeneration using autogenous tooth bone graft material with and without resorbable membrane. *J Dent Sci* 8: 281-286.
18. Kim YK, Lee HJ, Kim KW, Kim SG, Um IW (2011) Guided bone regeneration using autogenous teeth: case reports. *J Korean Assoc Oral Maxillofac Surg* 37: 142-147.
19. Chiapasco M, Zaniboni M, Boisco M (2006) Augmentation procedures for the rehabilitation of deficient edentulous ridges with oral implants. *Clin Oral Implants Res* 17: 136-159.
20. Raghoebar GM, Batenburg RH, Vissink A, Reintsema H (1996) Augmentation of localized defects of the anterior maxillary ridge with autogenous bone before insertion of implants. *J Oral Maxillofac Surg* 54: 1180-1185.