

Closure of Iatrogenic Atrial Septal Defect with Percutaneous Closure Device or Surgery: Which Technique is Safe?

Ersin Kadirogullari*, Ünal Aydın, Onur Şen, Kürşat Öz and İhsan Bakır

Istanbul Mehmet Akif Ersoy Thoracic and Cardiovascular Surgery Training ve Research Hospital, İstanbul, Turkey

*Corresponding author: Ersin Kadirogullari, Istanbul Mehmet Akif Ersoy Thoracic and Cardiovascular Surgery Training ve Research Hospital, Istanbul, Turkey, Tel: 905326736557; E-mail: ersinkadirogullari@gmail.com

Rec Date: September 15, 2015; Acc date: October 21, 2015; Pub date: October 27, 2015

Copy right: © 2015 Kadirogullari E, et al. This is an open-access article distributed under the terms of the Creative Commons Attribution License, which permits unrestricted use, distribution, and reproduction in any medium, provided the original author and source are credited.

Abstract

An iatrogenic atrial septal defect (iASD) is a rare complication in cardiac surgery. A postoperative iASD was closed with a percutaneous closure device in a 37-year-old patient who had undergone mitral valve replacement via transeptal incision. Hemodynamic instability occurred in the 6th hour of the post-procedural period, and echocardiography imaging showed the closure device free in the left atrium. An emergent operation was performed on the patient, the device was retrieved, and the iASD was closed with a pericardial patch. In this study we evaluated the efficiency and safety of percutaneous closure devices, which have been used for iASDs.

Keywords: Atrial septal defect; Mitral valve surgery; Iatrogenic; Percutaneous closure

Introduction

An iatrogenic atrial septal defect (iASD) is an uncommon complication of mitral valve surgery through transeptal incision [1]. Surgical closure for a large iASD is re-operation; however, percutaneous closure with different devices is considered an alternative approach to surgery in small iASDs with an adequate rim [2,3]. The efficiency of closure devices, which are used routinely for the closure of congenital ASD pathologies, is unclear for the treatment of an iASD complication. The percutaneous closure system is a good alternative method because re-operation results in high mortality and morbidity rates. However, the risks of a percutaneous closure procedure should also be considered.

Case

A 37-year-old man was evaluated because of symptoms of fatigue and palpitation. Diagnostic studies showed severe mitral stenosis and atrial fibrillation. The patient underwent mitral valve replacement (27-mm Sorin; SorinBiomedica, Saluggia, Italy) and radio-frequency ablation procedures via transeptal incision. The patient was discharged from hospital asymptotically; nevertheless, on postoperative day 25 the patient re-applied to the emergency department with congestive heart failure symptoms. Transesophageal echocardiography (TEE) showed an atrial septum-located iASD (2.5 cm) and a Qp/Qs rate of 2.5. Based on these results, a percutaneous closure procedure was planned. Under mild sedative anesthesia, a sheath was inserted in the right femoral vein (11 French), and the iASD was crossed with a multipurpose catheter (5F) over a 0.035 Amplatz Super Stiffwire (Boston Scientific Corp., Natick, MA, USA). A helix septal occluder was successfully deployed with excellent positioning and a trivial residual leak (Figure 1). Hemodynamic instability occurred 6 hours after the procedure, and TEE imaging showed that the closure device had dropped into the left atrium (Figure 2). Following embolization of the closure device, the patient

underwent emergent operation with a median sternotomy and cardiopulmonary bypass. The left atrium was explored through the interatrial septum, and the free closure device was retrieved from the chamber. The septal defect was then closed with a pericardial patch (Figure 3). Echocardiography confirmed no residual shunt. The patient was discharged asymptotically and was followed up uneventfully for 6 months.

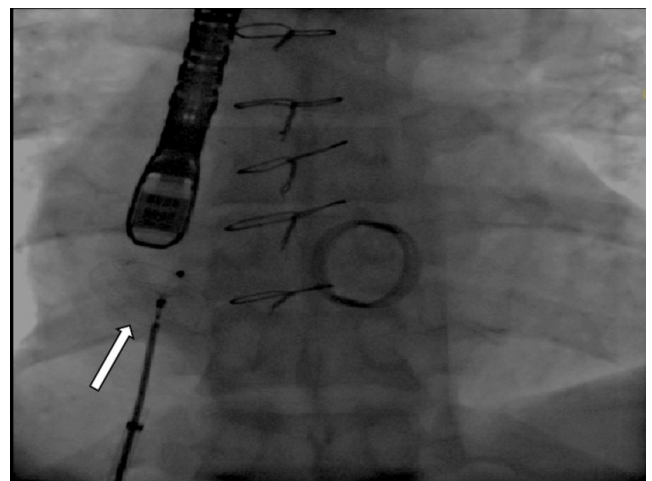


Figure 1: Successful implantation of an iASD closure device under fluoroscopy.

Discussion

Cardiac invasive intervention and alternative surgical procedures are potential risk factors for iASD occurrence. Mitral valve surgery via transeptal incision, left ventricle assist device implantation, Mitraclip system implantation, percutaneous mitral balloon valvuloplasty, and

pulmonary vein cryoablation procedures are the main causes of iASD [3-7].

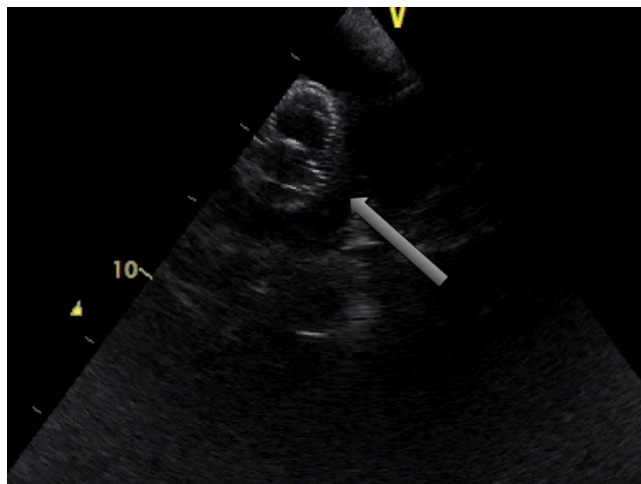


Figure 2: Dropping of a closure device into the left atrium.

A transseptal incision provides optimal surgical exposure for mitral valve surgery [8]. Although iASD occurrence is rare, it is an anticipated risk [9]. With the occurrence of an iASD, the diameter of the ASD or symptoms make an intervention essential for the patient. Percutaneous closure systems have been an alternative to operative procedures because of the high risk of mortality and morbidity of surgery.

The malposition of closure devices is frequently caused by an inadequate rim and inaccurate calibration of the device size during the treatment of congenital ASD with the percutaneous closure technique. However, the etyopathogenesis of this malposition has not been clarified for iASD [10].

Closure device placement could expand the septal defect and cause a device embolization because a closure device applies tension to the surrounding septal tissue. Even if patients with an iASD have been treated successfully with closing systems, hemodynamic monitoring and performing frequent echocardiography imaging are essential during the early post-procedural period. The risk of expanding a septal defect and device embolization should not be underestimated.

Conclusion

Percutaneous closure device placement for an iASD, which is related to a transseptal incision, is an alternative to surgery. Closure device placement for a postoperative iASD, which originates from suture defects of transseptal closing, might cause expansion of the defect and embolization of the device. Consequently, the potential risks of this procedure should be kept in mind, and close follow-up should be performed, especially in the early post-procedural period.

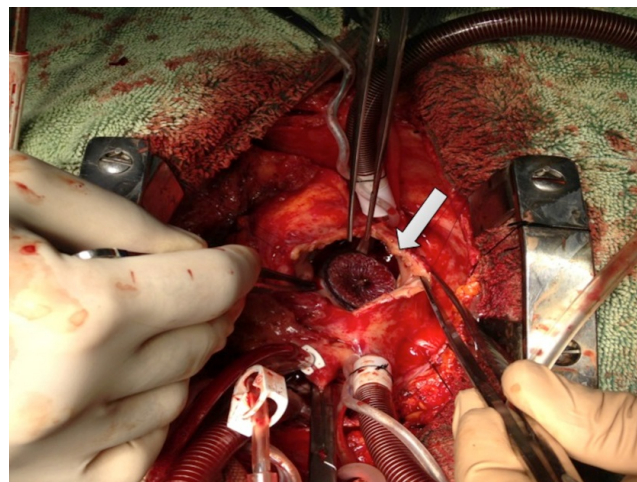


Figure 3: Retrieving the device from the left atrium.

References

1. Timmis Gerald C, Seymour Gordon SA Razvi (1972) Iatrogenic atrial septal defect: An unusual complication of valvular heart surgery. *American Heart Journal* 83: 804-809.
2. Khanna, Avinash, Jaime Barberena, David Skolnick (2005) An unusual case of shunting across the atrial septum after mitral valve repair. *Journal of the American Society of Echocardiography*. 18: 78-79.
3. Pitcher A, Schrale RG, Mitchell AR, Ormerod O (2008) Percutaneous closure of an iatrogenic atrial septal defect. *Eur J Echocardiogr* 9: 294-295.
4. Sur JP, Pagani FD, Moscucci M (2009) Percutaneous closure of an iatrogenic atrial septal defect. *Catheter Cardiovasc Interv* 73: 267-271.
5. Schueler R, Öztürk C, Wedekind JA, Werner N, Stöckigt F, et al. (2015) Persistence of iatrogenic atrial septal defect after interventional mitral valve repair with the MitraClip system: a note of caution. *JACC Cardiovasc Interv* 8: 450-459.
6. Korkmaz S, Demirkan B, Guray Y, Yilmaz MB, Sasmaz H (2011) Long-term follow-up of iatrogenic atrial septal defect after percutaneous mitral balloon valvuloplasty. *Texas Heart Institute Journal* 5: 523-524.
7. Rillig A, Meyerfeldt U, Birkemeyer R, Treusch F, Kunze M, et al. (2008) Persistent iatrogenic atrial septal defect after pulmonary vein isolation: incidence and clinical implications. *J Interv Card Electrophysiol* 22: 177-181.
8. Cohn LH, Edmunds LH Jr (2003) *Cardiac surgery in the adult* (2nd edn), McGraw-Hill.
9. Khanna A, Barberena J, Skolnick D (2005) An unusual case of shunting across the atrial septum after mitral valve repair. *J Am Soc Echocardiogr* 18: 78-79.
10. Misra M, Sadiq A, Namboodiri N, Karunakaran J (2007) The 'aorticrim' recount: Embolization of interatrial septal occluder into the main pulmonary artery bifurcation after atrial septal defect closure. *Interact Cardiovasc Thorac Surg* 6: 384-386.