

Clinical Outcome of Autologous Cultivated Limbal Epithelial Transplantation Therapy for Patients with Ocular Surface Disease

Umamathy T^{1*}, Alias R¹, Lim MN², Alagaratnam J¹, Zakaria Z² and Lim TO³

¹Department of Ophthalmology, Kuala Lumpur Hospital, Malaysia

²Institute for Medical Research, Kuala Lumpur, Malaysia

³Virtuallux Sdn Bhd, Kuala Lumpur, Malaysia

Abstract

Introduction: Cultivated Limbal Epithelial Cells Transplantation (CLET) has been proven effective in reconstructing cornea surface of Limbal Stem Cell Deficiency (LSCD). To better understanding the potential and risk of this treatment in our current setup, we conducted a phase I clinical trial and determined the outcome of cultivated limbal epithelial transplantation for Ocular Surface Disease (OSD).

Methods: Prospective interventional trial was conducted in Hospital Kuala Lumpur, Malaysia. Fourteen eyes of 14 patients with limbal stem cells deficiency: chemical injury (6), advanced pterygium (4), advanced Vernal Kerato Conjunctivitis (VKC) (2), Persistent Epithelial Defect (PED) (1) and Ocular Cicatricial Pemphigoid (OCP) (1) were selected according to the inclusion/exclusion criteria. Autologous cornea limbal epithelial stem cells were cultured on human amniotic membrane and subjected to immunohistological staining for a panel of markers (ABCG2, cytokeratins (K) 3, K19, p63, involucrin, integrin $\alpha 9$ and K14). Cell sheets with epithelial morphology and growth area greater than 80% will be used for CLET. Two weeks later, the tissue was transplanted to the recipient eyes after superficial keratectomy. The patients were followed up for 1 year. Outcome measures were improvement of symptoms, an improvement in visual acuity, no conjunctivalisation and vascularisation and healed persistent corneal epithelial defect.

Results: Ten patients (71.4%) had an improvement in visual acuity of at least two lines at 6 months and one year ($p < 0.05$). Thirteen patients (92.8%) had cornea epithelisation in 1 month. The patient with persistent epithelial defect (PED) healed in 3 months and the patient with ocular cicatricial pemphigoid (OCP) had recurrent cornea epithelial defect at 6 months and healed after one year. On slit lamp examination, eight patients (57.1%) had no cornea vascularisation in 6 months and 1 year ($p < 0.05$). Ten patients (71.4%) had no cornea conjunctivalisation in 6 months and 1 year ($p < 0.05$).

Conclusions: Transplantation of cultivated autologous limbal epithelial cell can efficiently restore the cornea with improved vision. Patients with chemical injury, advance pterygium group had better outcome results.

Keywords: Ocular surface disorder; Corneal transplant; Limbal stem cell deficiency; Cultivated limbal epithelial cells transplantation; Pterygium; Cornea epithelial stem cells; Clinical trial

Introduction

The corneal epithelium is responsible for maintaining a smooth ocular surface as well as providing a protective barrier. The renewal of these cells is derived from the corneal epithelial stem cells residing in the limbal palisades of Vogt and the interpalisade ridges [1-3]. In ocular chemical and thermal injuries, depending on the severity, there may be loss of epithelial stem cells resulting in limbal stem cell deficiency (LSCD) [4,5]. Patients will present with painful blind eyes due to persistent epithelial defects, ulceration and eventually cornea perforation leading to blindness. Additionally, the conjunctiva will be scarred with the formation of symblepharon and dry eye, contributing to further destabilization of the ocular surface. Conventional corneal transplantation will lead to graft failure and rejection because of LSCD [3-5].

In partial limbal stem cell deficiency, mechanical debridement of conjunctivalised epithelium and amniotic membrane transplantation (AMT) helps to prevent conjunctivalised epithelium from crossing the limbus and allows healing of the epithelial defect [6,7]. However, AMT is only a temporary measure for cases with total limbal stem cell deficiency and studies have described successful limbal autograft transplantation with no recurrent erosions or persistent epithelial defects, regressed corneal vascularisation and improved visual acuity

[8,9]. However in limbal allograft transplantation, there is a risk of graft rejection because of the immunological destruction of limbal stem cells requiring long term systemic immunosuppressant with possible adverse effects. Half of these transplants fail within 3 to 5 years [10,11].

Ex-vivo cultivated epithelial transplantation has been described using autologous limbal epithelium [12-17]. Long term results of CLET have shown that more than 70% of patients with unilateral OSD have attained permanent restoration of a transparent corneal epithelium at 1 year of follow-up [18]. Paulkin et al. have shown transplantation of limbal epithelium cultivated on intact amniotic membrane restored a noninflamed ocular surface and a corneal phenotype [19].

***Corresponding author:** Dr. Thiageswari Umamathy, MBBS (Mysore), MSOphth (National University of Malaysia), Consultant of Ophthalmologist, Department of Ophthalmology, Hospital Kuala Lumpur, 50588 Jalan Pahang, Kuala Lumpur, Malaysia, Tel: +60326162714; E-mail: thiagesw@yahoo.com

Received October 22, 2014; **Accepted** November 20, 2014; **Published** November 22, 2014

Citation: Umamathy T, Alias R, Lim MN, Alagaratnam J, Zakaria Z, et al. (2014) Clinical Outcome of Autologous Cultivated Limbal Epithelial Transplantation Therapy for Patients with Ocular Surface Disease. J Stem Cell Res Ther 4: 248. doi:10.4172/2157-7633.1000248

Copyright: © 2014 Umamathy T, et al. This is an open-access article distributed under the terms of the Creative Commons Attribution License, which permits unrestricted use, distribution, and reproduction in any medium, provided the original author and source are credited.

In our tertiary centre, there are various causes and severity of LSCD cases especially chemical injuries and fibrovascular disease of cornea of non-chemical in nature. This report presents the results of a clinical trial to demonstrate the clinical efficacy and safety of CLET for various OSD.

Materials and Methods

We conducted a prospective open label single group clinical trial at a single center to replicate the clinical efficacy of CLET as implemented by our laboratory and clinic.

The study was conducted in accordance with Declaration of Helsinki and Good Clinical Practice (GCP) requirements. The institutional review-board of the study site approved the protocol, and informed consent was obtained from all patients.

Study patients

The inclusion criteria were ages between 18 and 75 years with unilateral LSCD treated conservatively for 2-12 months. Limbal stem deficiency was diagnosed by the presence of symptoms such as decreased vision, redness, watering, photophobia and recurrent attacks of pain. The signs of LSCD are conjunctivalisation, neovascularisation, recurrent or persistent epithelial defects and chronic inflammation. The study patients had unilateral severe LSCD which included severe chemical injuries, recurrent/advanced pterygium, VKC, OCP and PED with anterior stromal dystrophy.

The exclusion criteria were pregnant or nursing woman; positive HIV, hepatitis B and C; history of pulmonary tuberculosis, cancer and organ transplant.

Human Amniotic Membrane (HAM)

It is a thin, semitransparent tissue, the innermost layer of the foetal membrane and has a stromal matrix, thick collagen layer and basement membrane of a single layer of epithelium. The membrane has anti-inflammatory, anti-immunogenic properties and could be used as carrier tissue for cultivated limbal corneal cells [3]. The epithelium of HAM is reported to produce growth factors and the thick basement membrane supports the growth of corneal epithelial cells [3].

Preparation of Human Amniotic Membrane (HAM)

HAM was obtained from a consented patient who had undergone an elective caesarean section. During the antenatal period and prior to surgery, the patient was screened for syphilis (VDRL), human immunodeficiency virus (HIV), hepatitis B and C [6]. The placenta was cleaned of blood clots in the operating theatre using sterile saline and HAM was separated from the rest of the chorion by blunt dissection and sent to the laboratory. The membrane was rinsed with normal saline containing antibiotics and antimycotics and flattened with a nitrocellulose paper with the epithelium/ basement membrane facing upwards. It was cut into smaller pieces 3×3 cm² and preserved in glycerol at -80°C in a sterile vial for less than a year [20].

Procurement of limbal biopsy

The patient with unilateral LSCD was selected for CLET and informed consent was taken for obtaining limbal biopsy. It was performed on the normal contralateral eye under local anaesthesia. The eye was cleaned with povidone-iodine and a piece of limbal tissue 2×2 mm² at the limbus (12 o'clock) was dissected into the clear cornea up to 1 mm using a disposable crescent handle. The limbal tissue sample was collected and stored in the Human Corneal Epithelial Media (HCEM)

in an ependorff tube and sent to the Good Manufacturing Practice laboratory for culturing on the HAM.

Cell culture

Autologous limbal biopsies (2×2 mm² in size) were taken from 14 patients' contralateral eye and cultured on human amniotic membranes as reported previously [4]. Prior to receiving the limbal biopsy, amniotic membranes (3×3 cm²) were de-epithelialised by adding 2 mL 0.25% trypsin-EDTA and incubated for 25 min at 37°C with 5% CO₂. The trypsinisation process was then stopped by adding 5 mL of human corneal epithelium medium (HCEM) onto the HAM. HCEM was a mixture of Dulbecco's Modified Eagle Medium: Nutrient Mixture F-12 (D-MEM/F-12), 10% human autologous serum, 5µg/mL rh-insulin, 10 ng/mL rh-epidermal growth factor, antibiotic-antimycotic (all from Invitrogen Corporation, Carlsbad, CA, USA) and 0.1 µg/mL hydrocortisone (Sigma-Aldrich Chemic, Steinheim, Germany). The epithelial layer of amniotic membranes was gently scraped off by using cell scrapper and then washed twice with phosphate buffered saline (PBS). The de-epithelialised AM were spread onto sterile glass slides (2.5×2.5 cm²) and placed into 60 mm culture dishes carefully. Fresh limbal biopsy was cut into 4-6 small pieces and explanted onto the de-epithelialised AM. Prior adding of 4 mL HCEM, the culture plates were placed into a 37°C CO₂ incubator for 30 min to allow the adhesion of the explants onto the AM. The culture medium was replaced every alternate day and cell growth was monitored under phase contrast microscope. Cells were cultured until approximately 80-100% confluence [20].

Prior to harvesting for clinical application, the spent media was subjected to sterility test by spreading sufficient amount of cultured medium onto nutrient agar and potato dextrose agar plates and observed after 3-5 days incubation at 37°C . For endotoxins test, a gel-clot method with Limulus ES-II (Wako Pure Chemical Industries, Ltd., Osaka, Japan) was performed according to manufacturer's instructions. Briefly, 0.1 mL of spent media was added into a Limulus tube which contained Limulus Amoebocyte Lysate (LAL) reagent solution and mixed gently. Then, the tube was incubated for one hour at 37°C along with positive and negative controls. Positive result was defined if a gel clot was formed when the tube was turned upside down after incubation; whilst negative result was defined if there was no gel clot formation.

Upon harvesting i.e. after two weeks of culturing, confluency $>80\%$, cultivated limbal epithelial cell sheets were removed from the glass slides and placed securely into a new culture dish. Small amount of HCEM was then added onto the cell sheets to keep the limbal epithelial cells alive and the culture dish was sealed with parafilm before sending it to operation theatre. Extra cell sheets were paraffin embedded and subjected to immunohistological staining for a panel of markers (ABCG2, cytokeratins (K) 3, K19, p63, involucrin, integrin $\alpha 9$ and K14) by using the IHC Select® Immunoperoxidase Secondary Detection System (Millipore, Temecula, CA, USA) as previously reported [20].

Transplantation of limbal epithelial cells cultured on HAM

Peritomy was performed at the limbus and the corneal fibrovascular tissues were removed by superficial lamellar keratectomy and sent for histopathological examination. If there was sectorial limbal and corneal damage with a normal central cornea, then limbal epithelial sheet transplanted and fashioned according to the size of the recipient eye. In cases where the damage was to the entire limbal and corneal surface, the limbal epithelial sheet transplanted over the whole damaged cornea.

The transplantation of the cultivated corneal epithelial sheet together with HAM was placed with the epithelial side up on the affected eye. The graft was then secured to the corneal side with interrupted 10-nylon sutures and to the surrounding conjunctival edge with 8-0 vicryl sutures. During the procedure, the cultivated limbal epithelium was protected with sodium hyaluronate (Healon, Pfizer). After surgery, therapeutic contact lens was inserted and Gutt Dexamethasone 0.1% and Gutt Ciprofloxacin was instilled every 2 hours topically for the first week and then tapered accordingly depending on the severity of inflammation and conjunctival congestion around operated area.

Outcome measures

Study visits post-transplant occurred at the first week, first month, 3 months, 6 months, 9 months and 1 year for efficacy and safety assessments for the duration of the study. The outcome measures were reduction/disappearance of symptoms, decreased cornea vascularisation and cornea conjunctivalisation. This was done by an independent observer.

Statistical analysis

All data were analysed with SPSS version 20. All data were analyzed for normal distribution and found to be non-parametric data. The data were analyzed using Wilcoxon Signed rank test. Visual acuity was assessed by using Snellen Chart and converted into logmar, for the visual acuity of counting fingers was categorized as an acuity of logmar 2.0, hand movement as logmar 3.0 and light perception as logmar 4.0 [21].

Results

A total of 14 CLET were done in 14 eyes among the 14 patients according to the inclusion and exclusion criteria and there were no intra-operative complications reported. All patients completed 1 year of follow-up. The clinical outcome of CLET was summarized in Table 1. The mean (SD) age of the patients was 42.29 years (range 21 to 66), and 86.0% were men.

The causes of LSCD in this clinical series were severe chemical burns grade 3 (6 cases), recurrent / advanced pterygium (4 cases), VKC (2 cases), OCP (1 case) and PED with anterior stromal dystrophy (1 case). Figure 1 represents 4 eyes pre- and post CLET.

Median visual acuity preoperatively was 2.00. Ten patients (71.4%)

had an improvement in visual acuity of at least two lines at 6 months post CLET median 1.00 (0.56-1.65), $p=0.012$ and improved at 12 months post CLET median 1.00 (0.60-1.40), $p=0.008$. Nine patients (64.2%) had functional ambulatory vision 6/60 and better post operatively as compared to only 2 patients preoperatively. Five patients had poor VA due to residual cornea scar and cataract. One of the patients with VKC had improved vision in the early postoperative stage, however at 6 months and one year follow-up, the vision decreased because of recurrent inflammation.

Ten patients (71.4%) had cleared all the symptoms at 1 month whereas three patients had persistent symptoms until 3 months and one patient at 1 year. The persistent symptoms cases were due to vernal allergy conjunctivitis (2 patients) and recurrent or advanced pterygium (2 patients).

Ocular surface findings noted eight patients had cornea vascularization out of which six patients had 12 clock hours, one had 9 clock hours and one had 2 clock hours, median 5.50 (0.05-12.05). Post 6 months CLET, six patients had reduced vascularization 2 to 8 clock hours and two patients had no vascularization, median 0.05 (0.05-2.50), $p=0.012$. The cornea vascularization also reduced at 1 year, median 0.05 (0.05-4.50), $p=0.018$. Thirteen patients (92.8%) had cornea conjunctivalisation. Preoperatively, most of the patients had 12-clock hour's conjunctivalisation median 7.50 (4.75-12.05). Post 6 months CLET, eleven patients (78.5%) had no more cornea conjunctivalisation median 0.05 (0.05-0.25), $p=0.001$. Ten patients (71.4%) had no conjunctivalisation at 1 year, median 0.05 (0.05-1.05), $p=0.001$. Three patients had 1 to 2 clock hours of recurrent conjunctivalisation. Thirteen patients (92.8%) had complete cornea epithelisation in 1 month and the patient with PED had complete epithelisation in 3 months. The patient with OCP had systemic immunosuppressive therapy, however she had recurrent cornea epithelial defect twice but resolved eventually. None of the patients had unfavorable outcome.

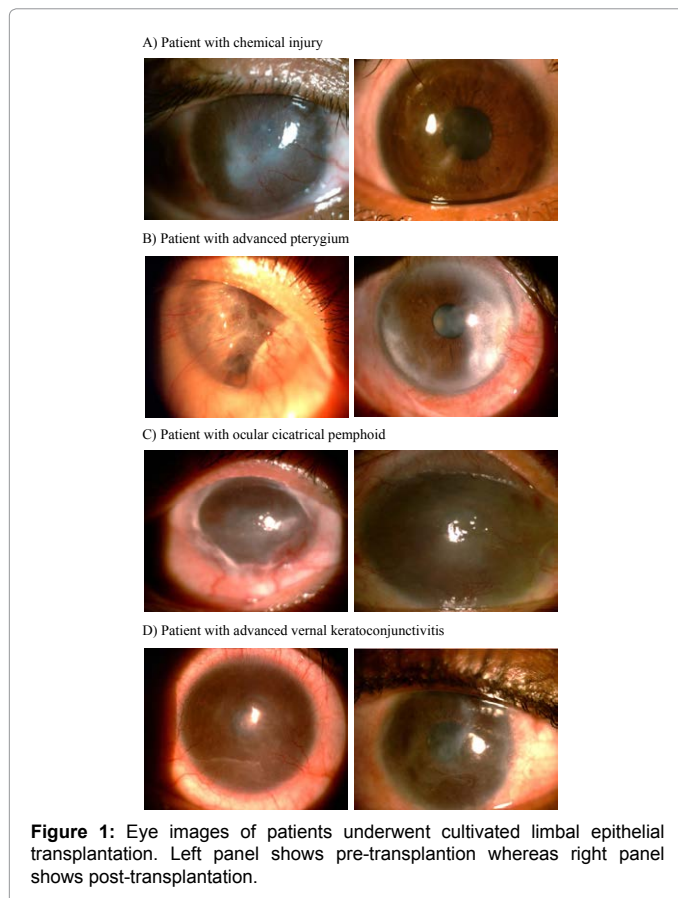
Characterization of limbal epithelial cell sheets

Cell culture, sterility and endotoxins test results were shown in Table 2. All limbal biopsies were successfully grown on AM with HCEM supplemented with autologous serum. Polygonal cells with growing edge were visible after three days of culture (Figure 2A). Hematoxylin and eosin staining showed small cuboidal cells with prominent nucleus (Figure 2B). The average of cell confluency was 87.57% after two weeks

Case	Visual Acuity				Cornea vascularization (clock hours)			Conjunctivalization (clock hours)		
	Preop	Postop 6 months	Postop 1 year	BCVA	Preop	Postop6 months	Postop1 year	Preop	Postop 6 months	Postop 1 year
1. Chemical injury 1	CF	CF	6/60 ph 6/30	6/30	12	2	1	12	nil	nil
2. Chemical injury 2	PL	6/120,ph 6/60	6/60 ph 6/45	6/45	12	nil	nil	12	nil	nil
3. Chemical injury 3	HM	HM	HM Cataract	HM	9	4	4	6	nil	nil
4. Chemical injury 4	6/18	6/18, ph 6/12	6/24 ph 6/9	6/9	nil	nil	nil	4	2	2
5. Chemical injury 5	CF	6/45 ph 6 /15	6/24 ph 6/12	6/12	12	nil	nil	12	nil	nil
6. Chemical injury 6	HM	6/60	6/60 ph 6/30	6/30	nil	nil	nil	7	1	1
7. Pterygium 1	6/60	6/60 ph 6/12	6/60 ph 6/7.5	6/7.5	2	1	2	6	nil	nil
8. Pterygium 2	HM	1/60	2/60	2/60	nil	nil	nil	5	nil	nil
9. Pterygium 3	CF	6/18	6/9	6/9	nil	nil	nil	4	nil	1
10. Pterygium 4	HM	6/24 ph 6/18	6/18	6/18	nil	nil	nil	8	1	1
11. VKC 1	6/120	6/120 ph 6/60	1/60 ph 2/60	2/60	12	8	8	12	nil	nil
12. VKC 2	CF	6/18	6/30	6/30	12	1	6	12	Nil	nil
13. OCP	6/120	6/60	6/60	6/60	12	6	6	12	nil	nil
14. PED	CF	CF	CF	CF	nil	nil	nil	nil	nil	nil

Abbreviation: VKC: Advanced Vernal Keratoconjunctivitis, OCP: Ocular Cicatricial Pemphoid; PED: Persistent Epithelial Defect; Preop: Pre-operation; Postop: Post-operation; BCVA: Best Corrected Visual Acuity; CF: Counting Finger; PL: Perception of Light; HM: Hand Movement; ph: Pin Hole; nil: None

Table 1: Outcome of cultivated limbal epithelial cells transplantation for all patients.



Test	Result
Average confluency	87.57%
Sterility Test	14/14 Negative
Endotoxin Test	14/14 Negative

Table 2: Cell culture results.

of culture and none of the limbal cultures were detected for bacteria mould and yeast growth. All limbal cultures (100%) were negative for endotoxin test. Immunohistological analysis (Figure 3) showed that the cultured cells expressed markers of limbal epithelial progenitor such as p63 and K19. In addition, markers of differentiation such as K3, K14 and involucrin were also detected.

The confluency of growing area was determined visually, whereas sterility and endotoxin tests were performed according to protocols as mentioned in Methods.

Discussion

Reconstruction of OSD in severe limbal stem deficiency cases is challenging and in recent years, studies have shown that transplantation of cultivated corneal epithelial cell sheets for severe OSD have been successful. In our clinical set up, we performed CLET on 14 patients with varied unilateral OSD in this prospective study. We obtained a successful outcome, with diminished symptoms and restoration of a stable ocular surface in 13 (93%) of the 14 patients. Ten (71.43%) patients had improvement of 2 or more lines in Best Corrected Visual Acuity at 6 months post-transplant. Our results indicated that the regenerated epithelium from our CLET procedure had successfully engrafted at 1 year after transplantation.

Since the first CLET was conducted in the 1990's, different culturing methods have been used together with different type of substrates for the production of limbal epithelial cell sheets. For example, the Japanese group [22] used suspension culture method to grow limbal epithelial cells on amniotic membrane. While the current advance of producing clinical trial product is xenograft free, one of the drawback of this method is that it requires feeder cell layer from mouse NIH 3T3 to support the growth of limbal epithelial stem/progenitor cells. Until today, amniotic membrane is still a proven good substrate for the growth of cornea epithelial cells because the extra cellular matrix of amniotic membrane not only resembles that in limbal basal membrane but also due to its anti-apoptosis and anti-inflammatory properties [23,24]. However, use of other substrate such as fibrin and therapeutic contact lens had also shown good results as compared to amniotic membrane in the treatment of LSCD [25,26]. Recently, other types of substrate have been reviewed extensively by Feng et al. [27].

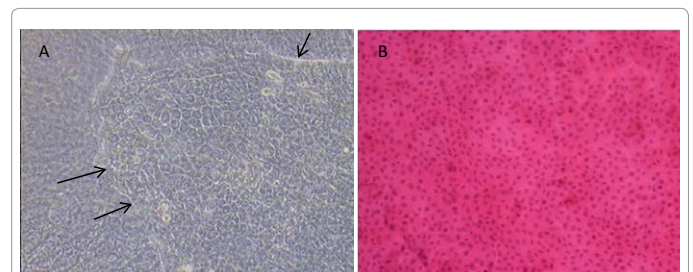


Figure 2: Morphological analysis of cultivated limbal epithelial cells. (A) Phase contrast of polygonal limbal epithelial cells growing on amniotic membrane. Arrows indicate growing edge of limbal epithelial cells. (B) A confluent layer of limbal epithelial cells stained with hematoxylin and eosin. Magnification 40x for both images.

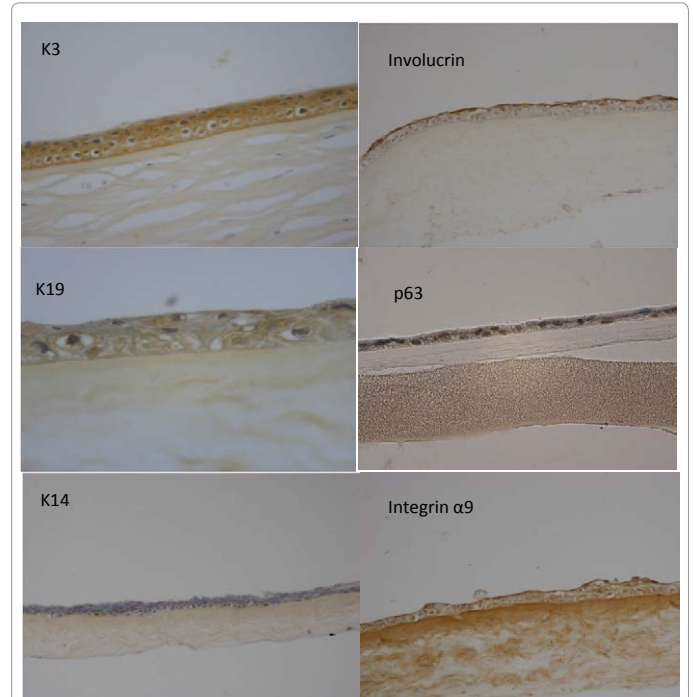


Figure 3: Immunohistochemical staining of cultured human epithelial cells on amniotic membrane. (A) Limbal epithelial cells were positive for K3 (brown; magnification 200x). (B-D) Part of the cells were positive for involucrin, K19 (basal layer only; 400x) and p63 (brown; magnification 400x). (E-G) The cultured cells were negative for K14 (200x) but positive for integrin α 9 (200x).

In this study, we adapted explant culturing method used by Sangwan et al. [18] and applied amniotic membrane for the production of limbal epithelial cell sheets. This method is xeno-free because we eliminated the use of mouse feeder and fetal bovine serum. Our cell culture results and immunohistochemical analysis concurred with that reported by Sangwan et al. [18]. In addition, our results showed that human autologous serum could serve as a good replacement for fetal bovine serum in supporting the growth of limbal progenitor cells as well as differentiated epithelial cells even without using mouse feeder layer. Although autologous serum is variable in terms of hormones and growth factors content [28], but it fulfills the concept of 'personalized medicine'. Despite the use of mouse feeder cells by most centers, this study has proven that xeno-free cell culture method i.e. without the use of animal materials such as mouse feeder fibroblast and fetal bovine serum was feasible to produce good clinical outcome.

The clinical outcome in this study is defined as stability of ocular surface and improved visual acuity. We followed patients at 1 month, 3 months, 6 months and 1 year. For the statistical analysis we reported the ocular surface signs only at 6 months and 1 year follow up because the first 6 months is the critical period for survival [18]. The donor sites of these patients healed well.

In this study, the visual acuity (VA) improved at least two lines (71.4%). Preoperatively, the functional ambulatory vision of $\leq 6/60$ was 14.2% compared to 64.2% postoperatively. Though visual acuity was used as evaluation criteria, it was helpful for patients who had epithelial involvement. However, the patients with poor vision had residual stromal cornea scar and cataract. Sangwan et al. [18], reported the vision was 21.8% (17/78) preoperatively compared to 52.6% (41/78) postoperative had VA $\leq 20/200$. However in their study, they proceeded with penetrating keratoplasty for their residual cornea scar patients. In a study by Koizumi et al. [22], all 13 patients had improved vision and 10/13 had improved 2 or more lines after 6 months and Prabhasawat et al. [29], 73.7% (14/19) of eyes had VA improvement after CLET in Table 1, CLET was done for various types of OSD with moderate and severe limbal stem cell deficiency.

The patients with chemical injury had significant regression of cornea vascularization and conjunctivalisation with favourable outcome as shown in Table 1. Patients with advanced pterygium also improved with CLET. However, the patients with VKC had recurrent vascularization due to ocular surface inflammation. Espana et al. also reported that cross section of their total limbal stem cells pannus tissue showed inflammatory cells infiltration in their entire specimen supporting that inflammation played a significant role in the development and maintenance of total limbal stem cells deficiency [30]. In addition in this group of patients, longer anti-inflammatory is required and perhaps antiangiogenic therapy would be beneficial [31]. The patient with OCP had a good outcome initially and was also systemically immunosuppressed. However, the patient developed epithelial defect and cornea vascularization on follow up at 6 months secondary to the inflammation when her oral steroid was reduced. The epithelial defect healed within one month with lubricants and she did not develop extensive conjunctivalisation. Shimazaki et al. [32] reported CLET for chronic cicatricial surface disorder showed moderate success rates and CLET treatment was feasible for eyes with non-immune-mediated disorders. The patient with PED had history of cataract surgery done in the left eye. She also had anterior stromal dystrophy in both eyes which was more severe in the left eye involving the visual axis. She was not keen for corneal graft and CLET was done in the left eye. The PED had delayed healing of 3 months due diabetic neuropathy and uncontrolled diabetes mellitus.

The overall symptoms improved and none of the patients had repeated CLET or unfavorable outcome like cornea perforation and microbial keratitis. Shimazaki et al. [33] reported 2/13 of his patients had infective keratitis and 4/12 had cornea perforation. Sangwan et al. [18] reported two patients had phthisis bulbi, and one patient had cornea perforation and 2 had microbial keratitis.

A novel surgical technique, namely simple limbal epithelial transplantation (SLET) has been introduced by Sangwan et al. [34] in 2012. This technique requires less donor tissue for conventional autografting and bypasses the need to expand the limbal biosy in a costly GMP facility. This method will be helpful where there is limited resources and the treatment depends on patient's eye pathology.

Conclusion

We have successfully replicated the laboratory and clinical procedures to perform CLET in our practice. Autologous CLET was effective in restoring both corneal epithelium and vision improvement in two thirds of patients with symptomatic relief in nearly all patients. The success however varies with the etiology of LCSD, best being in chemical injury. CLET could be considered as a viable option for patients with advanced LSCD.

Acknowledgement

We would like to thank the late Dr. ST Nathan (Obstetrics & Gynaecology Department, HKL) for providing the amniotic membrane tissue. We thank the Director General of Health, Malaysia for permission to publish this paper.

Role of the Funding Source and Other Parties

The study was funded by Ministry of Health. Virtuallux SB provided the Good Manufacturing Practice laboratory services. An independent clinical research organization (CRO), Klinseel SB, managed and monitored the conduct of the trial, undertook data management and safety surveillance. All data on efficacy, safety and other pre-determined variables were subjected to verification against source document. Investigators and biostatisticians of the CRO performed data analysis jointly.

References

1. Dua HS, Azuara-Blanco A (2000) Limbal stem cells of the corneal epithelium. *Surv Ophthalmol* 44: 415-425. [PubMed]
2. Goldberg MF, Bron AJ (1982) Limbal palisades of Vogt. *Trans Am Ophthalmol Soc* 80: 155-171. [PubMed]
3. Dua HS (1995) Stem cells of the ocular surface: scientific principles and clinical applications. *Br J Ophthalmol* 79: 968-969. [PubMed]
4. Tseng SC (1989) Concept and application of limbal stem cells. *Eye* 3: 141-157. [PubMed]
5. Dua HS, Saini JS, Azuara-Blanco A, Gupta P (2000) Limbal stem cell deficiency: concept, aetiology, clinical presentation, diagnosis and management. *Ind J Ophthalmol* 48: 83-92. [PubMed]
6. Azuara-Blanco A, Pillai CT, Dua HS (1999) Amniotic membrane transplantation for ocular surface reconstruction. *Br J Ophthalmol* 83: 399-402. [PubMed]
7. Konomi K, Satake Y, Shimamura S, Tsubota K, Shimazaki J (2013) Long-term results of amniotic membrane transplantation for partial limbal deficiency. *Cornea* 32: 1110-1115. [PubMed]
8. Kenyon KR, Tseng SC (1989) Limbal autograft transplantation for ocular surface disorders. *Ophthalmology* 96: 709-722. [PubMed]
9. Meallet MA, Espana EM, Grueterich M, Ti SE, Goto E, et al. (2003) Amniotic membrane transplantation with conjunctival limbal autograft for total limbal stem cell deficiency. *Ophthalmology* 110: 1585-1592. [PubMed]
10. Dua HS, Azuara-Blanco A (1999) Allo-limbal transplantation in patients with limbal stem cell deficiency. *Br J Ophthalmol* 83: 414-419. [PubMed]
11. Ilari L, Daya SM (2002) Long term outcomes of keratolimbal allograft for the treatment of severe ocular surface disorders. *Ophthalmology* 109: 1278-1284. [PubMed]

12. Holland EJ, Schwartz GS (2000) Changing concepts in the management of severe ocular surface over twenty-five years. *Cornea* 19: 688-698. [[PubMed](#)]
13. Pellegrini G, Traverso CE, Franz AT, Zingirian M, Cancedda R, et al. (1997) Long-term restoration of damaged corneal surfaces with autologous cultivated corneal epithelium. *Lancet* 349: 990-993. [[PubMed](#)]
14. Tsubota K, Satake Y, Kaido M, Shinozaki N, Shimmura S, et al. (1999) Treatment of severe ocular- surface disorders with corneal epithelial stem-cell transplantation. *New Eng J Med* 340: 1697-1703. [[PubMed](#)]
15. Shimmura S, Tsubota K (2002) Ocular surface reconstruction update. *Curr Opin Ophthalmol* 13: 213-219. [[PubMed](#)]
16. Fatima A, Sangwan VS, Vemuganti GK (2006) Technique of cultivating limbal derived corneal epithelium on human amniotic membrane for clinical transplantation. *J Postgrad Med* 52: 257-261. [[PubMed](#)]
17. Meller D, Pires RT, Tseng SC (2002) Ex vivo preservation and expansion of human limbal epithelial stem cells on amniotic membrane cultures. *Br J Ophthalmol* 86: 463-471. [[PubMed](#)]
18. Sangwan VS, Fatima A, Vemuganti GK (2006) Clinical outcome of autologous cultivated limbal epithelium transplantation. *Indian J Ophthalmol* 54: 29-34. [[PubMed](#)]
19. Pauklin M, Steuhl KP, Meller D (2009) Characterization of the corneal surface in limbal stem cell deficiency and after transplantation of cultivated limbal epithelium. *Ophthalmology* 116: 1048-1056. [[PubMed](#)]
20. Lim MN, Umaphy T, Baharuddin PJN, Zubaidah Z (2011) Characterization and safety assessment of bioengineered limbal epithelium. *Med J Malaysia* 66: 335-341. [[PubMed](#)]
21. Scanlon PH, Foy C, Chen FK (2008) Visual acuity measurement and ocular co-morbidity in diabetic retinopathy screening. *Br J Ophthalmol* 92: 775-778. [[PubMed](#)]
22. Koizumi N, Inatomi T, Suzuki K, Sotozono C, Kinoshita S (2001) Cultivated corneal epithelial stem cell transplantation in ocular surface disorders. *Ophthalmology* 108: 1569-1574. [[PubMed](#)]
23. Gruterich M, Espana EM, Tseng SC (2003) Modulation of keratin and connexin expression in limbal epithelium expanded on denuded amniotic membrane with and without a 3T3 fibroblast feeder layer. *Invest Ophthalmol Vis Sci* 44: 4230-4236. [[PubMed](#)]
24. Hao Y, Ma DH, Hwang DG, Kim WS, Zhang F (2000) Identification of antiangiogenic and antiinflammatory proteins in human amniotic membrane. *Cornea* 19: 348-352. [[PubMed](#)]
25. Rama P, Bonini S, Lambiase A, Golisano O, Paterna P, et al. (2001) Autologous fibrin-cultured limbal stem cells permanently restore the corneal surface of patients with total limbal stem cell deficiency. *Transplantation* 72: 1478-1485. [[PubMed](#)]
26. Di Girolamo N, Bosch M, Zamora K, Coroneo MT, Wakefield D, et al. (2009) A contact lens-based technique for expansion and transplantation of autologous epithelial progenitors for ocular surface reconstruction. *Transplantation* 87: 1571-1578. [[PubMed](#)]
27. Feng Y, Borrelli M, Reichl S, Schrader S, Geerling G (2014) Review of alternative carrier materials for ocular surface reconstruction. *Curr Eye Res* 39: 541-552. [[PubMed](#)]
28. Pellegrini G, Rama P, Di Rocco A, Panaras A, De Luca M (2014) Concise review: hurdles in a successful example of limbal stem cell-based regenerative medicine. *Stem Cells* 32: 26-34. [[PubMed](#)]
29. Prabhasawat P, Ekpo P, Uprasertkul M, Chotikavanich S, Tesavibul N (2012) Efficacy of cultivated corneal epithelial stem cells for ocular surface reconstruction. *Clin Ophthalmol* 6: 1483-1492. [[PubMed](#)]
30. Espana EM, Di Pascuale MA, He H, Kawakita T, Raju VK, et al. (2004) Characterization of corneal pannus removed from patients with total limbal stem cell deficiency. *Invest Ophthalmol Vis Sci* 45: 2961-2966. [[PubMed](#)]
31. Lim P, Fuchsluger TA, Jurkunas UV (2009) Limbal stem cell deficiency and corneal neovascularization. *Semin Ophthalmol* 24: 139-148. [[PubMed](#)]
32. Shimazaki J, Higa K, Morito F, Dogru M, Kawakita T, et al. (2007) Factors influencing outcomes in cultivated limbal epithelial transplantation for chronic cicatricial ocular surface disorders. *Am J Ophthalmol* 143: 945-953. [[PubMed](#)]
33. Shimazaki J, Aiba M, Goto E, Kato N, Shimmura S, et al. (2002) Transplantation of human limbal epithelium cultivated on amniotic membrane for the treatment of severe ocular surface disorder. *Ophthalmol* 109: 1285-1290. [[PubMed](#)]
34. Sangwan VS, Basu S, MacNeil S, Balasubramanian D (2012) Simple limbal epithelial transplantation (SLET): a novel surgical technique for the treatment of unilateral limbal stem cell deficiency. *Br J Ophthalmol* 96: 931-934. [[PubMed](#)]