

## Clinical Case of Artesunate Resistant *Plasmodium falciparum* Malaria in Kolkata: A First Report

Bhattacharyya N<sup>1</sup>, Mukherjee H<sup>2</sup>, Bose D<sup>3</sup>, Roy S<sup>4</sup>, Das S<sup>4</sup>, Tripathy S<sup>4</sup> and Hati AK<sup>5\*</sup>

<sup>1</sup>Division of Virology and Medical Entomology, Calcutta School of Tropical Medicine, Kolkata, India

<sup>2</sup>Medical Entomology, Calcutta School of Tropical Medicine, Kolkata, India

<sup>3</sup>Department of Pathology Calcutta Medical College, Kolkata, India

<sup>4</sup>Immunology and Microbiology Laboratory, Department of Human Physiology with Community Health, Vidyasagar University, Midnapore, India

<sup>5</sup>Department of Medical Entomology, Division of Parasitology, Calcutta School of Tropical Medicine, Kolkata, India

### Abstract

The World Health Organization has urged to set up artemisinin-based combination therapy (artemisinin and effective antimalarial drug) and gradually pull out oral artemisinin mono-therapies from the making of prescription due to their high recrudescence rates and to reduce the risk of drug resistance. Prescription practices by physicians and the availability of oral artemisinin monotherapies with pharmacists directly affect the pattern of their use as a result the first clinical case report of only artesunate resistant *P. falciparum* malaria has been found from Kolkata. A significant failure rate of artesunate and SP (9.5%) has recently been observed in the district Jalpaiguri, West Bengal, though no specific mutation has been observed in p<sub>ATPase6</sub> gene. In view of the above findings to get a clear picture of artemisinin resistance in *P. falciparum* a thorough study is required involving *in vivo*, *in vitro* and molecular procedures in this vulnerable area.

**Keywords:** Malaria; *Plasmodium falciparum*; Artesunate; ACT; Drug resistant

### Introduction

The World Health Organization (WHO) recommends the use of artemisinin derivatives only in combination with efficient partner drugs against *Plasmodium falciparum* malaria to make sure high cure rates and postponement resistance. Artemisinins produce rapid therapeutic response, reduce gametocyte carriage, and are well tolerated by patients [1]. The five formulations of Artemisinin Combination Therapy (ACT) are artemether+lumefantrine, artesunate+mefloquine, artesunate+amodiaquine, artesunate+sulphadoxine-pyrimethamine and dihydroartemisinin+piperazine [2]. The ACT was introduced by the National Vector Borne Disease Control Programme (NVBDCP) as the first-line treatment of falciparum malaria in 117 districts which represented more than 90% of the reported *P. falciparum* cases [3]. Presently all formulations of ACT recommended by WHO, except dihydroartemisinin+piperazine, are registered with the Drug Controller General of India to treat the patient as well as to overcome the resistant property of *P. falciparum*.

Now, the success of a new treatment policy is dependent on the adherence of health providers to the guideline and the compliance of patients with the recommended treatment. Equally, information on current provider and patient practices is needed to inform and improve future treatment policy [4]. But our recent report suggests the inappropriate treatment practices continue in spite of the availability of evidenced-based guidelines.

### Case Report

This report stated an *in vivo* artesunate resistant *Plasmodium falciparum* case in Kolkata, capital of West Bengal (Figure 1). A female patient (SL), 57 years of age, was a resident of central Kolkata, West Bengal, India. The patient was suffering from fever with chill and rigor on alternate days from 20<sup>th</sup> October, 2012. She examined her blood on 26.10.2012 following the advice of her local physician for malaria parasite and dual antigen (PF/PV HRP2 / LDH) tests in

the Gautam Laboratories, 9A, K K Tagore street, Kolkata 700007. Both thick (Giemsa stained) and thin (Leishman stained) films of the patient were observed. Malaria antigens were tested applying malaria antigen

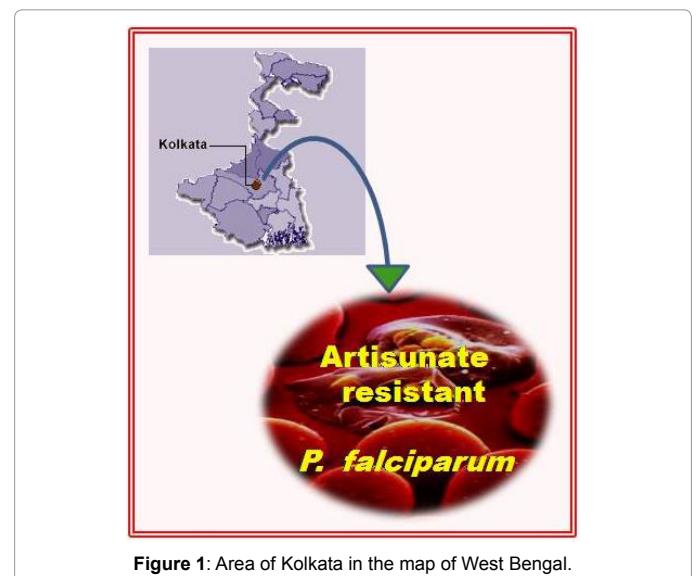


Figure 1: Area of Kolkata in the map of West Bengal.

\*Corresponding author: Amiya Kumar Hati, Department of Medical Entomology, Division of Parasitology, Calcutta School of Tropical Medicine, Kolkata, India, Tel: 03325773409; Fax: 9103222-275329; E-mail: akhati2012@gmail.com

Received December 16, 2013; Accepted January 04, 2014; Published January 07, 2014

**Citation:** Bhattacharyya N, Mukherjee H, Bose D, Roy S, Das S, et al. (2014) Clinical Case of Artesunate Resistant *Plasmodium falciparum* Malaria in Kolkata: A First Report. J Trop Dis 2: 128. doi: 10.4172/2329-891X.1000128

**Copyright:** © 2014 Bhattacharyya N, et al. This is an open-access article distributed under the terms of the Creative Commons Attribution License, which permits unrestricted use, distribution, and reproduction in any medium, provided the original author and source are credited.

rapid diagnostic test kit of MicroGene Diagnostic systems (P) Ltd., (web: [www.microgenediagnostic.com](http://www.microgenediagnostic.com), following the instructions of the company).

Microscopic observation suggested the presence of *P. falciparum* rings in her blood and *P. falciparum* antigen was also detected. Then she was treated by her physician with artesunate (Falcigo) injection alone, 120 mg i.m. on the first day (26.10.12) followed by 60mg i.m. daily for the next four days. She became a febrile on and from 28.10.2012. Her blood was tested on 6.11.2012, when no malaria parasite was found.

But, on 19<sup>th</sup> November, 2012, the patient was attacked by fever. Again her blood was examined on 20.11.12. *P. falciparum* rings were present and falciparum antigen was also found to be positive. In this time the membrane surface protein test suggests that the patient was recurrence of infection and not the re-infection. This time she was treated with six tablets of artemether 80 mg and lumefantrine 480 mg (Lumether forte DT) from 20.11.2012 administered orally at 0, 6, 24, 36, 48 and 60 hr. She became a febrile from 21.11.2012 and her blood was examined on 21.11.2012, 22.11.2012, 23.11.2012, 29.11.2012, 13.12.2012 and 25.12.2012 and in all the occasions malaria parasite was not found in her blood. She had no history of movement to neighboring countries in recent years.

These results demonstrated that the patient was clinically resistant to artesunate. It was a late treatment failure case. However, the combined therapy (artemether and lumefantrine) was effective in her case, as though the exact protocol was not maintained, in her blood no malaria parasite was found on day 7, 21 and 36, after completion of her treatment with artemether and lumefantrine combined therapy.

## Discussion

This is the first clinical case report of only artesunate resistant *P. falciparum* malaria from Kolkata. Though the present national drug policy is ACT (artemisinin and SP) [5] that has not been followed in this particular case. It is possible that such practices are continuing even with ACT. A significant failure rate of artesunate and SP (9.5%) has

recently been observed in the district Jalpaiguri, West Bengal, though no specific mutation has been observed in *pfATPase6* gene [6]. In view of the above findings to get a clear picture of artemisinin resistance in *P. falciparum* a thorough study is required involving *in vivo*, *in vitro* and molecular procedures in this vulnerable area. Rationality of inclusion of SP in ACT also raises a serious question as among isolates from Kolkata most common mutations in *dhfr* gene (responsible for pyrimethamine resistance) are at positions 108 and 51. The mutation is also found in C59R [7]. Again, in Kolkata 36.67% of isolates contains quadruple *dhps* AGEAT mutation (436+437+540+613), responsible for sulphadoxine resistance [8]. This case suggests that combination therapy effective as well as artesunate and lumefantrine in such cases is more practicable and efficacious than any other combination.

## References

1. Valecha N, Joshi H, Mallick PK, Sharma SK, Kumar A, et al. (2009) Low efficacy of chloroquine: time to switchover to artemisinin-based combination therapy for falciparum malaria in India. *Acta Trop* 111: 21-28.
2. World Health Organization (2010) Guidelines for the treatment of malaria, second edition.
3. National Vector Borne Disease Control Programme. Directorate General of Health Services Ministry of Health & Family Welfare.
4. Wasunna B, Zurovac D, Goodman CA, Snow RW (2008) Why don't health workers prescribe ACT? a qualitative study of factors affecting the prescription of artemether-lumefantrine. *Malar J* 7:29.
5. Guideline for diagnosis and treatment of malaria in India (2009) Government of India.
6. Saha P, Guha SK, Das S, Mullick S, Ganguly S, et al. (2012) Comparative efficacy of artemisinin combination therapies (ACTs) in *P. falciparum* malaria and polymorphism of *pf.ATPase 6*, *pfacr. pfdhfr* and *pf dhps* genes in tea gardens of Jalpaiguri district, India. *Antimicrob. agents and Chemother* 56: 2511-2517.
7. Das S, Chakraborty SP, Tripathy S, Hati AK, Roy S (2012) Association between prevalence of pyrimethamine resistance and double mutation in *pf dhfr* gene in West Bengal, India. *Asian Pacific J Trop Dis* 5: 31-35.
8. Das S, Chakraborty SP, Tripathy S, Hati A, Roy S (2012) Novel quadruple mutations in dihydropteroate synthase genes of *Plasmodium falciparum* in West Bengal, India. *Trop Med Int Health* 17: 1329-1334.