

Chemopreventive Effect of Methanol Extract of *Anacardium Occidentale* Nut Shell on Ultra-Violet Radiation Induced Skin Damage

Pepple NM¹, Ekoriko WU¹, Idih FM^{2*}, Chidozie VO¹

¹Salem University Lokoja, P.M.B 1060, Kogi State, Nigeria; ²Kogi State University, P.M.B 1008, Anyigba, Kogi State, Nigeria

ABSTRACT

Anacardium occidentale nut shell liquid which is mostly known as cashew nut shell liquid has been used for decades especially by natives of South America, Asia and Africa in the treatment of topical skin diseases, skin abrasion and cancerous ulcers amongst others. Some previous studies attempted to link pharmacological activities to the antibacterial, antioxidant and anti-proliferative properties of CNSL. Chronic exposure to sunlight can lead to skin damages including erythema, edema, hyperplasia, formation of sunburn cells, photoaging, suppression of the immune system and skin cancer. This study was aimed at evaluating the effect of methanol extract of *Anacardium occidentale* nut shell liquid on UV induced skin damage and cancer initiation. Gas chromatography and mass spectroscopic analysis was carried out on the extract. Skin damage was induced by exposing the hairless part of the experimental animals (albino rats) directly to UVR for 42 days alongside treatment with methanol extract of cashew nut shell following the experimental design. Percentage weight gain, relative organ weight, lipid peroxidation and histological studies were carried out to evaluate the impact of the UVR exposure and the chemo preventive effect of the extract. The methanol extract of CNS as determined by GC-MS analysis contains 1,2,3-Benzenetriol and benzofuran. A normal skin tissue and hepatocyte was observed in the normal control, severe wrinkling of skin epithelium with actinic keratosis of the dermal collagen and marked venous congestion in the liver of the negative control and complete recovery in the group treated with 300 mg/kg of the extract was observed. Marked serboheic keratosis and venous congestion in the liver was seen in the untreated groups. This study suggest that the administration of methanol extract of CNS exhibited a chemo preventive effect against skin damage which could lead to cancer initiation stage resulting from ultraviolet radiation by preventing its detrimental impact on the epidermis which could in turn lead to DNA damage and subsequently skin cancer initiation. 1,2,3-Benzenetriol and benzofuran which according to previous studies, exhibits anticancer, antioxidant and antibacterial activity were present in the extract, these compounds amongst others are believed to be responsible for the pharmacological activities observed in the study.

Keywords: Alcoholism, Dietary intake, Structural equation modelling

Abbreviations: CNSL: Cashew Nut Shell Liquid; CNS: Cashew Nut Shell; UVR: Ultra-Violet Radiation; GC-MS: Gas Chromatography Mass Spectroscopy

INTRODUCTION

Cashew (*Anacardium occidentale* L.) is a widely plant in South America, Africa and Asia mostly for nutritional and commercial purposes. Various parts of *Anacardium occidentale* have been reported to be traditionally used across the world in the treatment of various diseases [1]. Cashew nut shell liquid (CNSL), a reddish brown viscous liquid extracted from the pericarp of the cashew nut which is mostly a byproduct of industrial processing of cashew nut has various medicinal uses [2]. The major constituents of CNSL include anacardic acid, cardol, cardanol and methyl cardol. Based on the method of extraction, the ratio of these components varies.

Cashew nut shell liquid is used in folk medicine by some natives in treating soles of feet abrasion, topical infections and also cancerous ulcers [3].

Chronic exposure to ultra-violet radiation (UVR) from sunlight can result to skin damages which may include erythema, edema, hyperplasia, formation of sunburn cells, photoaging, suppression of the immune system and skin cancer, with these effects it could be said that UVR is doubly involved in the development of skin cancer through the induction of genetic alterations in keratinocytes leading to their neoplastic transformation and by the depression of the skin normal immune responses [4].

Correspondence to: Favour Idih, Kogi State University, P.M.B 1008, Anyigba, Kogi State, Nigeria, Tel: +2348143308906; E-mail: idihfavour@gmail.com

Received: January 18, 2020; **Accepted:** May 04, 2020; **Published:** May 11, 2020

Citation: Pepple NM, Ekoriko WU, Idih FM, Chidozie VO. Chemopreventive Effect of Methanol Extract of *Anacardium Occidentale* Nut Shell on Ultra-Violet Radiation Induced Skin Damage. J Clin Exp Pharmacol 10: 266. doi: 10.35248/2161-1459.20.10.266

Copyright: © 2020 Pepple NM, et al. This is an open-access article distributed under the terms of the Creative Commons Attribution License, which permits unrestricted use, distribution, and reproduction in any medium, provided the original author and source are credited.

Skin cancer is the most common form of cancer, accounting for nothing less than least 40% of cases globally. The most common type is non-melanoma skin cancer, which affects about 2-3 million people per year [5,6].

There are primary and secondary methods involved cancer prevention. The primary method is aimed at keeping the carcinogenic process from beginning; the Secondary prevention method is through the discovery of cancerous or precancerous conditions in their very early stage [7].

This research was designed to evaluate the effect of methanol extract of *Anacardium occidentale* (cashew) nut shell liquid on UV induced skin damage and cancer initiation.

MATERIALS AND METHODS

Collection of plant sample

Anacardium occidentale seeds were gotten from Salem University Lokoja, Kogi State, Nigeria and identified in the Department of Plant Science and Biotechnology of Kogi State University, Anyigba with voucher number (023). The nut shell of *Anacardium occidentale* were washed in cold water, the nut that floated were taken out and the nut that did not were air dried. The kernel were shelled from the nut, the shells were then cut into smaller sizes and blended using an electric blender.

Soxhlet extraction

Extraction of *Anacardium occidentale* shell was extracted using soxhlet extraction method, with methanol, hexane and isopropyl as solvent. The sample to be extracted was weighed to a tibble and loaded into the chamber of the soxhlet extractor, 150 ml of the solvent was poured into a different chamber attached to the soxhlet extractor enough to siphon at least twice into the flask, the temperature was set to 75°C and heated at reflux. This cycle was repeated over and over again over six hours using the three different solvents one after the other. The extract were dried at room temperature and stored at 4°C for further usage.

Experimental animals

Thirty five (35) albino rats (males) with average weight of 196 g were bought from the animal house section of Salem University Lokoja, Kogi State. The animals were acclimatized in the experimental room for few days.

Gas chromatography mass spectrophotometry (GC-MS)

GC-MS analysis of the ethanol extract of *P. chinense* was performed using a Perkin-Elmer GC Clarus 500 system comprising an AOC-20i auto-sampler and a Gas Chromatograph interfaced to a Mass Spectrometer (GC-MS) equipped with an Elite-5MS (5% diphenyl/95% dimethyl poly siloxane) fused a capillary column (30 × 0.25 µm ID × 0.25 µm df). For GC-MS detection, an electron ionization system was operated in electron impact mode with an ionization energy of 70 eV. Helium gas (99.999%) was used as a carrier gas at a constant flow rate of 1 ml/min, and an injection volume of 2 µl was employed (a split ratio of 25:1). The injector temperature was maintained at 250 °C, the ion-source temperature was 200 °C, the oven temperature was programmed from 60 °C (isothermal for 2 min), with an increase of 30 °C/min to 120°C, ending with a 3 min isothermal at 290 °C. Mass spectra were taken at 70 eV; a scan interval of 0.5 s and fragments from 45 to 700 Da. The solvent delay was 0 to 2 min, and the total GC/MS running time was 21 min.

Animal study

UV induced skin damage and cancer initiation: The experimental animals (30) were weighed, shaved of the fur on their back and divided into six (6) groups according to the experimental design below. The induction was done according to a modified method by Wang et al., 1992. The rats were exposed to UVR (180 mJ/cm² daily) for 42 days.

Experimental design

- Group 1- Normal Control
- Group 2- Negative control (exposed but untreated)
- Group 3- 100 mg/kg methanol extract
- Group 4- 300 mg/kg methanol extract
- Group 5- 500 mg/kg methanol extract
- Group 6- normal + 500 mg/kg methanol extract.

Treatment of experimental animals

The experimental animals were treated alongside with the induction process following the details of their grouping above. The treatments of the animals were done physically by applying the extract on their shaved skin 5 minutes after exposure to the UV. At the end of the treatment, they were starved for 12 hours, weighed and anesthetized and sacrificed.

Collection of organs

The vital organs (heart, spleen, liver, lungs and kidney) of the animals were collected and weighed.

Preparation of serum sample

Blood were collected into sample bottles and was centrifuged at 3000 RPM (using a micro field centrifuge) for 15 minutes. The serum were decanted into a different sample bottle and was stored in the freezer for further analysis.

Preparation of tissue homogenate

The organs collected from each animal were rinsed in normal saline and homogenized in ice cold buffer with pH 7.4 using a homogenizer. The homogenates were centrifuged at 3000 PRM for 15 minutes and the supernatant were collected.

Protein determination

Four hundred and fifty (450) micro liter of distilled water was pipetted into test tubes in duplicates and 50 µl of the sample was added after which 1.5 ml of biuret reagent was added. The absorbance was read at 540 nm using a spectrophotometer.

Lipid peroxidation

Two millimeter of thiobarbituric acid (TBA) and trichloro acetate (TCA) was added to 50 µl of the tissue homogenates respectively. The mixture was incubated for 30 minutes at 80°C. The test tubes were allowed to cool under ice and centrifuged at 3000 RPM for 15 minutes. The supernatant were measured using a spectrophotometer at a wave length of 535 nm.

Histological studies

The skin and liver tissues of the experimental animals were stored respectively in 10% formalin for 24 hours. The formalin fixed specimens were embedded in paraffin and section (3-5 µm) and stained with haematoxylin and eosin dye. The histological sections were evaluated by light microscopy.

RESULTS

Gas chromatography mass spectroscopy (GC-MS)

Relative organ weight: The result (Figure 1) shows the effect of methanol extract of *Anacardium occidentale* Nut Shell on relative organ weight of the experimental animals. There was no significant ($p < 0.05$) decrease or increase in all the groups when compared to the normal and negative control.

Percentage weight gain: The result as shown in Figure 2 represents the effect of methanol extract of *Anacardium occidentale* Nut Shell on the percentage weight gain of the experimental animals. There was a significant ($p < 0.05$) decrease observed in all the groups when compared to the normal.

Peak#	R-Time	I-Time	F-Time	Area	Area%	Height	Height%	A/H	Mark	Name
1	9.557	9.517	9.600	127232	0.13	62497	0.12	2.04		Butanoic acid, hydroxy-, dimethyl ester
2	10.891	9.987	10.054	28473	0.09	48249	0.09	1.83		4-(2-oxo-4-oxo-7,8-dihydro-3,5-dihydroxy
3	10.781	10.733	10.892	206025	0.20	35913	0.07	5.57	MI	Hexanoic acid
4	11.758	11.642	11.709	707839	0.70	10252	0.02	4.25		Hexanoic acid, 2,3-dihydro-5-hydroxy-
5	11.171	13.125	13.325	1332714	1.33	281508	0.54	4.73		1,2,3-Hexanetriol
6	13.900	13.833	14.000	926360	0.95	172909	0.33	5.23	V	Adipic acid, 7-phenylbutanoic acid
7	14.443	14.375	14.467	310136	0.31	132282	0.25	2.38		11-(2-cyclopent-1-yl)undecanoic acid, (+-
8	14.807	14.883	14.800	122040	0.12	70073	0.15	1.56	V	11-(2-cyclopent-1-yl)undecanoic acid, (+-
9	18.257	15.233	15.202	252116	0.25	160527	0.30	1.57	V	4-(4-Ethoxycyclohex-2-en-1-yl)
10	18.875	15.900	15.900	1164308	1.16	203209	0.75	2.96	V	9-Octadecenoic acid (Z)-, 2-hydroxy-1-(hyd
11	19.936	15.900	16.025	1947055	1.94	330201	1.00	3.67	V	Cyclopropanecarboxylic acid, methyl ester
12	16.332	16.208	16.256	140133	0.14	117619	0.22	1.19	V	9-Octadecenoic acid (Z)-, 2-(trimethylsilyloxy)
13	16.616	16.542	16.717	730709	0.73	137481	0.26	5.31	V	9,12,13-Octadecatrienoic acid, 2-(trimethylsilyloxy)
14	17.361	17.276	17.383	627448	0.62	106060	0.36	2.24	V	Cyclopropanecarboxylic acid, methyl ester
15	17.425	17.383	17.506	964487	0.96	183964	0.58	2.12	V	8,11,14-Eicosatrienoic acid, (Z,Z,Z)-
16	17.570	17.500	17.667	7748256	7.71	3472832	6.38	2.19	V	9,12,13-Octadecatrienoic acid, methyl ester
17	17.605	17.625	17.625	1031750	1.03	97989	0.74	1.12	MI	7-(10-Hexadecenoic acid, methyl ester)
18	17.708	17.667	17.742	4724635	4.70	4404465	7.58	1.18	V	Hexadecanoic acid, methyl ester
19	17.875	17.825	17.875	3147955	3.13	140305	0.87	3.20	V	8,11,14-Eicosatrienoic acid, (Z,Z,Z)-
20	17.950	17.938	18.050	3374411	3.36	140303	2.66	2.41	V	n-Hexadecanoic acid
21	18.374	18.307	18.400	689071	0.69	180160	0.36	3.66	V	Cyclopropanecarboxylic acid, 2-[[2-[[2-(2-pe
22	18.819	18.792	18.825	2719375	2.70	1003782	3.61	1.43	MI	Phenol, 3-para-acyl-
23	18.838	18.825	18.900	1909185	1.90	2011128	0.36	0.99	MI	9,12-Octadecadienoic acid, methyl ester
24	18.873	18.838	18.950	18006295	17.91	6636575	12.58	2.71	V	9-Octadecenoic acid (Z)-, methyl ester
25	18.901	18.925	19.025	1967311	1.95	1091145	3.75	0.99	MI	9-Octadecenoic acid, methyl ester, (Z)-
26	19.009	18.950	19.050	2429397	2.42	1070813	3.73	1.23	V	Methyl stearate
27	19.120	19.050	19.150	2941000	2.92	304540	0.90	5.82	V	17-Octadecenoic acid
28	19.425	19.425	19.425	1588365	1.58	1091137	0.75	2.81	V	Hexyl 2,2,4,4-tetramethyl-3-butenoate
29	19.969	19.925	20.017	560605	0.56	261488	0.59	2.14	V	Hexyl 2,2,4,4-tetramethyl-3-butenoate
30	20.046	20.017	20.067	1586382	1.58	1819545	1.92	1.56	V	Phenol, 3-para-acyl-
31	20.105	20.067	20.192	33146700	32.96	20608756	39.05	1.61	V	Phenol, 3-para-acyl-
32	20.674	20.600	20.708	2029712	2.02	992380	1.88	2.04	V	Phenol, 3-para-acyl-
33	20.751	20.708	20.817	1478404	1.47	58476	1.06	2.65	V	Phenol, 3-para-acyl-

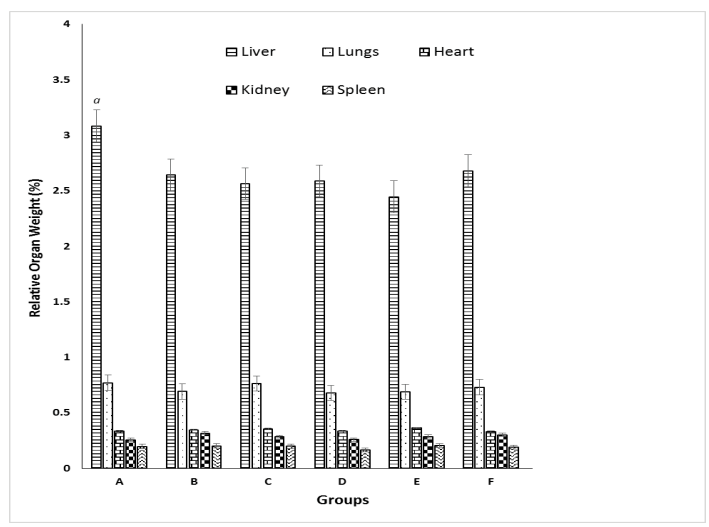


Figure 1: The Effect of Methanol Extract of *Anacardium occidentale* Nut Shell on Relative Organ Weight of the Experimental Animals. ^aSignificant ($p < 0.05$) difference between the normal control and other groups. ^bSignificant ($p < 0.05$) difference between the negative control and other groups.

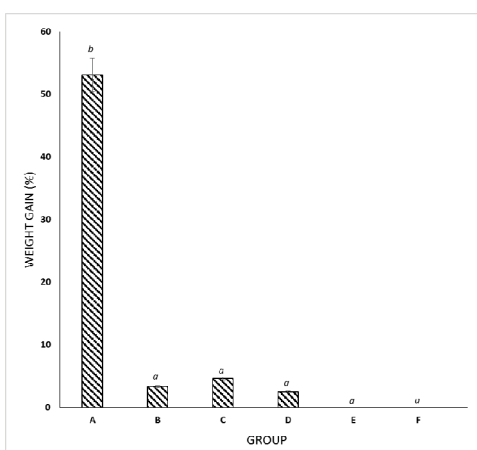


Figure 2: The Effect of Methanol Extract of *Anacardium occidentale* Nut Shell on the Percentage Weight Gain of the Experimental Animals. ^aSignificant ($p < 0.05$) difference between the normal control and other groups. ^bSignificant ($p < 0.05$) difference between the negative control and other groups.

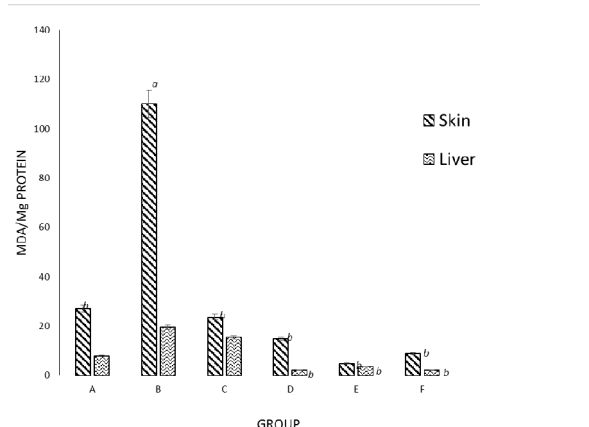


Figure 3: The Effect of Methanol Extract of *Anacardium occidentale* Nut Shell on the Lipid Peroxidation in the Experimental Animals. ^aSignificant ($p < 0.05$) difference between the normal control and other groups. ^bSignificant ($p < 0.05$) difference between the negative control and other groups.

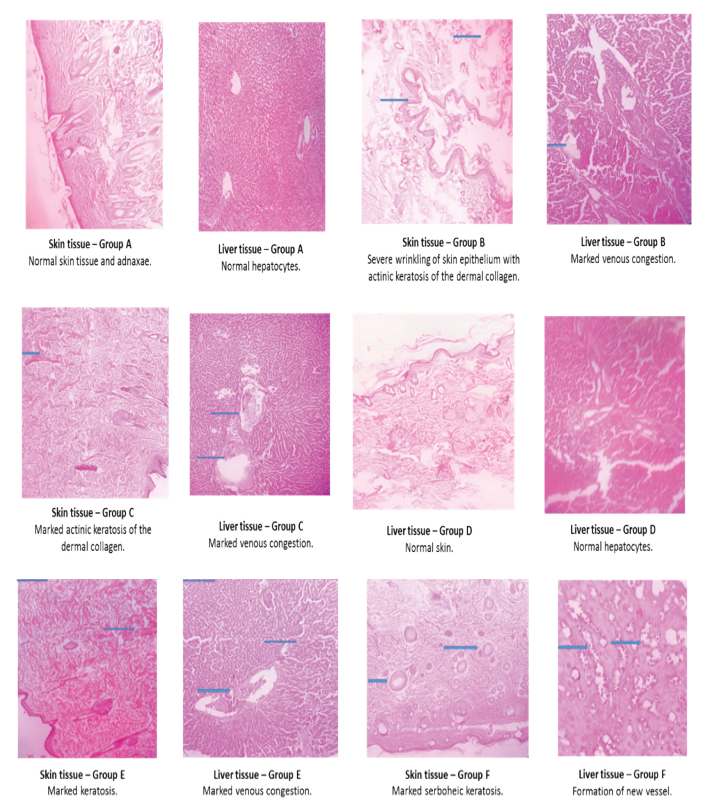


Figure 4: Representative Photomicrograph (X100 Magnification) of the Skin and Liver Tissue of the Experimental Animals.

Lipid peroxidation: The result as shown (Figure 3) represents the effect of methanol extract of *Anacardium occidentale* Nut Shell on the lipid peroxidation in the experimental animals. There was a significant ($p < 0.005$) decrease between the negative control and all other groups except the group treated with the lowest dose (100 mg/kg) of the extract.

Histological studies: The result in Figure 4 is a representative photomicrograph (x100 Magnification) of the skin and liver tissue of the experimental animals. A normal skin tissue and hepatocyte was observed in the normal control, severe wrinkling of skin epithelium with actinic keratosis of the dermal collagen and marked venous congestion in the liver of the negative control was observed. Complete recovery was observed in the group treated with 300 mg/kg of the extract.

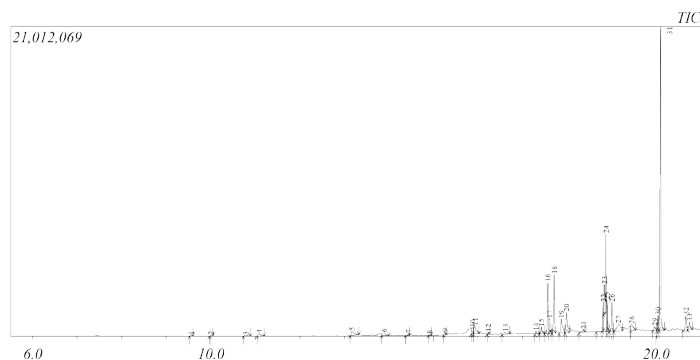


Figure 5: The GM-MS Spectra and List of Compounds in Methanol Extract of *Anacardium Occidentale* Nut Shell.

DISCUSSION

Skin cancer is the most common form of cancer, accounting for nothing less than least 40% of cases globally. The most common type is non-melanoma skin cancer, which affects about 2-3 million people per year [5,6].

Plant-based and traditional medicine systems will continue to play essential roles in health care, with about 80% of the world's inhabitants relying mainly on traditional medicines for their primary health care [8,9]. Cashew nut shell liquid is used in folk medicine by some natives in treating soles of feet abrasion, topical infections and also cancerous ulcers [3].

This study shows the compounds (Figure 5) present in the methanol extract of *Anacardium occidentale* nut shell as determined using gas chromatography mass spectroscopy (GC-MS). Some of this compounds possess pharmacological properties that could be responsible for the activity of the extract observed in this study. These include 1,2,3-Benzenetriol also known as pyrogallol and benzofuran which according a study [10-12] exhibited anticancer, antioxidant and antibacterial activity respectively amongst others.

There was no significant ($p < 0.05$) change observed in the relative organ weight of the treated groups when compared with the normal and negative control (Figure 1). This indicate the induction had little or no effect on the organ weight of experimental animals.

A significant ($p < 0.005$) decrease in MDA concentration was observed in the skin of all the groups when compared to the negative control, there was also a significant ($p < 0.005$) decrease between the negative control and all other groups except the group treated with the lowest dose (100 mg/ml) of the extract, this effect was also observed in the liver of the treated group. This shows the extract had effect against lipid peroxidation in the liver and skin of the treated animals.

The histological study revealed the extract was able to bring the skin and liver tissue of the treated animals to a normal state especially at 300 mg/kg where a complete recovery was observed as shown in Figure 1. A normal skin tissue and hepatocyte was observed in the normal control, severe wrinkling of skin epithelium with actinic keratosis of the dermal collagen and marked venous congestion in the liver of the negative control was observed.

According to a UV induced skin cancer model [13], UV penetration through the epidermis is the first step in the initiation of skin cancer and in this study the effect observed indicates that the extract exhibited a chemo preventive effect against skin cancer initiation stage resulting from ultraviolet radiation through the action of the bioactive compounds identified in the extract amongst others.

CONCLUSION

This study suggest that the administration of methanol extract of CNS exhibited a chemopreventive effect against skin damage which could lead to cancer initiation stage resulting from ultraviolet radiation by preventing its detrimental impact on the epidermis which could in turn lead to DNA damage and subsequently skin cancer initiation. 1,2,3-Benzenetriol and benzofuran which according to previous studies, exhibits anticancer, antioxidant and antibacterial activity were present in the extract, these compounds amongst others are believed to be responsible for the pharmacological activities observed in the study. However, further study will be done to isolate and evaluate the effect of this bioactive compounds respectively.

CONFLICT OF INTEREST

We wish to state that there are no known conflicts of interest associated with this publication and there has been no any significant financial support for this work that could have possibly influenced its outcome.

REFERENCES

- Iwu MM. Handbook of African Medicinal plants CRC press. Boca Raton, FL. 1993:183-184.
- Hamad FB, Mubofu EB. Potential biological applications of bio-based ancardic acids and their derivatives. International Journal of Molecular Sciences. 2015;16:8569-8590.
- Patel DK, Desai SN, Gandhi HP, Devkar RV, Ramachandran AV. Cardio protective effect of Coriandrum sativum L. on isoproterenol induced myocardial necrosis in rats. Food and Chemical Toxicology. 2012;50:3120-3125.
- Wang ZY, Huang MT, Ho CT, Chang R, Ma W, Ferraro T, et al. Inhibitory effect of green tea on the growth of established skin papillomas in mice. Cancer Research. 1992;52:6657-6665.
- Dubas LE, Ingraffea A. Nonmelanoma skin cancer. Facial Plastic Surgery Clinics. 2013;21:43-53.
- Harris RE. Epidemiology of chronic disease: global perspectives. Jones & Bartlett Learning. 2019.
- Spratt JS. The primary and secondary prevention of cancer. Journal of Surgical Oncology. 1981;18:219-230.
- Idih FM, Ighorodje-Monago CC, Ezim OE. Antiplasmodial effect of ethanol extract of Morinda lucida and Mucuna pruriens leaves on NK65 chloroquine resistant strain of Plasmodium berghei in mice. Clin Exp Pharmacol. 2017;7:2161-1459.
- Owolabi OJ, Omogbai EK, Obasuyi O. Antifungal and antibacterial activities of the ethanolic and aqueous extract of Kigelia africana (Bignoniaceae) stem bark. African J of Biotechnol. 2007;6.
- Chen ZP, Schell JB, Ho CT, Chen KY. Green tea epigallocatechin gallate shows a pronounced growth inhibitory effect on cancerous cells but not on their normal counterparts. Cancer Letters. 1998;129:173-179.
- Rice-Evans CA, Miller NJ, Paganga G. Structure-antioxidant activity relationships of flavonoids and phenolic acids. Free Radical Biology and Medicine. 1996;20:933-956.
- Rida SM, El-Hawash SA, Fahmy HT, Hazza AA, El-Meligy MM. Synthesis and in vitro evaluation of some novel benzofuran derivatives as potential anti-HIV-1, anticancer, and antimicrobial agents. Archives of Pharmacol Research. 2006;29:16.
- Leffell DJ, Brash DE. Sunlight and skin cancer. Scientific American. 1996;275:52-59.