

Can Uveitis on Behcet's Disease be Granulomatous

Mehdi Khamaily*, Imane Tarib, Yassine Mouzari, Joumany Brahim Salem, Taoufik Abdellaoui, Fouad El Asri, Karim Reda, Abdelbarre Oubaaz

Department of Ophthalmology, Mohammed V Military Teaching Hospital, Rabat, Morocco

ABSTRACT

Behcet's disease (BD) is a chronic multisystem disorder, characterized by relapsing inflammation, Ocular involvement is frequent (40%-70%), and all coats of the eye may be affected. The non-granulomatous character of uveitis is usually reported in BD.

We report a series of 11 cases of atypically granulomatous uveitis in patients with extra ocular signs of Behcet.

Keywords: Granulomatous uveitis; Behcet; Atypical

INTRODUCTION

Behcet's disease (BD) is a chronic multisystem disorder, characterized by relapsing inflammation for which the underlying histopathology is an occlusive vasculitis, and whose etiology is still poorly known [1]. The exact etiopathogenesis of the disease is still unclear, although genetic predisposition, environmental factors, and immunologic abnormalities have been considered [2].

It is classically characterized by recurrent oral aphthae (the main and the most recurrent symptom), genital ulcerations, variable skin lesions, uveitis, and peripheral arthritis. Ocular involvement is frequent (40%-70%), representing an important clinical criterion. Responsible for a serious attack, conditioning the visual prognosis. All coats of the eye may be affected. The non-granulomatous character of uveitis is usually reported in BD [3].

PURPOSE OF THE STUDY

The purpose of this study is to report for the first time cases of granulomatous uveitis noted in patients with BD.

PATIENTS AND METHODS

Retrospective study conducted between January 2010 and December 2019, at the Mohammed V Military Teaching Hospital. The diagnosis of BD was selected according to the international study group for Behcet disease (1990). Ocular involvement was defined by the presence of anterior, intermediate or posterior uveitis or pan-uveitis associated or not with a retinal vasculitis in the fundus of the eye or a retinal

angiography. An assessment has been carried out to eliminate any common cause of granulomatous uveitis: conversion enzyme, thoracic radio, TST (tuberculin skin test), infectious serologies, namely syphilitic and toxoplasmic, search for signs of Vogt Koyanagi Harada.

RESULTS

Among 277 cases of ocular involvement in BD, 11 cases of granulomatous uveitis were found. The sex ratio was 4.5, with an average age at diagnosis of 30 years and an average age at onset of ocular symptomatology of 36 years.

It was inaugurated in two patients. Associated with parenchymal neurological involvement in two cases and vascular involvement with deep vein thrombosis in one case. The pathergy test was positive in nine cases.

Ocular involvement was bilateral in nine patients. The ophthalmologic examination revealed:

Anterior uveitis in 2 patients.

A posterior uveitis in 4 patients.

Pan-uveitis in 5 patients.

Retinal vasculitis in 4 patients.

The granulomatous character was noted in the presence of ant eggs in six patients and mutton-fat precipitates behind Descemet's membrane in five patients.

Correspondence to: Khamayli M, Department of Ophthalmology, Mohammed V University, Rabat, Morocco, E-mail: mehdi.khamaily@gmail.com

Received date: July 02, 2020; **Accepted date:** July 15, 2020; **Published date:** July 22, 2020

Citation: Khamayli M, Tarib I, Mouzari Y, Salem JB, Abdellaoui T, Asri FE, et al. (2020) Treatment of the Refractory Glaucoma by the Micropulse Transcleral Diode Laser Cyclophotocoagulation. *J Eye Dis Disord* 5: 137. DOI: 10.35248/2684-1622.20.5.137

Copyright: © 2020 Khamayli M, et al. This is an open-access article distributed under the terms of the Creative Commons Attribution License, which permits unrestricted use, distribution, and reproduction in any medium, provided the original author and source are credited.

We report a case from our series, this is a patient admitted for a table of granulomatous uveitis (Figure 1) with extra ocular signs in favor of behcet's disease.

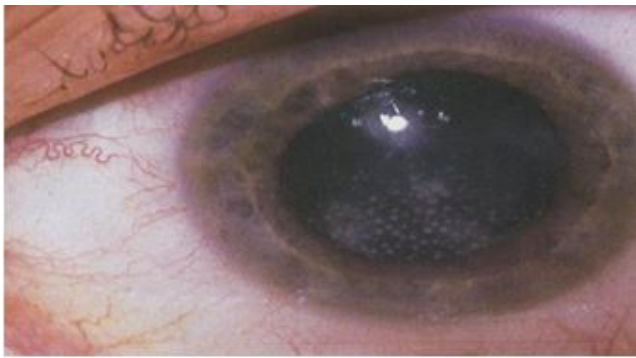


Figure 1: Atypical Granulomatous Uveitis in 37-year-old patient with Behcet's Disease.

From a therapeutic point of view, all patients underwent full-dose corticosteroid therapy. An immunosuppressant type cyclophosphamide by bolus was introduced in 9 patients, with a relay initiated in 8 patients by azathioprine. One of these patients was in addition treated with biotherapy (anti-TNF) due to severe ocular involvement. The average duration of follow-up was three years. A good response was noted in 64.4% (Figure 2).

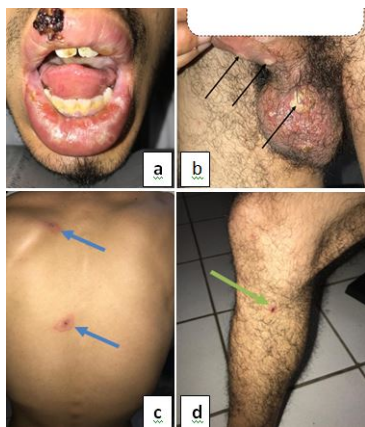

Figure 2: Extra ocular sign of Behcet's disease with atypical Granulomatous Uveitis in 37-year-old patient.

DISCUSSION

Ocular involvement in BD occurs in 67%-95% of cases. It is often bilateral (63 to 100% of cases) [4]. The first inflammatory

outbreaks are rather unilateral and anterior [5]. The recurrences will concern the posterior segment and become bilateral. Uveitis can be inaugural in 10 to 20% of cases, otherwise it appears 2 to 3 years after aphthous ulcers [6]. The ocular involvement in the BD is very rich and protean, it touches all the tunics of the eye [7]. Several types of ocular involvement have been described, but the granulomatous character did not appear in the previous studies.

This series reports for the first time cases of granulomatous uveitis in patients with BD on a sufficient number of criteria. This may lead to not excluding the possibility of BD in the presence of granulomatous uveitis if the clinical context is suggestive, and after eliminating the usual causes of granulomatous uveitis. However, further studies are needed to substantiate these findings.

CONCLUSION

Uveitis is the primary ocular involvement of Behcet's Disease.

It is a part of the diagnostic criteria for the disease.

Generally described as non-granulomatous.

First series having reported granulomatous uveitis in Behcet's disease, but a small series ...

In case of a suggestive clinical presentation, despite the granulomatous character of uveitis is suggestive, consider the possibility of Behcet's disease.

REFERENCES

1. Ksaa I. Eye and Behcet disease. *J Fr Ophtalmol.* 2019;42(6): 626-641.
2. Rokutanda R, Kishimoto M, Okada M. Update on the diagnosis and management of Behcet's disease. *Open Access Rheumatol.* 2014;30:1-8.
3. Z Hajji. *Encyclopedia Medico-Chirurgicale.* 2010;21-225.
4. Yohei K. Clinical and genetic Aspects of Behcet's disease in Japan. *Intern Med.* 2019;58(9):1199-1207.
5. Pleyer U. Anterior uveitis clinic Diagnostic procedure and treatment options. *KlinMonblAugenheilkd.* 2020.
6. Esatoglu SN. Update on the treatment of Behcet's syndrome. *Intern Emerg Med.* 2019;14:661-675.
7. Zhang j. A review of behcet's disease from perspectives of both western and chinese medicine. *J Tradit Chi Med.* 2019;39(1): 139-152.