

Axillobipopliteal Bypass in the Presence of Critical Limb-Threatening Ischemia

Edward Batzel, John Joseph Tolli*, Alison Migonis and Evan Ruppell

Geisinger Community Medical Center, USA

Abstract

Axillobipopliteal bypass is a very uncommon but sometimes necessary procedure as a final attempt at revascularization for limb salvage. We present a case of extensive bilateral arterial occlusion managed by artificial grafting, with the additional challenge of an inaccessible sub-clavian artery on the left side secondary to pacemaker implantation. The proposed staged bilateral axillopopliteal bypass was altered to supply both popliteal arteries utilizing the right sub-clavian artery alone. This procedure resulted in a restoration of blood flow, which continues to remain robust at more than three months post operatively.

Introduction

The goal of extra-anatomic bypass surgery is to achieve revascularization using remote subcutaneous pathways that can be performed with lower morbidity and mortality. This has been performed for complex vascular pathologies, including graft infection, claudication and rest pain and skin necrosis. Blaisdell and Hall introduced the axillofemoral bypass in 1963 [1]. Smith et al and Veith et al. [2,3] are credited with first describing the axillopopliteal bypass in the late 1970s. In 1989, Ascer et al. [4] reported a 5 year limb salvage rate of 58% following axillopopliteal bypass. However, a thorough literature search revealed only two publications regarding the axillobipopliteal bypass [5,6]. This report presents our case of the unique and inventive axillobipopliteal bypass.

Case Report

A 77 year-old male with complex co-morbidities, including diabetes mellitus, chronic obstructive pulmonary disease, chronic kidney disease, coronary artery disease, congestive heart failure, and pacemaker insertion for 3rd degree AV block was referred by his physician for a workup of ischemia and gangrenous pedal lesions. The patient was a heavy smoker who recently quit. Physical exam revealed severe rest pain with non-palpable femoral, popliteal, and pedal pulses bilaterally. There was also dry necrosis of the left hallux and anterior ankle, as well as his bilateral heels. Bilateral radial pulses were palpable. Non-invasive vascular studies revealed an Ankle-Brachial index of 0.09 and 0.4 on the left and right, respectively, with significant proximal and mid-level disease. Upon admission, he was optimized prior to angiography by cardiology, pulmonology, and nephrology. Angiography revealed

diffuse severe calcific disease without significant stenosis in the abdominal aorta and both common iliac arteries. The internal iliac arteries were patent. However, there was chronic total occlusion of bilateral external iliac, common femoral, superficial femoral, and above knee popliteal arteries with below knee reconstitution and two vessel infrapopliteal arterial outflow bilaterally via anterior tibial and peroneal arteries. Angiographic intervention was attempted by interventional radiology, however unsuccessful (Figure 1).

Following administration of general anesthesia, the patient's right neck, chest, abdomen, bilateral groins, and legs were prepared and draped. An incision was made in the right sub-clavicular area, where the axillary artery was then isolated circumferentially. An incision was made along the medial aspects of the left and right calves. After reflecting the gastrocnemius posteriorly, the neurovascular bundle was identified and popliteal arteries isolated. Nine counter incisions were made in total in the right chest wall, abdomen, and upper legs in order to tunnel the bypass grafts. The 8 mm Polytetrafluoroethylene (PTFE) axillobifemoral bypass graft was tunneled using these counter incisions. Prior to any clamping, 7500 units of heparin were given systemically, and 1000 units of heparin were given every hour. After heparinization, proximal and distal clamps were placed on the right axillosub-clavian artery. An arteriotomy was performed with anastomosis of the graft in end-to-end fashion using 5-0 GORE-TEX. The graft was flushed and clamped. The ends of the axillobifemoral graft were brought out through the proximal thigh since there weren't femoral arteries to anastomose the grafts to. A second PTFE graft, a PROPATEN 6 mm, was cut in half to provide the extra length necessary on each limb to extend to the below-knee popliteal artery. The left popliteal artery anastomosis was carried out first. The PTFE graft was cut to conform to the anastomosis and sutured in place using 6-0 GORE-TEX suture. All clamps were released and the graft was back-bled, flushed, and passed through the tunnel between the gastrocnemius heads and out the thigh

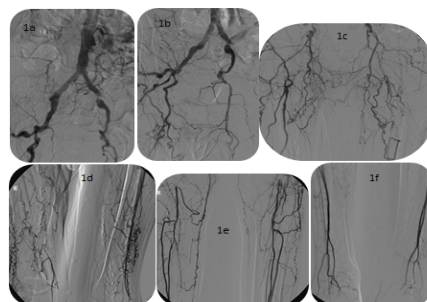


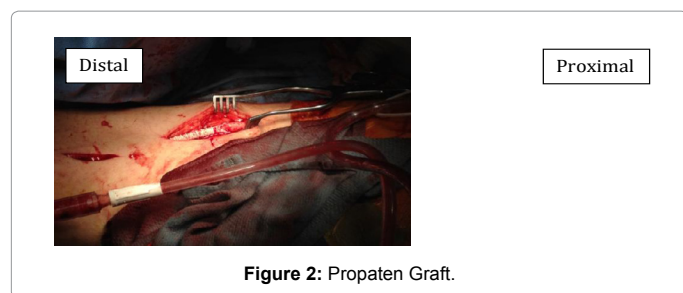
Figure 1: Angiographic Intervention.

*Corresponding author: John Joseph Tolli, Geisinger Community Medical Center, Scranton, Pennsylvania, USA, Tel: 9144944953; E-mail: jjtoll@geisinger.edu

Received June 11, 2014; Accepted August 14, 2014; Published August 16, 2014

Citation: Batzel E, Tolli JJ, Migonis A, Ruppell E (2014) Axillobipopliteal Bypass in the Presence of Critical Limb-Threatening Ischemia. J Vasc Med Surg 2: 149. doi: 10.4172/2329-6925.1000149

Copyright: © 2014 Batzel E, et al. This is an open-access article distributed under the terms of the Creative Commons Attribution License, which permits unrestricted use, distribution, and reproduction in any medium, provided the original author and source are credited.



incision in the upper limb. A graft-to-graft anastomosis was then made by grooming both ends of the graft in a spatulated fashion and sewing them together using 5-0 GORE-TEX suture. Defects in all suture line were repaired with 6-0 prolene. All clamps were released from the left leg, revealing excellent pulsatile flow into the dorsalispedis artery with palpable pulse. Attention was then directed to the right leg, where the same procedure was performed with the other half of the PROPATEN graft (Figure 2). Once the grafts were adequately sewn, all clamps were removed. Excellent pulsatile flow was present through both grafts, and bilateral dorsalispedis pulses were palpable. The heparin was reversed with 50 mg of protamine and the incisions were closed with 2-0 vicryl and staples. Postoperatively the patient was started on Plavix and aspirin, however after the first postoperative day Clopidogrel was discontinued and the patient began a heparin bridge to Coumadin.

Discussion

Peripheral arterial disease is a manifestation of generalized atherosclerosis in the non-cardiac vessels, affecting 12-20% of patients older than age 65 in the United States [7,8]. The iliac and femoral arteries are often affected in patients with symptomatic occlusive disease and since the early 1960's extra-anatomic bypass has been performed for arterial reconstruction [1].

Although conditions requiring an axillopopliteal graft technique are rare, and those requiring axillobipopliteal bypass even more infrequent, the technique is useful when other avenues for limb salvage have been exhausted, which was the circumstance in our case. Concern for graft infection provided quite an uneasy feeling considering the extent of material used, however we felt it was justifiable risk allowing restoration of arterial flow. Long grafts are a technical challenge, and unfortunately large cross-sectional studies on outcomes are few. Ascer et al. [4] performed one of the largest studies, of which he reported on a series of 55 axillopopliteal bypasses. They observed an extremity salvage rate of 83%, 68%, and 58% at the end of the first, third, and fifth postoperative years, respectively. Patency rates were 58%, 45%, and 40% within the same time frame. They also observed that 74% of sequential axillofemoro-popliteal grafts remained patent after three years, while straight grafts remained patent in only 42% of cases. Later, a 30 patient study by Keller et al. [9] refuted this result, as well as observed that angiographic runoff was not indicative of primary patency.

The rarity of the axillobipopliteal bypass is only exemplified by the lack of published literature. One case report by Gunay et al described a staged procedure in which an existing femoropopliteal graft was anastomosed in end-to-side technique to a new contralateral axillopopliteal graft [5]. This procedure first required embolectomy for massive thrombus of the femoropopliteal graft, but the completed system of spiral PTFE grafts remained patent for at least five weeks postoperatively [5]. Gunay et al. [5] additionally emphasized the use of anticoagulation postoperatively to ensure higher patency rates. We

agree that post-operative anticoagulation is paramount to graft patency and opted to transition from Clopidogrel to an indefinite course of Coumadin due to the magnitude of the graft.

In conclusion, the reported case differs from those previous in that both popliteal arteries below the knee were revascularized in a sole procedure from a single axillary artery origin. Originally, we had planned for a staged bilateral axillopopliteal bypass in which we would revascularize the left extremity first, as it was the most symptomatic. However, the positioning of the patient's pacemaker generator made conducting two axillopopliteal grafts impractical. The decision to graft to both extremities simultaneously rather than as a staged revascularization minimized a critically ill patient's anesthesia exposure and provided symptomatic relief to both extremities quickly. To date, the patient has had a rather uneventful postoperative course with complete alleviation of rest pain and no post-operative infections. The patient did require digital amputation of an unchanged gangrenous toe, which was present pre-operatively, but has healed. Although the necrotic areas of the heels have not completely resolved, they have improved significantly, and most importantly there are still strong palpable dorsalispedis pulses bilaterally. Use of a commercial femoropopliteal graft limited the amount of customization necessary. One graft-to-graft anastomosis on each end provided sufficient length to reach the popliteal artery. This new use of materials combined with established technique is a treatment option for advanced bilateral peripheral arterial disease not amenable to other interventions.

References

1. Blaisdell FW, Hall AD (1963) Axillary-femoral artery bypass for lower extremity ischemia. *Surgery* 54: 563-568.
2. Smith RB, Perdue GD, Hyatt HC, Ansley JD (1977) Management of the infected aortofemoral prosthesis including use of an axillo-popliteal bypass. *Am Surg* 73: 65-73.
3. Veith FJ, Moss CM, Daly V, Fell SC, Haimovici H (1978) New approaches to limb salvage by extended extra-anatomic bypasses and prosthetic reconstructions to foot arteries. *Surgery* 84: 764-774.
4. Ascer E, Veith FJ, Gupta S (1989) Axillopopliteal bypass grafting: indications, late results, and determinants of long-term patency. *J Vasc Surg* 10: 285-291.
5. Gunay C, Ucak A, Cingoz F, Bingol H, Kuralay E (2005) Axillo-bipopliteal bypass application in critical leg ischemia. *Kosuyulo Heart Journal* 9: 25-28.
6. Pluhackova H, Staffa R, Vlachovsky R, Novotny T, Dvorak M (2011) A rare case of a long-term patent axillobipopliteal bypass--a case report. *Rozhl Chir* 90: 575-578.
7. Harris L, Dryjski M (2014) Epidemiology, risk factors, and natural history of peripheral artery disease. *UpToDate*.
8. Roger VL, Go AS, Lloyd-Jones DM, Adams RJ, Berry JD, et al. (2011) Heart Disease and Stroke Statistics Update: A Report From the American Heart Association. *Circulation* 123: e18-e209.
9. Keller MP, Hoch JR, Harding AD, Nichols WK, Silver D (1992) Axillopopliteal bypass for limb salvage. *J Vasc Surg* 15: 817-822.