

## An Incidental Case of Auto-atticotomy

Mirza M<sup>1</sup>, Asadi H<sup>1,2\*</sup>, Brennan P<sup>1</sup>, O'Hare A<sup>1</sup>, Thornton J<sup>1</sup> and Looby S<sup>1</sup>

<sup>1</sup>Neuroradiology and Neurointerventional Service, Department of Radiology, Beaumont Hospital, Beaumont Rd, Beaumont, Dublin 9, Ireland

<sup>2</sup>School of Medicine, Faculty of Health, Deakin University, Pigdons Road, Waurn Ponds, Australia

### Abstract

In this article we present a case of incidental auto-atticotomy in a patient presenting with headache and otorrhea.

Auto-atticotomy also known as "Nature's atticotomy" is a phenomenon that occurs in very few patients who have a cholesteatoma, whereby spontaneous drainage occurs into the external auditory canal, resulting in an air filled cavity, which is in the shape of the original cholesteatoma. Our case study highlights that although rare, auto-atticotomy can be considered as a differential diagnosis in patient's presenting with headache and spontaneous otorrhea.

**Keywords:** Auto-atticotomy; Cholesteatoma; Neuroradiology

### Introduction

Cholesteatoma is a nonmalignant cyst like growth consisting of squamous epithelium that is located in the middle ear or mastoid air cells which can lead to the erosion of structures within the temporal bone [1-3]. This may then lead to central nervous system complications, which in turn may be potentially fatal [4-6].

The treatment depending on the age of the patient is usually a surgical excision known as atticotomy, whereby the scutum and the lower lateral wall of the attic are removed. In a minority of patients a spontaneous atticotomy may occur, called auto-atticotomy, where there is spontaneous drainage of the cholesteatoma into the external auditory canal [2].

Here we present a patient with an auto-atticotomy, who presented with headache and otorrhea.

### Case Report

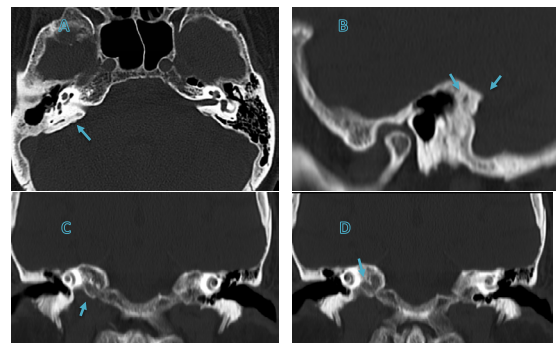
A 62-year-old woman presented with a 2 day history of constant headache with no history of preceding trauma. The patient had no significant past medical history or ongoing medication. On clinical examination, she had a painless right-sided otorrhea; otherwise, there were no abnormalities detected on her neurological or head and neck examination.

The patient underwent a non-contrast CT brain that showed extensive right mastoid air cell opacification and no other abnormality. This was further investigated with CT temporal bones (Figure 1), which demonstrated erosion of the right scutum and right lateral attic wall and some demineralisation of the right ossicles, with an enlarged air filled right aditus ad antrum, which communicated with the right middle ear cavity. There was marked retraction of the right tympanic membrane and no residual soft tissue abnormality was detected in the right middle ear cavity.

### Discussion

Cholesteatomata were first described by Duverney et al in 1683 in "Traité de l'Organe de l'Ouïe" as "Caries of the bone accompanied with bad smell and symptoms" [7]; and, in 1838, Müller et al were the first to introduce the term cholesteatoma [8,9].

However, the term cholesteatoma is a misnomer, as it neither contains cholesterol "chole" or fat "steat", and therefore over the years, other names have been proposed, such as "margaritoma" in 1891 by Graigie and "keratoma" in 1974 by Schuknecht, but none of these names were adopted, and cholesteatoma remained as the dominantly used term [10].



**Figure 1:** Non-contrast CT temporal bones (A – Axial: Expanded air filled cavity, without soft tissue opacification, in the mastoid temporal bone; B – Sagittal: Cavity expansion into the mastoid temporal bone and tegmen tympani attenuation; C & D – Coronal: Attenuated ossicles, scutum and tegmen tympani. Bony erosion of the lateral wall of the attic, with the air filled cavity extending into the mastoid temporal bone.).

Cholesteatoma is a relatively rare condition with an incidence of 3 and 9.2 per 100,000 population in children and adults respectively. There is a slight male predominance of 1.4:1, and a higher incidence of middle ear cholesteatomata occurring in patients younger than 50 years of age [11].

Macroscopically cholesteatomata appear as pearly grey structures with a thin membrane. Microscopically they are divided into three layers: cystic content, matrix and perimatrix. The cystic content is the primary component of the cholesteatoma that demonstrates fully differentiated anucleate keratin lined by stratified keratinizing squamous epithelium [12,13]. Once a cholesteatoma sac is formed, it starts accumulating keratin debris and grows in size with invasion and destruction of the surrounding structures, which depending on the age of the patient, extent of the disease and location, various surgical treatments should be performed to avoid the potential complications that may occur, such as meningitis or brain abscesses [14].

**\*Corresponding author:** Asadi Hamed, Department of Radiology, Interventional Radiology Service, Beaumont Hospital, Beaumont Rd, Beaumont, Dublin 9, Ireland, Tel: +353 1 809 3000; Fax: +353 1 809 837 6982; E-mail: [asadi.hamed@gmail.com](mailto:asadi.hamed@gmail.com)

Received October 06, 2015; Accepted October 13, 2015; Published October 18, 2015

**Citation:** Mirza M, Asadi H, Brennan P, O'Hare A, Thornton J, et al. (2015) An Incidental Case of Auto-atticotomy. J Gerontol Geriatr Res 4: 250. doi:10.4172/2167-7182.1000250

**Copyright:** © 2015 Mirza M, et al. This is an open-access article distributed under the terms of the Creative Commons Attribution License, which permits unrestricted use, distribution, and reproduction in any medium, provided the original author and source are credited.

	Initial Location	Pathogenesis
Pars flaccida (attic)	Epitympanum (Lateral to ossicles)	Congenital
		Primary acquired
		Secondary acquired
Pars tensa (sinus)	Mesotympanum (Medial to ossicles)	Congenital
		Secondary acquired

**Table 1:** Location based classification of middle ear cholesteatomata [11].

CT temporal bones are the imaging modality of choice for diagnosing cholesteatomata. Typical findings include an expansile soft-tissue lesion with associated retraction of the tympanic membrane. This in turn leads to blunting of the scutum and erosion of the ossicles [2]. MRI imaging with Diffusion Weighted Imaging (DWI) may also be performed in cases where tissue differentiation is helpful for diagnosis [15].

Cholesteatomata are classified as congenital or acquired depending on the disease pathogenesis. Congenital cholesteatomata, being specific to children have an incidence of 0.12 per 100,000 children [16,17], while acquired cholesteatomata which affects both children and adults is further subdivided into primary (80% of all middle ear cholesteatomata), and secondary cholesteatomata (18% of all middle ear cholesteatomata). On the other hand, the middle ear cholesteatomata are more commonly classified based on their location (Table 1) [11].

Congenital cholesteatomata are generally asymptomatic, behind an intact tympanic membrane [18] and are usually an incidental finding. As for primary acquired cholesteatomata, they also usually have an intact tympanic membrane, and are localised to the pars flaccida, and present with recurrent ear symptoms, such as conductive hearing loss, discharge and vertigo [19].

Secondary cholesteatomata, on the other hand are usually a result of surgical intervention, infections or trauma, and grow into the middle ear through a perforated tympanic membrane [20]. In advanced stages of congenital cholesteatomata, they may present with symptoms similar to acquired cholesteatomata.

Primary acquired cholesteatoma or retraction pocket cholesteatomata, most commonly forms in the Prussak's space lateral to the ossicles [2], with lateral expansion. This may result in erosion of the lower lateral wall of the attic and the scutum [21,22], resulting in spontaneous drainage into the external auditory canal known as auto-atticotomy, with an air filled cavity remaining, which reflects the dimensions of the cholesteatoma [2,23]. This bony destruction likely result from a combination of different mechanisms, mass effect of the growing cholesteatoma, cytokines secreted within the environment, and osteoclastic activity of the cholesteatoma [23]. The exact incidence of auto-atticotomy is unknown; however, it is considered quite rare with incidental cases likely being very uncommon.

## Conclusion

Cholesteatomata have been well described in the literature, however in our knowledge only a few cases of auto-atticotomy have been published. In patients with headache and spontaneous otorrhea, although a rare diagnosis, careful attention should be made to the temporal bones, as an auto-atticotomy may be the underlying diagnosis.

## References

- Swartz J, Hagiwara M, Som P, Curtin H (2011) Inflammatory disease of the temporal bone. *Head and Neck Imaging*. (5th edn), Mosby Inc, St Louis, MO.
- Manasawala M, Cunnane ME, Curtin HD, Moonis G (2014) Imaging findings in auto-atticotomy. *AJNR Am J Neuroradiol* 35: 182-185.
- Sadé J (1980) Retraction pockets and attic cholesteatomas. *Acta Otorhinolaryngol Belg* 34: 62-84.
- Prasad SC, Shin SH, Russo A, Di Trapani G, Sanna M (2013) Current trends in the management of the complications of chronic otitis media with cholesteatoma. *Curr Opin Otolaryngol Head Neck Surg* 21: 446-454.
- Migirov L, Yakirevitch A, Kronenberg J (2005) Mastoid subperiosteal abscess: a review of 51 cases. *Int J Pediatr Otorhinolaryngol* 69: 1529-1533.
- Maksimovic Z, Rukovanjski M (1993) Intracranial complications of cholesteatoma. *Acta Otorhinolaryngol Belg* 47: 33-36.
- Soldati D, Mudry A (2001) Knowledge about cholesteatoma, from the first description to the modern histopathology. *Otol Neurotol* 22: 723-730.
- Müller J (1838) *Über den feinen Bau und der Formen der Krankhaften Geschwülste*. G Reimer, Berlin, Germany.
- Dornelles C, Costa SS, Meurer L, Schweiger C (2005) Some considerations about acquired adult and pediatric cholesteatomas. *Braz J Otorhinolaryngol* 71: 536-545.
- Baráth K, Huber AM, Stämpfli P, Varga Z, Kollias S (2011) Neuroradiology of cholesteatomas. *AJNR Am J Neuroradiol* 32: 221-229.
- Kuo CL, Shiao AS, Yung M, Sakagami M, Sudhoff H, et al. (2015) Updates and knowledge gaps in cholesteatoma research. *Biomed Res Int* 2015: 854024.
- Ferlito A (1993) A review of the definition, terminology and pathology of aural cholesteatoma. *J Laryngol Otol* 107: 483-488.
- Minovi A, Dazert S (2014) Diseases of the middle ear in childhood. *GMS Curr Top Otorhinolaryngol Head Neck Surg* 13: Doc11.
- Mas-Estelles F, Mateos-Fernandez M, Carrascosa-Bisquert B, Facal de Castro F, et al. (2012) Contemporary non-echo-planar diffusion-weighted imaging of middle ear cholesteatomas. *Radiographics* 32: 1197-1213.
- Bennett M, Warren F, Jackson GC, Kaylie D (2006) Congenital cholesteatoma: theories, facts, and 53 patients. *Otolaryngol Clin North Am* 39: 1081-1094.
- Nevoux J, Lenoir M, Roger G, Denoyelle F, Ducou Le Pointe H, et al. (2010) Childhood cholesteatoma. *Eur Ann Otorhinolaryngol Head Neck Dis* 127: 143-150.
- Zappia JJ, Wiet RJ (1995) Congenital cholesteatoma. *Arch Otolaryngol Head Neck Surg* 121: 19-22.
- Shohet JA, de Jong AL (2002) The management of pediatric cholesteatoma. *Otolaryngol Clin North Am* 35: 841-851.
- McKenna KX, Chole RA (1989) Post-traumatic cholesteatoma. *Laryngoscope* 99: 779-782.
- Mafee MF, Kumar A, Yannias DA, Valvassori GE, Applebaum EL (1983) Computed tomography of the middle ear in the evaluation of cholesteatomas and other soft-tissue masses: comparison with pluridirectional tomography. *Radiology* 148: 465-472.
- Nager G (1997) Theories on the origin of attic retraction cholesteatoma. *Proceedings of the Shambaugh Fifth International Workshop on Middle Ear Microsurgery and Fluctuant Hearing Loss Huntsville, AL, Strode*
- Vignaud J (1974) *Temporales fosses nasales cavités accessoires*: Masson.
- Orisek BS, Chole RA (1987) Pressures exerted by experimental cholesteatomas. *Arch Otolaryngol Head Neck Surg* 113: 386-391.