

# A Rare Case of Filariasis in a Male Breast- Case Report

Surjeet Dwivedi<sup>1\*</sup>, Surender Kumar<sup>2</sup>

<sup>1</sup>Department of Surgery and Oncology, Command hospital Air force Bangalore, Karnataka, India; <sup>2</sup>Department of Pathology, Army hospital research and referral, New Delhi, India

## ABSTRACT

Filariasis of the female breast, although unusual, is a known entity, whereas filariasis in a male breast or case of gynecomastia is extremely rare. We are presenting a case of a 17-year-old boy with painless swelling of a breast. Ultrasonography and FNAC (Fine Needle Aspiration Cytology) were unremarkable and the patient was diagnosed to have filariasis on histopathological examination of the lumpectomy specimen. Filariasis in gynecomastia is extremely rare and a high index of suspicion, especially in endemic areas, is warranted to avoid unnecessary surgery for a medically treatable cause.

**Keywords:** Gynaecomastia; Filariasis; Histopathological examination

## INTRODUCTION

Filariasis continues to be a major health problem in India despite efforts such as National vector-borne disease control programs. The usual sites of filariasis are the lymphatics of the lower limbs, upper limbs, and male genitalia. Breast is an unusual and rare site although cases have been reported in the past [1]. However, filariasis of the male breast is extremely rare. On an extensive search of the literature, we could find only one more case of filariasis of the male breast [2]. Filariasis may remain asymptomatic for varying periods or may present as lumps.

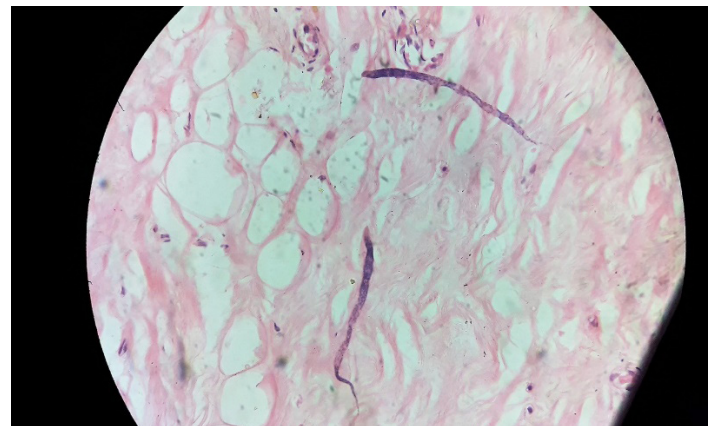
## CASE REPORT

A 17-year boy with no history of addiction or past illness presented with painless swelling of the left breast of two months' duration.

He was diagnosed with a case of grade II gynecomastia and was advised to follow up ultrasonography the breast revealed diffuse glandular hypertrophy. Fine needle aspiration cytology revealed only scanty acellular fluid with no cellular elements.

He requested surgical excision, as he was declared unfit for the same at the army selection rally. He underwent a subcutaneous mastectomy at our center. The post-op period was uneventful. Random sections revealed multiple microfilariae of *Wuchereria bancrofti* (Figure 1).

Microfilaria showed a long slender body with smooth curves. The body was sheathed and nuclei were seen throughout the length of the body except for the tapering tail, which was devoid of nuclei. Background breast tissue was unremarkable with no other significant pathology noted.



**Figure 1:** Multiple microfilaria of *Wuchereria bancrofti* with background breast tissue. *Wuchereria bancrofti* showing nuclei throughout the body except at tail, (H&E Stain x400).

## DISCUSSION

Filariasis is a major health problem in India, accounting for almost 40% of the world's disease burden [3]. The disease is endemic in 17 states and 6 union territories of India with Bihar having the highest endemicity (over 17%) followed by Kerala (15.7%), Uttar Pradesh (14.6%) [4]. Microfilaria is transmitted from infected to the new host by the bite of *Culex* mosquitoes which acts as an intermediate host. The larvae develop into adult worms in the lymphatic system. The female worm gives rise to 50000 microfilaria/day which comes in the blood circulation [5]. Our case was a young boy from an endemic area with the only complaint of gynecomastia. After an extensive search of the literature, we could only find one reported

**Correspondence to:** Surjeet Dwivedi, Department of Surgery and Oncology, Command hospital Air force Bangalore, Karnataka, India, Telephone: +918972569268; Email: surjeetdwivedi@gmail.com

**Received:** October 30, 2021; **Accepted:** November 24, 2021; **Published:** December 15, 2021

**Citation:** Dwivedi S, Kumar S (2021) A Rare Case of Filariasis in a Male Breast- Case Report. J Trop Dis 9:302

**Copyright:** ©2021 Dwivedi S, et al. This is an open-access article distributed under the terms of the Creative Commons Attribution License, which permits unrestricted use, distribution, and reproduction in any medium, provided the original author and source are credited.

case of filariasis in the male breast by Kohli K, et al. wherein the authors believed that theirs was in all probability the first such case being reported [2]. Due to the rarity of the case, filariasis may get overlooked as a cause of gynecomastia. In our case, Ultrasonography and FNAC were non-contributory. No other investigations were performed and he was listed for subcutaneous mastectomy. Filariasis as a cause of gynecomastia is a rare etiology and more cases that report filariasis in gynecomastia may establish it as a cause of gynecomastia. A high index of suspicion in cases where no other cause is apparent, especially in endemic areas, may help diagnose these cases and avoid unnecessary surgery.

## CONCLUSION

Filariasis in the case of gynecomastia is an extremely rare occurrence. However, in cases where no other cause is apparent, especially in endemic areas, a high index of suspicion should be exercised to rule out filariasis before resorting to surgical interventions.

## REFERENCES

1. Thakur M, Lhamo Y. Breast filariasis. *J Surg Case Rep.* 2014;2014:rjt128.
2. Kohli K, Jain S. Filariasis presenting as gynecomastia. *Breast J.* 2012;18:83-84.
3. Suma TK. Indian scenario of elimination of lymphatic filariasis. *Medicine update, Association of Physicians of India.* Munjal YP, Kolkata, India. 2013:6-9.
4. Raju K, Jambulingam P, Sabesan S, Vanamail P. Lymphatic filariasis in India: epidemiology and control measures. *J Postgrad Med.* 2010;56:232-238.
5. Park K. *Textbook of Preventive and Social Medicine.* 23<sup>rd</sup> edition. Epidemiology of communicable disease. 2015:270-271.