

What Might Lie Behind an Increased D-Dimer Level?

Walczak-Galezewska MK*, Braszak A and Bryl W

Department of Internal Diseases, Metabolic Disorders and Hypertension, Poznan University of Medical Sciences, Szamarzewskiego, Poznan, Poland

Aortic dissection (AD) is a disruption of the medial layer of the wall of the aorta, resulting in the separation of the aortic wall layers and the subsequent formation of a true lumen and a false lumen. Chronic AD is usually asymptomatic, despite widespread extension, but it can lead to dangerous situations, such as impaired renal perfusion, loss of peripheral pulse, compromised visceral perfusion, and other signs [1].

A 54-year-old woman was referred to our clinic because of resistant arterial hypertension (HT). Two months earlier, she had been hospitalized for cholecystitis; due to the new HT diagnosis, the scheduled operation was cancelled. Her past medical history was unremarkable, apart from successfully treated infertility. She had no family history of HT. She had not complained of anything apart from pains due to her gallstones (Figure 1).

Physical examination revealed tenderness in right upper abdominal pain, hirsutism, blood pressure over 200/100 mmHg, and no neurological deficiencies.

Laboratory studies showed hemoglobin, white blood cells, and cancer markers (AFP, Ca125, CEA, Ca19.9) in the references ranges. The following biochemical markers were out of range: serum creatinine 155 $\mu\text{mol/L}$ (50.0-115.0), C-reactive protein (CRP) 19.60 mg/L (0.0-5.0) and D-dimer level 9086 ng/mL (0.0-500.0). Chest imaging with abdominal ultrasonography (USG) revealed no new significant abnormalities.

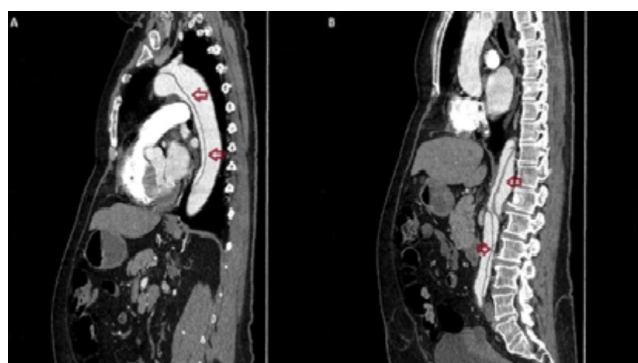


Figure 1: CT images present Stanford type B aortic dissection (AD), beginning at the arch level (A) and ending at the external iliac arteries (B).

Computed tomography (CT) of the adrenal glands showed a 5-mm adenoma in the left adrenal gland. USG of the renal arteries (RA) revealed abdominal aortic pathology below the RA. Despite the renal failure, an angio-CT of the aorta was conducted. CT images present Stanford type B aortic dissection (AD), beginning at the arch level and ending at the external iliac arteries (Figure 1). Because the patient had not presented any AD symptoms, observation and preservation of the current treatment were recommended.

D-dimer evaluation is used in the diagnosis of many diseases. It is an important part of pulmonary embolism diagnosis; the result, which is out of range, very often precedes the cancer process. The value of D-dimer measurement in acute AD (lasting less than 14 days) has been confirmed by the study of Asha et al. [2], who showed that a negative D-dimer result may help rule out acute AD in low-risk patients. We have few data for interpreting D-dimer level in the course of chronic AD (lasting over 90 days).

The most common risk factor of chronic AD is uncontrolled HT [3]. The early detection (including D-dimer measurement) in populations with resistant HT can help ensure proper observation of the patient and early treatment in the case of life-threatening complications.

The aim of this paper was to present the clinical image of the case of the no-symptomatic AD coexisting with very high D-dimer level, what indicates importance to determine the reason of this biochemical abnormality.

Acknowledgments

We would like to thank Dr. Ewelina Grela and Dr. Malgorzata Chelkowska-Partyka for their expertise and help in interpreting the angio-CT images.

References

1. Erbel R, Aboyans V, Boileau C, Bossone E, Bartolomeo RD, et al. (2014) 2014 ESC Guidelines on the diagnosis and treatment of aortic diseases: Document covering acute and chronic aortic diseases of the thoracic and abdominal aorta of the adult. The Task Force for the Diagnosis and Treatment of Aortic Diseases of the European Society of Cardiology (ESC). *Eur Heart J* 35: 2873-2926.
2. Asha SE, Miers JW (2015) A Systematic Review and Meta-analysis of D-dimer as a Rule-out Test for Suspected Acute Aortic Dissection. *Ann Emerg Med* 66: 368-378.
3. Thrururthy SG, Karthikesalingam A, Patterson BO, Holt PJ, Thompson MM (2011) The diagnosis and management of aortic dissection. *BMJ*.

***Corresponding author:** Walczak-Galezewska MK, Department of Internal Diseases, Metabolic Disorders and Hypertension, Poznan University of Medical Sciences, Szamarzewskiego, Poznan, Poland, Tel: +48 618549377; Fax: +48 618478529; E-mail: walczak_marta@interia.pl

Received November 08, 2018; **Accepted** December 20, 2018; **Published** December 27, 2018

Citation: Walczak-Galezewska MK, Braszak A, Bryl W (2018) What Might Lie Behind an Increased D-Dimer Level? *J Vasc Med Surg* 6: 375. doi: [10.4172/2329-6925.1000375](https://doi.org/10.4172/2329-6925.1000375)

Copyright: © 2018 Walczak-Galezewska MK, et al. This is an open-access article distributed under the terms of the Creative Commons Attribution License, which permits unrestricted use, distribution, and reproduction in any medium, provided the original author and source are credited.