

Use of 980 nm Diode laser for Lingual Frenectomy: A Case Report

Malik Waqas Javied¹, Zafar Quratul-Ain²

¹Department of Oral and Maxillofacial Surgery, Shaheed Zulfiqar Ali Bhutto Medical University, Islamabad, Pakistan, ²Department of Conservative Dentistry and Endodontics, Islamabad Medical and Dental College and Hospital, Bharakahu, Islamabad, Pakistan

Abstract

A frenum is a soft tissue attachment of the labial, buccal and lingual mucosa to the jaw bones. Abnormalities in development of this soft tissue fold may present as a very short lingual frenum limiting the mobility of the tongue. This condition is termed as ankyloglossia or tongue tie. The surgical technique is used to reposition the frenum and correct the functional impairments caused by ankyloglossia. This case report presents a 30 years old male patient with impairment of speech due to the short lingual frenum. 980 nm diode laser was used for frenectomy which showed minimal pain and healing with no complications. Surgical procedures like frenectomy and biopsy of oral lesions can be effectively carried out using Diode laser.

Key Words: Diode Lasers, Ankyloglossia, Tongue-tie

Introduction

Ankyloglossia is a congenital abnormality presenting with a very short lingual frenum. The word 'ankyloglossia' originates from the Greek words "agkilos" means "curved" and "glossa" means "tongue". Ankyloglossia is defined as "limited normal movement of the tongue chiefly due to an abnormally shortened frenulum" [1].

The tongue is a muscular organ and performs a variety of functions most important speech and deglutition. Patients with ankyloglossia present with multiple problems ranging from feeding difficulties in infants to difficulty in speech and social problems to the patients. Infants present feeding difficulties, mouth breathing, and malaligned teeth. Limitation of tongue movements produces lisp and improper pronunciation of words during the speech.

Ankyloglossia is managed according to the severity of symptoms. In moderate to severe ankyloglossia, surgical intervention is indicated. This is achieved by incising the mucosa and fibrous attachments using a scalpel and blade followed by primary closure.

Lasers have the ability to perform very precise incision without excessive bleeding. Diode lasers function by cutting with an initiated hot tip causing vaporization of soft tissues and minimal to no interaction with dental hard tissue. This selective effect makes them suitable for soft tissue surgical procedures [2]. The contact cutting mode provides enhanced bloodless site visibility and facility to perform delicate soft tissue procedures, which is important in areas with difficult access. Moreover, the need for suturing to achieve hemostasis is minimal. The need for local anesthetics and post-op medications is greatly reduced owing to the minimally invasive surgical procedure performed by lasers. This article presents a successful case of lingual frenectomy in an adult patient with severe ankyloglossia.

Aim

This case report presents an advanced technique for minimally invasive surgical correction of ankyloglossia with predictable functional results and improved mobility of the tongue. The aim of this study was to show the application of 980 nm diode laser for frenectomy procedure and evaluate the healing phase.

Case Report

A 30 years old man presented with complaint of impaired speech and pronunciation since childhood.

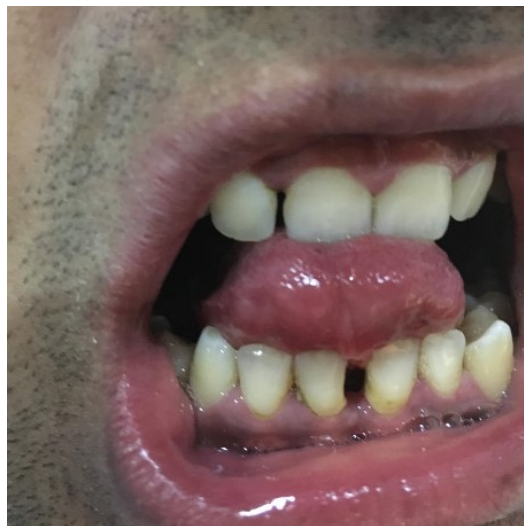

Figure 1. Preoperative view showing maximum protrusion of the tongue.

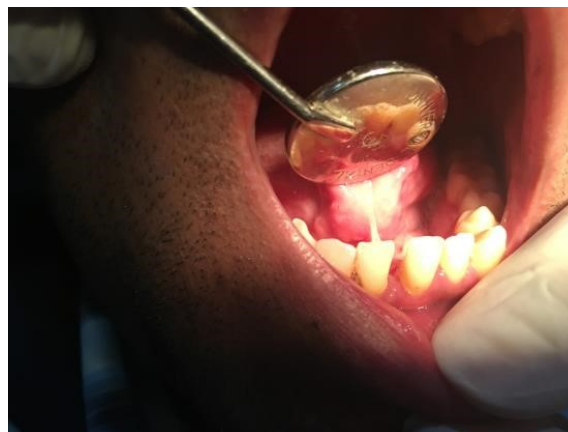


Figure 2. Preoperative view showing short lingual frenum.

Corresponding author: Dr. Malik Waqas Javied, Department of Oral and Maxillofacial Surgery, Shaheed Zulfiqar Ali Bhutto Medical University, Islamabad, 44000, Pakistan, Tel: +923335637948; E-mail: waqas088@yahoo.com

The patient was otherwise healthy and had a significant medical history or systemic diseases. On clinical examination, it was observed that tongue movement was severely restricted and a very short lingual frenum was present (*Figure 1*).

The frenal attachment was close to the tip of the tongue and it was causing the functional problem of speech limitation (*Figure 2*). The patient was assessed for ankyloglossia and “free tongue length” was measured according to Kotlow et al. criteria [3]. It was diagnosed as Class III ankyloglossia with a free tongue length of 6 mm.

The surgical procedure of frenectomy was planned using a 980 nm diode laser. Informed consent was obtained from the patient. Topical anesthesia was applied with Lignocaine spray for 2 minutes. Eye safety measures were taken. Diode laser (Lasotronix Smart, Poland) was used in contact mode at 1.5-Watt power settings in continuous mode (*Figure 3*).

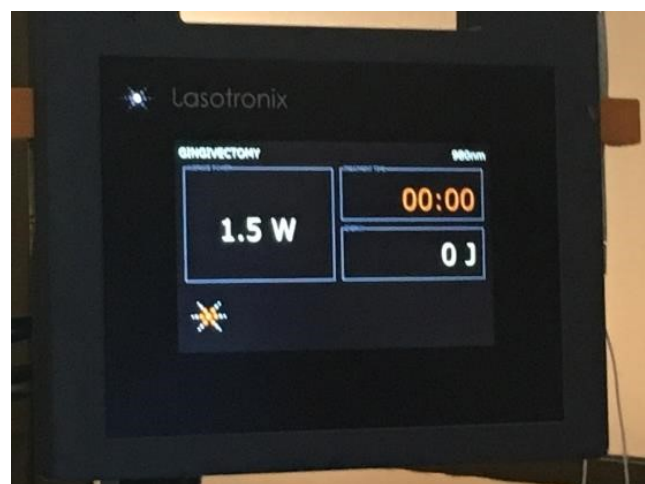

Figure 3. Diode Laser Parameters used for surgical procedure.

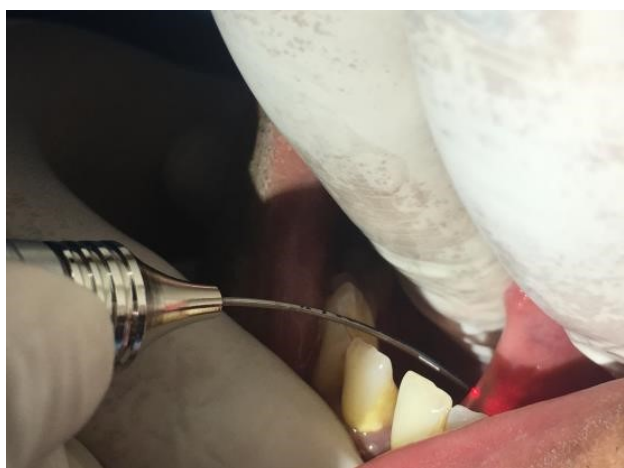


Figure 4. Surgical tip of diode laser intraoperatively.

A 300 μm optic fiber was used in controlled movements excising the lingual frenum and fibrous attachments till sufficient tongue movement was appreciable. Immediate evaluation for improvement in range of tongue movement was observed. No sutures were needed as there was no bleeding intraoperatively. Postoperative instructions were given to the

patient and follow-up visits were scheduled at 1 week, 1 month and 3 months postoperatively (*Figure 4*).

Laser Parameters

- A device used: Lasotronix Smart 10 Watts 980 Diode Laser (Lasotronix ul. Żytnia 1 05-500 Piaseczno Poland)
- Wavelength: 980 nm, Emission mode: Continuous wave, Output Power: 1.5 Watts
- Tip used: 300 μm initiated tip, Operating mode: contact mode, Total contact time: 180 sec

Results

Lingual frenectomy was completed in minimal time and under topical anesthesia. There was excellent hemostasis and no suturing was required (*Figure 5*).

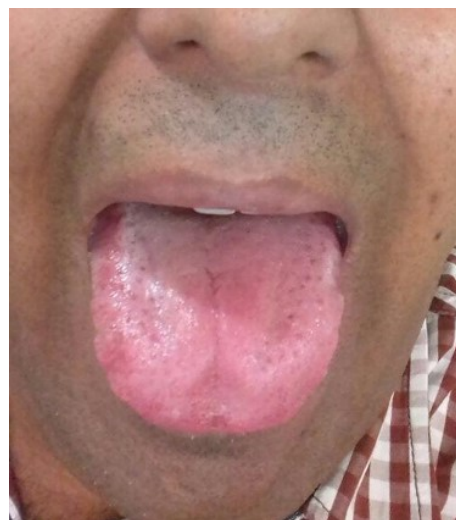

Figure 5. Postoperative view showing maximum protrusion of the tongue.

Discussion

Ankyloglossia or tongue-tie is a congenital anomaly where the lingual frenum is very short and is attached closer to the tip of the tongue [4]. This condition varies in severity with no functional impairments in mild cases to severe ankyloglossia presenting with feeding difficulties in infants, speech and articulation difficulties as well as periodontal and malocclusion problems in children and adults. The exact etiopathogenesis of ankyloglossia remains unclear; it may present solely as a localized anomaly or in association with other craniofacial anomalies [5]. Correction of this condition is necessary in such cases to relieve these symptoms.

Tongue performs three functions i.e. speech, deglutition, and mastication. In the adult, deglutition occurs when teeth come into occlusion and the anterior part of the tongue is pressed against anterior hard palate creating a vacuum. With limited tongue mobility, this function gets impaired.

Ankyloglossia was also found associated with certain rare syndromes Van der Woude syndrome [6], X-linked cleft palate syndrome, Opitz syndrome [7], Kindler syndrome [8] and Floating-Harbor syndrome [9]. However, the majority of

ankyloglossia cases occur individually without any systemic manifestations.

Speech impairment is a major issue faced by adult patients with a tongue tie as observed in this case. The difficulty is articulation is evident during the pronunciation of consonants and sounds “s, z, t, d, n, l, j, ch, zh, th, dg” [10]. The maximum difficulty is encountered in lingual-alveolar sounds (particularly /l/) and interdental sounds (voiced and voiceless /th/) because the tongue needs to be maximally raised and the tip must touch the anterior palate for correctly pronouncing these sounds [11].

In the present case, our patient had difficulty in pronouncing above mentioned along with spillage of saliva during the speech, since childhood. However, the patient sought treatment at this age when he started having social concerns. After careful evaluation, frenectomy was planned and physical impairment was relieved.

The diode laser is a very useful tool for minimally invasive surgical procedures. The significant benefits with laser procedures include minimal or no intraoperative bleeding providing an excellent vision of the operative field, little need for local anesthetics, superior healing, and no postoperative pain or discomfort.

Other lasers that are used for oral surgical procedures include CO₂ laser and Er: YAG lasers. These lasers are also effective in soft tissue incisions and provide superior hemostasis and rapid healing postoperatively. These lasers enable faster and minimally invasive surgical procedures.

The patient was educated to modify the deglutition and speech pattern following a frenectomy. The postoperative training included, repeatedly practice speaking the syllables that were difficult to pronounce by reading out loud, secondly, it was advised to protrude the tongue maximally out of the mouth and try to touch the tip of nose and chin. These exercises were advised for 2 weeks postoperatively to train the tongue muscles for the new movements that were previously restricted

In conclusion Diode, laser proved superior to the conventional surgical incision. There was minimal morbidity and immediate hemostasis was obtained thus proving effective for this procedure. High level of patient comfort and excellent healing postoperatively makes Diode laser an effective tool for this procedure.

References

1. <https://www.merriam-webster.com/medical/ankyloglossia>
2. Borzabadi FA. The adjunctive soft-tissue diode laser in orthodontics. *Compendium of Continuing Education in Dentistry*. 2017; **38**: 18-31.
3. Kotlow LA. Ankyloglossia (tongue-tie): A diagnostic and treatment quandary. *Quintessence International*. 1999; **30**.
4. Junqueira MA, Cunha NN, e Silva CO, Lucas L, Araújo LB, et al. Surgical techniques for the treatment of ankyloglossia in children: A case series. *Journal of Applied Oral Science*. 2014; **22**: 241-248.
5. Tsaousoglou P, Topouzelis N, Vouros I, Sculean A. Diagnosis and treatment of ankyloglossia: A narrative review and a report of three cases. *Quintessence International*. 2016; **47**.
6. Rizos M, Spyropoulos MN. Van der Woude syndrome: A review. Cardinal signs, epidemiology, associated features, differential diagnosis, expressivity, genetic counseling and treatment. *European Journal of Orthodontics*. 2004; **26**: 17-24.
7. Meroni G. X-linked opitz G/BBB syndrome. In Gene Reviews. 2018 Apr 5. University of Washington, Seattle.
8. Barbosa NM, Visioli F, Martins MD, Martins MA, Munerato MC. Oral manifestations in Kindler syndrome: Case report and discussion of literature findings. *Special Care in Dentistry*. 2016; **36**: 223-230.
9. Singh A, Bhatia HP, Sood S, Sharma N, Mohan A. A novel finding of oligodontia and ankyloglossia in a 14-year-old with floating-harbor syndrome. *Special Care in Dentistry*. 2017; **37**: 318-321.
10. Khan S, Sharma S, Sharma VK. Ankyloglossia: Surgical management and functional rehabilitation of tongue. *Indian Journal of Dental Research*. 2017; **28**: 585.
11. Mishra G, Jayam C. Ankyloglossia-detailed review with a case report. *International Healthcare Research Journal*. 2017; **1**: 28-32.