

Treatment of Maxillary Incisors with Periapical Surgery Using Mineral Trioxide Aggregate

Jun-Beom Park¹, Jeong-Heon Lee²

¹Department of Periodontics, College of Medicine, The Catholic University of Korea, Seoul, Republic of Korea, ²Private Dental Clinic

Abstract

Introduction: Mineral trioxide aggregate (MTA) has a variety of possible uses, including root-end filling material due to its excellent sealing ability in the presence of moisture and a high degree of biocompatibility. **Aim:** This case report demonstrates the use of MTA as an obturating material to promote periapical healing of root canals with large apical rarefactions. **Materials and Methods:** An 18-year-old female presented with a complaint of dental caries in the upper anterior region. Radiographic lesions were found with 4 mm and 10 mm sizes in the central and lateral incisors, respectively. The patient presented with swelling of gingiva and formation of fistula one month after filling of root canals. MTA was used as an apical filling material for the apical surgery. **Discussion and Conclusions:** This case reports how teeth that had large periapical lesions with recurring symptoms could be fixed with periapical surgery using MTA.

Key Words: Incisor, Mineral trioxide aggregate, Periapical periodontitis, Surgical flaps

Introduction

Mineral trioxide aggregate (MTA; Pro-Root®, Dentsply, Tulsa, OK, USA) has shown potential as a root-end filling material [1-3] due to its excellent sealing ability in the presence of moisture [4,5] and a high degree of biocompatibility [6,7]. MTA is also reported to produce precipitates with a composition and structure similar to that of hydroxyapatite [8]. This case report demonstrates the use of MTA as an obturating material to promote periapical healing of root canals with large apical rarefactions.

Case Presentation

Case

An 18-year-old female presented to the clinic with a complaint of dental caries in the upper anterior region. The patient had been informed of her multiple decayed teeth previously, but she had not pursued dental treatment. Her medical history was noncontributory. The upper right central and lateral incisors were unresponsive to sensitivity testing with cold or an electric pulp tester (Parkell, Farmingdale, NY, USA). Radiographic lesions were found with 4 mm and 10 mm sizes in the central and lateral incisors, respectively (Figure 1A). Clinical and radiographic examinations indicated pulp necrosis with chronic apical periodontitis. The patient was given a detailed explanation concerning the planned treatment procedure and prognosis. Consent was received from the patient.

The teeth were isolated with a rubber dam. Conventional access cavities were prepared in the lingual surfaces of the central and lateral incisors with a #330-carbide bur, and the cavities were widened with a lateral cutting bur (Endo-Z bur, Dentsply) to enhance the visibility of the root canals. The canals were cleaned with a manual instrument and then gently irrigated with 5% sodium hypochlorite several times. The last irrigation solution was left in the canals for 30 minutes to dissolve any organic material. Determination of the working length was done using an electronic apex locator (Root ZX®, J

Morita Corporation, Kyoto, Japan) and a radiograph (Figure 1B).

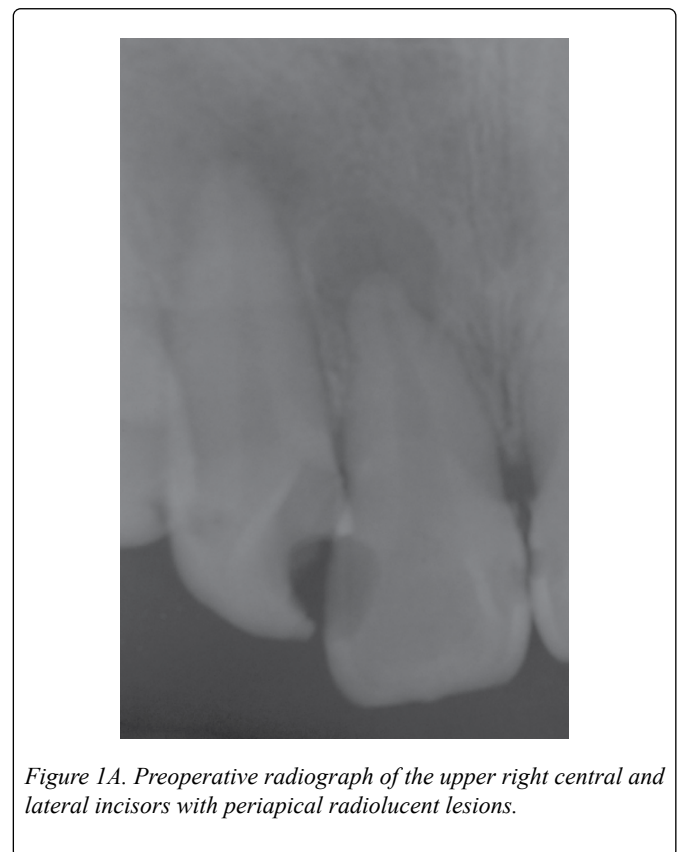

Figure 1A. Preoperative radiograph of the upper right central and lateral incisors with periapical radiolucent lesions.

Canal enlargement was then performed using nickel-titanium rotary instruments (Profile, Dentsply Tulsa, Tulsa, OK, USA). The canals were irrigated with 5% sodium hypochlorite, and calcium hydroxide was applied twice more over the interval of one week. Then, the canals were obturated using gutta percha and sealer (AH26®, Dentsply). A matched taper master cone was placed to obturate the canals below the level of the staging platform and sealed off at the level with a heat source (System B, Analytic Technology, Redmond, WA, USA).

Corresponding author: Jun-Beom Park, Department of Periodontics, Seoul St Mary's Hospital, College of Medicine, The Catholic University of Korea, 222, Banpo-daero, Seocho-gu, Seoul, 06591, Republic of Korea, Tel: +82-10-4325-2651; Fax: +82-2-537-2374; E-mail: jbasoonis@yahoo.co.kr

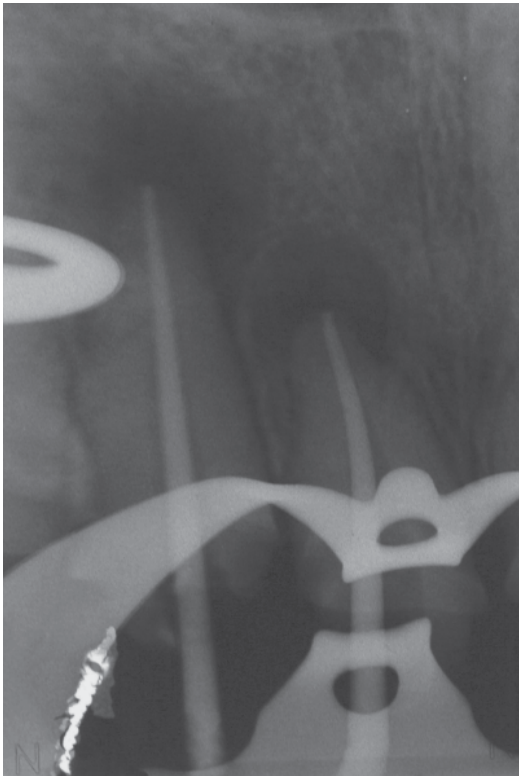


Figure 1B. Working length radiograph.

The remaining portion of the canals were back-filled with the thermoplastic gutta percha technique (Obtura II, Obtura-Spartan Corporation, Fenton, MO, USA) (Figure 1C).

A resin core was added, and the treated teeth were restored with temporary prostheses constructed from a chemical cure composite (ALIKE, GC America Incorporation, Chicago, IL, USA). The patient presented with swelling of gingiva and formation of fistula one month after the filling of root canals. A radiograph was taken with gutta percha cone tracing to indicate the location of the source of the infection that was draining gingivally (Figure 2A).

Under a 2% lidocaine with 1:100,000 epinephrine local anesthetic injection, a horizontal incision was made with a No. 15 blade on the attached gingiva that was 2 to 3 mm apical to the gingival margin. A vertical releasing incision was made one tooth mesial to the involved tooth, and this incision was made perpendicular to the horizontal incision.

A full-thickness mucoperiosteal flap was elevated, and the apical area was thoroughly debrided and degranulated to remove all the tissue (Figure 2B). The defect had a 10 mm diameter on the lateral incisor and a 3 to 4 mm diameter on the central incisor. Root-end resection was performed at 90 degrees, 2 to 3 mm from the apex, and root-end cavities were prepared by ultrasonic retrotip (Figure 2C).

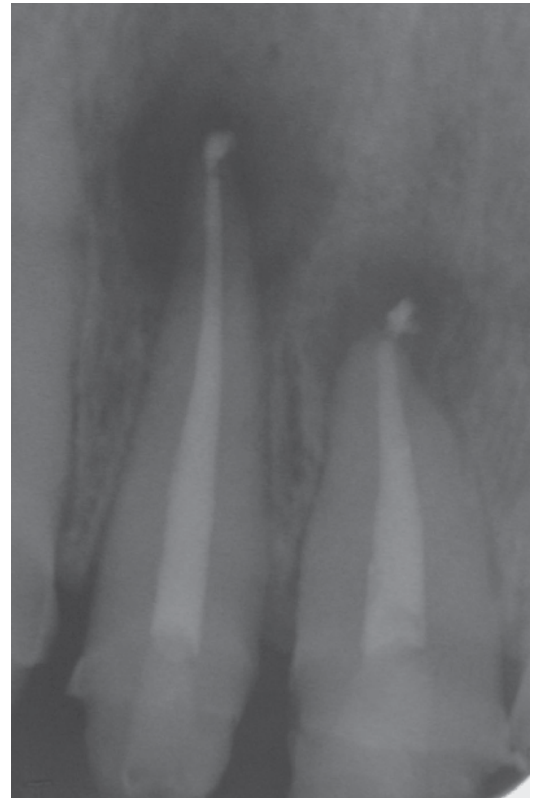

Figure 1C. Radiograph of the upper right central incisor and lateral incisor filled with the thermoplastic gutta percha technique.

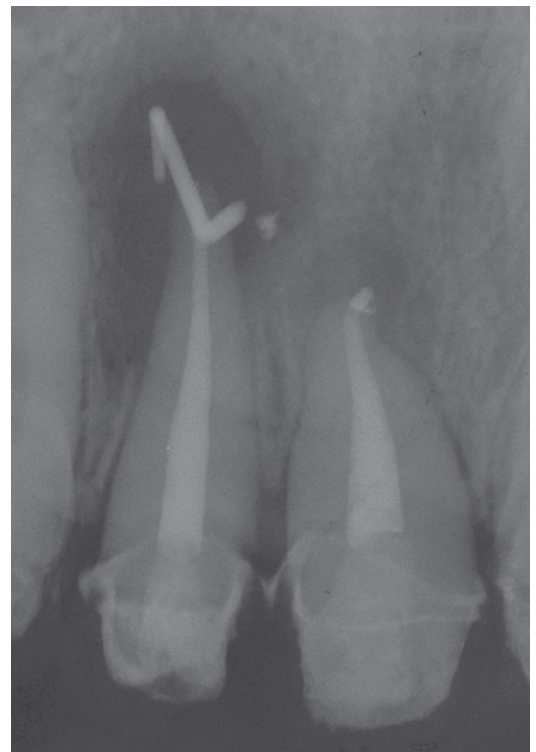


Figure 2A. A radiograph with gutta percha cone tracing taken at one month after canal filling.

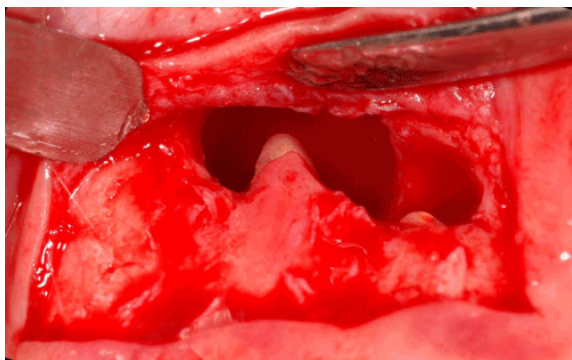


Figure 2B. Apical area thoroughly debrided and degranulated to remove all tissue.

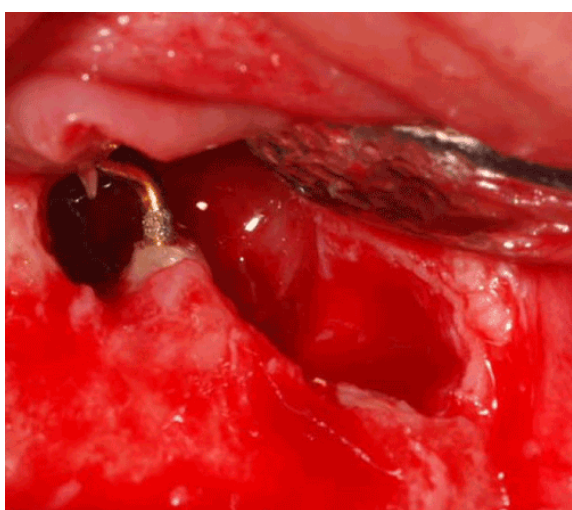


Figure 2C. A root-end resection was performed and root-end cavities were prepared via ultrasonic retrotip.

MTA was mixed with sterile water to a paste consistency, following the manufacturer's instructions, and retrograde filling was done with MTA (Figure 2D).

Discussion

The raised flap was repositioned with suture material, and a periodontal dressing was applied. Patient was placed on cefaclor 250 mg, 3/day for 5 days; ibuprofen 400 mg, 3/day for 5 days; ibuprofen 400 mg, 3/day for 5 days and chlorhexidine digluconate 0.12%, 3/day for 2 weeks. She was asked not to chew or brush the surgical area for the first 4 weeks postoperatively. Finally, the treated teeth were restored with porcelain-fused metal crowns 2 weeks after endodontic surgery. The teeth have been asymptomatic since the obturation. The patient was recalled regularly, and she was clinically and radiographically asymptomatic up to the 5-month follow-up (Figure 3).

MTA has an excellent sealing ability in the presence of moisture in a root canal, and it has minimal risk of marginal leakage and bacterial reinfection [9]. These properties are especially important in teeth receiving apical surgery with large periapical lesions and granulation tissue because the material may be exposed to blood [10].

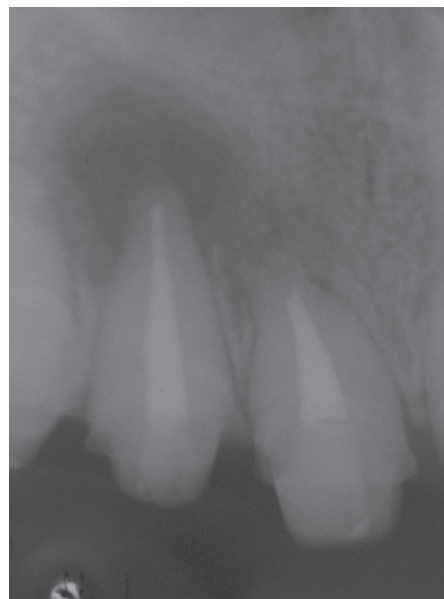

Figure 2D. Radiograph of the upper anterior teeth after retrograde filling.

Sarkar et al. [8] reported that endodontically prepared teeth filled with mineral trioxide aggregate and stored in synthetic tissue fluid at 37°C for 2 months produced an adherent interfacial layer at the dentin wall that resembled hydroxyapatite in composition. The authors suggested that Ca, the dominant ion released from mineral trioxide aggregate, reacts with phosphates in synthetic tissue fluid, yielding hydroxyapatite. It is likely that the high pH of MTA contributes a further reduction of bacterial factors [11].

The underlying reason for endodontic failures is almost invariably due to bacterial infection. Management of the failing root canal filling begins with the identification of the source of the persistent infection [12]. The bacteria may be situated within a previously missed or uninstrumented portion of a root canal, infiltrating via a leaky coronal restoration and root filling, and thus, orthograde retreatment may be the choice of treatment.

However, Mortensen et al. stated that, with a radiographic lesion size of 10 mm, the incidence of cysts was 53% [13], and Morse et al. [14] reported that the incidence of cysts was 67% with a lesion size of 10 mm or larger. The fenestration of root apices through the cortical plate can be confirmed by manual examination, and there was a possibility of cysts in this case. Periapical surgery was initiated after considering the patient's history, the quality of the nonsurgical endodontic treatment, and the cooperation from the patient.

It has been reported that resection of the apical 3 mm with a 3 mm root-end preparation reduces 98% of the apical ramifications and 93% of the lateral canals during periapical surgery [15,16]. In this report, the ultrasonic retro preparation technique was used to overcome the major shortcomings of the conventional rotary bur type of preparation [17]. As the size of the ultrasonic tip was reduced, it was easier to place into the crypt, and this technique greatly facilitated preparation perpendicular to the long axis of the root. A 5-month postoperative radiograph revealed a decrease of the

periapical rarefaction, confirming healing of the periapical region.

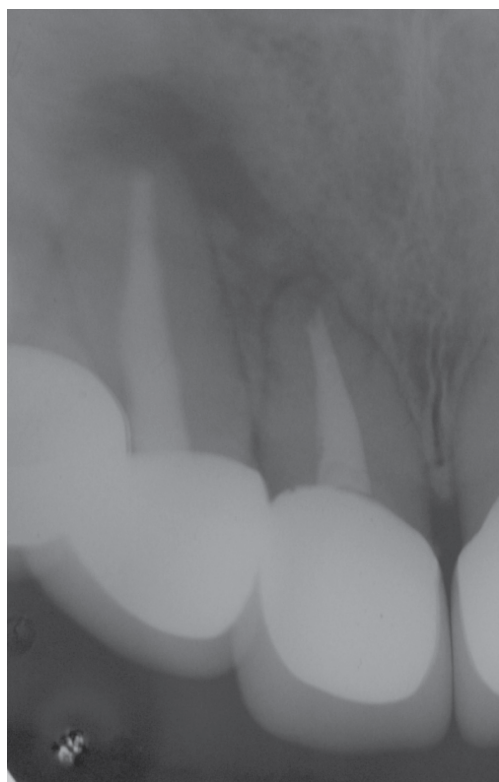


Figure 3. Five-month postoperative radiograph showing periapical healing.

MTA solidifies as a hard structure in approximately 4 hours in a humid condition [11], and thus, the patient was instructed not to eat for at least the first 4 hours postoperatively. The final restoration is suggested to be placed 1 to 7 days after the reparative procedure [18].

The incision line was made on the attached gingiva to prevent placing the incision line over the apical pathosis. A full-thickness flap with a sulcular incision was avoided because full-thickness flaps, which denude the bone, result in crestal bone loss of about 1 mm, which would have caused loss of vertical height of the supporting tissues and, consequently, a detrimental effect on the esthetics [19]. This clinical case demonstrates that, when MTA is used as an apical filling material for surgery, the defect can be effectively sealed. This case reports that teeth with large periapical lesions with recurring symptoms could be fixed with periapical surgery using MTA.

Acknowledgements

This research was supported by Basic Science Research Program through the National Research Foundation of Korea (NRF) funded by the Ministry of Science, ICT & Future Planning (NRF-2014R1A1A1003106). The author claims to have no financial interest in any company or any of the products mentioned in this article.

References

1. Chong BS, Pitt Ford TR, Hudson MB. A prospective clinical study of Mineral Trioxide Aggregate and IRM when used as root-end filling materials in endodontic surgery. *International Endodontic Journal*. 2003; **36**: 520-526.
2. Lindeboom JA, Frenken JW, Kroon FH, van den Akker HP. A comparative prospective randomized clinical study of MTA and IRM as root-end filling materials in single-rooted teeth in endodontic surgery. *Oral Surgery, Oral Medicine, Oral Pathology, Oral Radiology*. 2005; **100**: 495-500.
3. Saunders WP. A prospective clinical study of periradicular surgery using mineral trioxide aggregate as a root-end filling. *Journal of Endodontics*. 2008; **34**: 660-665.
4. Hachmeister DR, Schindler WG, Walker WA, 3rd, Thomas DD. The sealing ability and retention characteristics of mineral trioxide aggregate in a model of apexification. *Journal of Endodontics*. 2002; **28**: 386-390.
5. Hayashi M, Shimizu A, Ebisu S. MTA for obturation of mandibular central incisors with open apices: case report. *Journal of Endodontics*. 2004; **30**: 120-122.
6. Torabinejad M, Hong CU, Lee SJ, Monsef M, Pitt Ford TR. Investigation of mineral trioxide aggregate for root-end filling in dogs. *Journal of Endodontics*. 1995; **21**: 603-608.
7. Torabinejad M, Pitt Ford TR, McKendry DJ, Abedi HR, Miller DA, Kariyawasam SP. Histologic assessment of mineral trioxide aggregate as a root-end filling in monkeys. *Journal of Endodontics*. 1997; **23**: 225-228.
8. Sarkar NK, Caicedo R, Ritwik P, Moiseyeva R, Kawashima I. Physicochemical basis of the biologic properties of mineral trioxide aggregate. *Journal of Endodontics*. 2005; **31**: 97-100.
9. Torabinejad M, Watson TF, Pitt Ford TR. Sealing ability of a mineral trioxide aggregate when used as a root end filling material. *Journal of Endodontics*. 1993; **19**: 591-595.
10. Torabinejad M, Higa RK, McKendry DJ, Pitt Ford TR. Dye leakage of four root end filling materials: effects of blood contamination. *Journal of Endodontics*. 1994; **20**: 159-163.
11. Torabinejad M, Hong CU, McDonald F, Pitt Ford TR. Physical and chemical properties of a new root-end filling material. *Journal of Endodontics*. 1995; **21**: 349-353.
12. Cheung GS. Endodontic failures--changing the approach. *International Dental Journal*. 1996; **46**: 131-138.
13. Mortensen H, Winther JE, Birn H. Periapical granulomas and cysts. An investigation of 1,600 casesScandinavian. *Journal of Dental Research*. 1970; **78**: 241-250.
14. Morse DR, Patnik JW, Schacterle GR. Electrophoretic differentiation of radicular cysts and granulomas. *Oral Surgery, Oral Medicine, Oral Pathology, Oral Radiology*. 1973; **35**: 249-264.
15. Kim S, Kratchman S. Modern endodontic surgery concepts and practice: a review. *Journal of Endodontics*. 2006; **32**: 601-623.
16. Jang JH, Lee JM. Surgical endodontic management of infected lateral canals of maxillary incisors. 2015; **40**: 79-84.
17. Carr GB. Ultrasonic root end preparation. *Dental Clinics of North America*. 1997; **41**: 541-554.
18. Arens DE, Torabinejad M. Repair of furcal perforations with mineral trioxide aggregate: two case reports. *Oral Surgery Oral Medicine Oral Pathology Oral Radiology Endodontics*. 1996; **82**: 84-88.
19. Caffesse RG, Ramfjord SP, Nasjleti CE. Reverse bevel periodontal flaps in monkeys. *Journal of Periodontology*. 1968; **39**: 219-235.