

The results of clinic-morphological investigation of glutamic acid influence on the experimental dental fluorosis (The Experimental research)

Ch. A.Pasahev¹, A.N.Aliev², H.K.Muradov¹, A.Ch.Pashaev², F.Y.Mammadov²

Baku, Azerbaijan

Summary

Objective. The experimental investigations on the teeth of rats for determining the prophylaxis influence of the glutamic acid on the level of dental (teeth) fluorosis were made. Have been studied both clinical and histological conditions (picture) of teeth of experimental animals.

Methods

We made experiment on 60 rats with 30-50 gr by weight. The animals have been divided into 3 groups 20 rats in each group. The I groups (control) the rats which were on a usual vivarium ration and received water with the contents of fluorine 0,30-0,45 mg/l; II group (comparison) rats receiving water with the contents of fluorine 15 mg/l; III group – (main group) – the animals received both water with the contents of fluorine 15 mg /l and 1% solution of glutamic acid 2 times per a week intra orally. Histological investigations have been made on sections of rat's teeth, which were painted (colored) with hemotoxilin –eozine, thionine.

Results. On incisors of rats receiving water with the contents 15 mg/l of fluorine at 4-5 weeks the area (zone) of depigmentation characteristic for dental fluorosis has appeared. Microscopically was observed hypoplasia, enamel prisms have both crimped and indirect courses. The results of these were the infringement of Sroger line and sometimes its absence. In group of rats receiving simultaneously water with high concentrations of fluorine and 1% solution of glutamic acid similar both clinical and histochemical changes were not occurred (marked).

Conclusion. The glutamic acid prevented teeth fluorosis because of neutralization of a fluoric intoxication (high level of fluorine).

Keywords. Dental fluorosis, (DF) glutamic acid, (GA) enamel (E).

Substantiation of the subject of research

Practically its enamel was similar to normal enamel of rats that were on vivarium ration. The glutamic acid prevented teeth fluorosis because of neutralization of a fluoric intoxication (high level of fluorine).

One of prevalent pathology of hard tissue of tooth is dental fluorosis, concerning of uncarius lesion. In spite of it that the aetiology of this disease is known for a long time, at present day many people suffer from given defeat of hard tooth tissues [1, 3, 5, 6, 7]. As known, the main characteristics of fluorosis are spots, defects on enamel promoting cosmetic and structural defect, discoloration.

For prophylaxis of DF have been used general methods: replacement of source of drinking water, defluoridation of water, mixing of this water with water which has less quantity of fluorine. However, practically these measures not always possible to realize because of technical or economic opportunities [2]. That's why, it is important to realizations

of individual preventive measures against fluorosis, for example, prescription of tablet of calcium, vitamins, the appropriate diet, temporary departure from the region of fluorosis etc. But, studying of the literature shows that these measures not always give desired effect.

That's why, at present time the study of effective method of individual prevention against fluorosis continues, to be actual problems, and achievement these purpose will have scientific and practical meaning. For this reason we paid attention to glutamic acid using, of which reduced the toxic influence of fluorine and promoted improvement of clinical picture of industrial dental fluorosis [4].

Material and methods

We made experiment on 60 rats with 30-50 gr by weight. The animals have been divided into 3 groups 20 rats in each group. The I group (control) the rats which were on a usual vivarium ration and received water with the contents of fluorine 0,30-

¹ Prof.Dr. Department of Therapeutic Dentistry, Azerbaijan Medical University, Baku, Azerbaijan

² Assist. Prof. Department of Therapeutic Dentistry, Azerbaijan Medical University, Baku, Azerbaijan

0,45 mg/l; II group (comparison) rats receiving water with the contents of fluorine 15 mg/l; III group – (main group) – the animals received both water with the contents of fluorine 1,5 mg /l and 1% solution of glutamic acid, 2 times per a week intra orally. Histological investigations have been made on sections of rat's teeth, which were colored with hematoxylin-eosin, thionine.

Results and discussion

On the II group the manifestation of fluorosis is occurred on incisor. In none case the damage of molar tooth were found. According to our investigations a clinical picture of DF in rats is characterized with following: the absent of usual brown coloring of lip surface of enamel, the color of E was chalky. The color of incisor differed from these in rats of control group, which didn't receive fluoridated water. The E of rats of III group was not destroyed by DF. The E of incisors in all animals was normal, i.e. flown coloring. On surface of E isn't revealed depigmentated zone. This is indicated, that added of glutamic acid to diet ration of rats provide reduction of toxic influence of fluorine to such degree that its quantity used in our experiences unable to cause disturbance of a mineralization of E of the teeth. Probably, the prevention of the development and clinical manifestation of a DF is a result of neutralization of negative influence of a fluoric intoxication on organism and in particular on tooth germ. Obviously, arising disturbance of a metabolism, especially of mineral and protein exchange, during penetration of the raised doses of fluorine, into organism are blocked by glutamic acid. It is support by histological investigations on teeth of experimental rats. The E of teeth in the I group of animals receiving a water with the contents of fluorine 0,30-0,45 mg/l is yellow – brown colored, the thickness of E on both cutting edge and chewing surface is approximately 2,1 mm, at cervical region is 2,5 mm. Infringement, pigmentation and depigmentation were not occurred, the concentration not soft. Microscopically within the enamel has been revealed enamel prism (Figure 1).

The painted revealed the presence of oval prisms with indirect course (Figure 2).

On the cross section of teeth are occurred incremental striate of Retzius which associated with the variations in structure and mineralization.

On the control group the teeth was not affected by hypoplasia of enamel and the pigmented and depigmented zones on them are not defined (also spot).

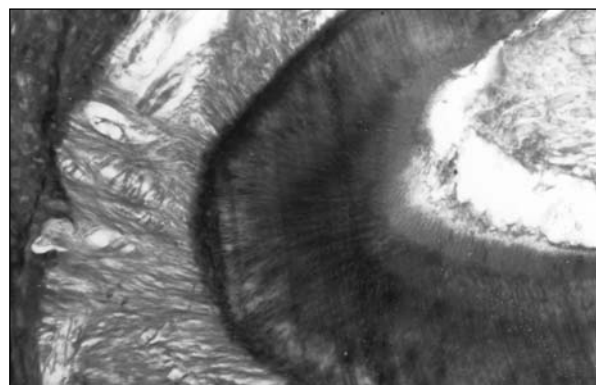


Figure 1. I group control. The integrity of enamel prism is kept. The enamel prism is oriented perpendicularly in DEJ direction. On the section of tooth enamel prisms have s forming course on the both enamel's surface and DEJ's direction.

Hematoxylin-eosin, 70




Figure 2. II group – the comparison group. The painted section of enamel prisms. In transverse section enamel prisms follow spiral (s) course, producing an alternating (light and dark strips) layer of. The production of these bands (H-S) is a result of changes in direction of enamel prisms. Hematoxylin-eosin, 280

It is important to note, that the II group comparison, the animals of this group received water which content 15 mg/l of NaF. Microscopically, the teeth in this group are subdivided into 3 groups: I) very poorly depigmentation of teeth; II) have been found the teeth with both white and black color; III) infringement of edge of teeth, difficulties in the production of tooth section, rough surface. E prisms of depigmented tooth of I group in comparison with norm is more contrast, haven't change in course and are aligned perpendicularly to DEJ. S formed prisms (indirect) were revealed. The region of DEJ hadn't enamel rods.

On the cervical areas of parallel teeth have been revealed depigmented strips of white color (Figure 3).

The revealed painted zone indirect form (Figure 4).




Figure 3. II group the comparison group. The zone of depigmentation. These strips are replaced with other normally pigmented strips. Hematoxylin-eosin, 200




Figure 4. II group the comparison group. The zone with indirect form. The widening of interprismatic spaces. Macroscopic in the II group, the direction of the prism, of the teeth with depigmented, klinoid strips are destroyed. Hematoxylin-eosin, 200

In the field of interprism spaces are marked amorphous zone station (spot)-form (Shaped) (Figure 5).

On the teeth of III group, which had rag surface and partially, damaged cutting edge have been found destruction of interprismatic spaces. These changes are occurred not only within interprismatic areas but it penetrated to deeper portion of enamel.




Figure 5. II group the comparison group. Stain Shaped amorphous zone between the prisms. Thionine, 240

On the section of teeth with fluorosis was seen the chalky strip. These strips can achieve of 3/4 thickness of enamel, and differs the “chalky-spot” structure from normal enamel (Figure 6).



Figure 6. II group the comparison group. “Spot” zone of enamel. The investigations showed that all of noted changes are readily occurred more on the cervical region of teeth. Thionine 400

The changes reached to DEJ (Figure 7).




Figure 7. II group comparison group. “Moire” structures at the enamel. Hematoxylin-eosin, 400

In the III group, as it is noted before, the animals received water with contents of fluorine 15 mg/liter and glutamic acid 2 times per one week. The color of teeth was yellow-brown, consistation –hard and the zone with local depigmentation, chalky strips, spots, recorption and destruction are not revealed (Figure 8).

On the section the prisms have many-sided form, between them crystals of hydroxiappatities and sticking fluid are observed (Figure 9).

Optically hard strips placed perpendicularly to enamel are found (Figure 10).

So, the histological investigations did not reveal destruction, resorbition, depigmentated zone on the animals, which received water with the contents fluorine 0,30-0,45 mg/l. The infringement of direction of enamel prism is not occurred. In result, the course of Sroger line changed, and absence of direction at the some zone is observed.

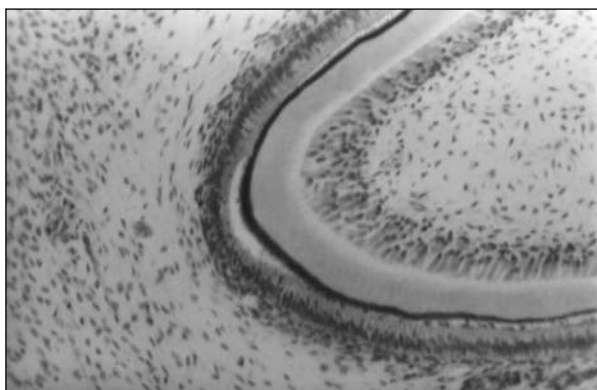


Figure 8. III group main group. The enamel without zone of depigmentation, resorption and destruction. On the tooth section the prism are both indirect and S- formed. Enamel line was not affected. Hematoxylin-eosin, 240




Figure 9. III group – main group. Enamel line keeps its normal structure. This line exactly is revealed at neck of teeth. Between line and layer of enamel was occurred deep proves (perixima). Thionine, 400

The hidroxiapatities formed “moiré” – shaped structure, and between them have been found unstructured mass, i.e. we come to conclusion that researched pathology must first be associated with disturbance in the process of organization structure of enzymes, and must not be associated with process of mineralization. The finding characteris-

References

1. Alimckiy A.V., Aliyeva R.K. The indications of caries and fluorosis among school men, was born and living in the region of Azerbaijan with different level of fluorine in the drinking water, *Stomatologiya*, 2000; **2**:40-42.
2. Qrexova T.D., Kacnelson B.D., Kolmogradova V.M., et al. The estimation of glutamic acid on the correlation of early manifestation of professional fluorosis. *Medicine of work and industrial ecology*, 1994; **8**: 20-23.
3. Nikolishin A.K. Tooth fluorosis. Avtoreferat diss. doc. of med. Science, Poltava, Moskwa, 1989; p. 30.

tic for II group: the expanding of interprismatic spaces, the widening of prism, the zone of depigmentation, erosion and spots.

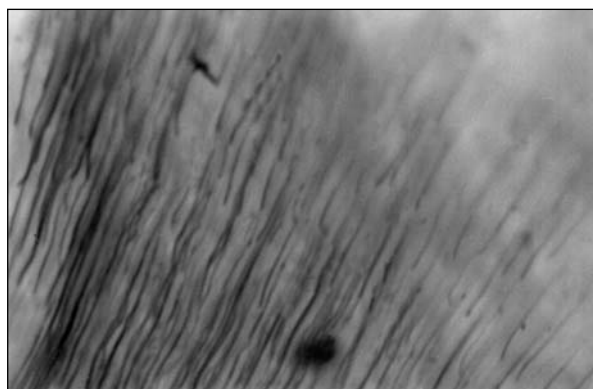


Figure 10. III group – main group. The normal stripness of enamel. Thionine, 400

In comparison with II group, on the teeth of animals receiving water with 15 mg /l of fluorine and glutamic acid were not revealed infringement. So, adding to water glutamic acid prevents the penetration and retention of NaF within teeth, and it blocked the teeth against chemical exchange within them. As a result is preventing the formation of heterogeneous structure within teeth.

Conclusions

1. The receive water the contents of fluorine 15 mg/l result in depigmentation of tooth enamel and histological change characteristic for the experimental dental fluorosis.
2. To added of glutamic acid to ration of animals result in prevention o dental fluorosis on the teeth. This amino acid prevents the appearance of metabolic change during introduction o high level of fluorine.
3. The results of our investigation are interesting for improvement of individual prophylaxis method again fluorosis or the people living on the endemic fluorosis region.

4. Shgoev V.A. The treatment and preventive influence of glutamic acid on the inalation hazardous effects of neorganic fluorine substances. *Hyghine of work*, 1998; **12**:26-30.
5. Yanovskiy L.M. Teeth fluorosis in the Pribaikolye, *Stomatologiya*, 2003; **4**:55-59.
6. Bowen W.N. Fluorosis: is it realy a problem? *J. Am Dent Assoc.* – 2002 oct. Vol **133** (10):1405-1407.
7. Chobisa S.L., Choubica L., Choubica D.K. Endemic fluorosis in Rajasthan, *Indian J. Environ Health*, 2001 Oct., Vol **43**(4):177-189.

Correspondence to: Prof. Chingiz Pashayev, Head of Department of Therapeutic Dentistry, Azerbaijan Medical Universitety. Baku. Azerbaijan, AZ 1078, Abbas Sahhet str. 25, fl 2. E-mail: aga70@bk.ru.