

The Prevalence of Pneumocystis in Lung Tissue of Kenyan Children Who Died Following Severe Respiratory Infection

Irum Beg Mirza^{1*}, Andrew Kanyi Gachii², Patricia Okiro¹ and Sherif Zaki³

¹Department of Laboratory Medicine, Aga Khan University Hospital Nairobi, Kenya

²University of Nairobi, Kenya

³Center for Disease Control and Prevention, Infectious Disease Pathology Branch, NCEZID Atlanta, GA

*Corresponding author: Irum Beg Mirza, Department of Laboratory Medicine, Aga Khan University Hospital Nairobi, Kenya, Tel: +254721888589; E-mail: irumbeg74@gmail.com

Received date: September 13, 2018; Accepted date: October 17, 2018; Published date: October 24, 2018

Copyright: © 2018 Mirza IB, et al. This is an open-access article distributed under the terms of the Creative Commons Attribution License; which permits unrestricted use; distribution; and reproduction in any medium; provided the original author and source are credited.

Abstract

Background: Children in Sub-Saharan Africa have a high mortality rate from Severe Acute Respiratory Infection (SARI). The prevalence of *Pneumocystis jirovecii* in Kenyan children is not known. We aimed to determine the prevalence of Pneumocystis in lung tissue of children below 5 years of age who died following admission for SARIs in Kenyatta National Hospital, a referral hospital in Nairobi.

Objectives: To determine the prevalence of Pneumocystis in children who died following SARI over a two year period from January 2015 to December 2016. Histological description was undertaken to identify changes in lung tissue in SARI with emphasis on presence of Pneumocystis.

Methods: Methods of 138 children with fatal respiratory infection at Kenyatta National Hospital, 64 consented autopsies were performed. Lung samples were stained with Haematoxylin and eosin (H and E) and Grocott's Methenamine Silver stain (GMS), to identify Pneumocystis.

Results: Pneumocystis has 17% prevalence by GMS in lung samples from children who died following SARI. Children between 0-6 months comprised 41% of the total number autopsied, out of which 31% were positive for Pneumocystis. In the 7-12 month old category only 9% were Pneumocystis positive. Children between 13-24 months comprised 23% of the autopsies, amongst whom 7% showed presence of Pneumocystis. All children who died following admission for SARI in this cross-section were less than 2 years old.

Conclusions: Mortality following admission for SARI and prevalence of Pneumocystis decreased with increasing age. A prevalence of 17% Pneumocystis was seen in lung tissue of the 64 children who died following admission for SARI. Pneumocystis colonisation and Pneumocystis Pneumonia should be a consideration in children who present with SARIs particularly in 0-6 month age group, regardless of HIV status. Further studies are warranted to better understand the implication of presence of Pneumocystis in lung biopsies in children for insight into its precise contribution to lung pathology.

Keywords: Pneumonia; Sub-Saharan Africa; Child-mortality; Respiratory fungi; Fatal outcome; Opportunistic infection

Introduction

In Kenya, acute respiratory infections and Pneumonia remains one of the leading causes of child mortality according to UNICEF 2014 reports by the UN interagency groups for child mortality estimation [1]. Since 50% of severe Pneumonia in Africa is attributed to *Haemophilus influenzae b* and *Streptococcus Pneumoniae* [2]. The Kenyan government initiated vaccination programs for *Haemophilus influenzae b* in 2001 and pneumococcal conjugate vaccine in 2011 as a preventive measure. These vaccines were implemented in the Expanded immunization program in collaboration with GAVI (Global Alliance for Vaccines and Immunization) to curb morbidity and mortality from Pneumonia. Despite these efforts, respiratory illness continues to claim the lives of Kenyan children. Establishing the precise aetiology of Pneumonia is challenging because of a large

variety of pathogens (bacteria, viruses and fungi) as well as low diagnostic capacity in most laboratories. There is often untimely patient management, augmented by poor access to health care and inadequate resources. Africa also bears a high burden of HIV and poverty-related factors such as malnutrition and overcrowding that predispose to Pneumonia [3]. Pneumocystis is a fungus known to cause severe respiratory disease particularly in immunocompromised individuals, attributable to a deficiency in cell mediated immunity [4]. It causes high mortality in HIV positive children and is well documented in immunocompromised children between 0-6 months of age. High numbers of AIDS cases in Sub-Saharan Africa make Pneumocystis a pathogen of public importance in this region [5] and limited access to prophylaxis or anti-retroviral drugs further predispose immunocompromised individuals to Pneumocystis Pneumonia (PP). A CD4+ cell count below 200/ μ l is considered a significant risk factor which requires prophylaxis against Pneumocystis in both adults and children under 6 years [5]. However, CD4+ counts in children aged less than 1 year are generally below normal, and

children may acquire Pneumocystis at higher CD4+ counts than adults since their immune system is relatively immature. It is also known to frequently cause fatal Pneumonia in immunocompromised children between 3-6 months of age, which is coincidentally a period when HIV status is undetermined [5]. Pneumocystis is a fungus that exists worldwide and causes both medical and economic burdens [6]. It has been regarded as uncommon in Sub-Saharan Africa with postulates of a lack of suitable types in the African environment or following difficulties in diagnosis or perhaps death from other organisms prior to severe immunosuppression [7].

Transmission and host response to Pneumocystis

Pneumocystis is transmitted via airborne route and afflicts alveoli with preference for type 1 pneumocytes. Pneumocystis may cause disseminated infection in severely immunocompromised patients or in cases with overwhelming infection however, this is exceedingly rare [8]. In host inflammatory responses and alveolar macrophages often clear infection except in individuals with immunodeficiencies, AIDS and malignancy [8]. It is nevertheless a common infection that occurs very early in life [9]. Pneumocystis is an evident cause of life threatening Pneumonia based on variable host response patterns and has also been associated with serious lung diseases such as Chronic Obstructive Pulmonary Disease (COPD) [4,6,10]. Some studies associate Pneumocystis infection to Sudden Infant Death Syndrome (SIDS) [9,11].

Brief history

Pneumocystis was first described by Carlos Chagas in the 1900s in lung histology, [10,12] and later in time, it was found to cause 'plasmacell Pneumonia' in malnourished children in orphanages in Europe and Iran during World War II [13]. However, the most remarkable attention paid to Pneumocystis was in the early eighties when implicated to cause Pneumonia in the immunocompromised, thus becoming the AIDS-defining illness during the early years of the AIDS epidemic [10,14-16]. After 1989 the incidence of Pneumocystis dropped due to the introduction of prophylaxis medication and a few years later in 1992, its prevalence once again showed a reduction by 3.4% per year following introduction of anti-retroviral therapy for HIV [5]. Pneumocystis continued to affect 20,000 new AIDs cases per year in United States despite the use of anti-retroviral therapy and prophylaxis against Pneumocystis. To date, it is the most devastating opportunistic organism in HIV positive persons and remains one of the most serious opportunistic infection in this population. Pneumocystis is among the most common opportunistic infection in developed countries [17]. It has been documented as the commonest opportunistic infection in HIV infected children [18]. The Multinational Antiretroviral Therapy Cohort Collaboration (ART-CC) established in 2009 rated Pneumocystis Pneumonia as the second most frequent AIDS-defining condition after oesophageal candidiasis [10] despite widespread use of anti-retroviral therapy and an undisputed decrease in Pneumocystis incidence over time. The greatest burden of HIV is borne by Sub-Saharan Africa yet data on Pneumocystis from this region is scarce. The epidemiology of Pneumocystis is changing over time as there is a rising population of surviving immunocompromised people and survivors of solid organ transplants as well as numerous people on chemotherapy [12,15]. Pneumocystis is no doubt an emerging infectious disease of epidemiological importance. Respiratory Distress Syndrome (RDS) is a known cause of morbidity and mortality particularly in premature infants and a recent

study has demonstrated that RDS is significantly increased in infants who harbour *Pneumocystis jirovecii* suggested to cause surfactant depletion hence altering surface tension, as noted in animal models [19].

Time of infection and colonisation

Humans are known to be exposed early in life and often remain asymptomatic or present with mild upper respiratory infections [11]. The presence of Pneumocystis is therefore not limited to immunosuppressed individuals, nor is it limited to adults. Evidence of prior infection has been documented in immunocompetent children via serological testing in a previous study demonstrating 94% detectable antibody in children between 30 months and 4 years of age [8]. The concept of colonization documented by Beard et al. in a study that used PCR to detect mitochondrial large subunit rRNA of Pneumocystis in lung tissue of infants and detected 100% positivity for Pneumocystis in 58 immunocompetent children from 5 US cities below 1 year of age, who died of various other causes [14]. Another study conducted on Danish children showed 16% hospitalized infants were Pneumocystis positive upon molecular testing of nasopharyngeal aspirates [19,20]. Of note, the infants were all HIV negative with 48% between 50-112 days old [20]. Larsen et al. found that healthy infants with URTI harbour Pneumocystis in their respiratory tract and more children with URTI carried Pneumocystis than those with LRTI [20]. Healthy adults also show high seroprevalence for Pneumocystis as seen in more than half the adult population in Chile testing seropositive for Pneumocystis [21].

Role of immunity in Pneumocystis infection

Pneumocystis although frequently detected in immunocompromised individuals is not limited to this population [22] and there exist carriers of latent organisms within the general population. The high detection in immunocompromised individuals certainly suggests that host immunity is imperative in the clearance of this organism from host lung tissue. Murine studies confirm that Th-17 immunodeficient mice showed delayed clearance of Pneumocystis from their lung tissue [12]. Also, CD-4 T cell lymphocyte counts are noted to be inversely proportional to the prevalence of Pneumocystis Pneumonia [12]. Thus it is convincing that immunity plays a major role in the survival of Pneumocystis or progress to Pneumocystis Pneumonia within a host. Cytomegalovirus (CMV) results in severe T-cell immunosuppression of the host by this virus [23] creating an opportunity for concurrent Pneumocystis infection. CMV has commonly been seen with Pneumocystis in lung biopsies. The discovery of PCR technology brought further insight into the concept of colonisation (carrier state) of Pneumocystis [18]. Colonisation implies the existence of subclinical infection with Pneumocystis without progress to clinical disease. This state of latency shows mere presence of the organism however the precise pathology or effect of its presence in lung tissue is still not clear. It is postulated that local inflammatory effects may be detrimental [15]. Non-clinical infections create a carrier-state of Pneumocystis serving as a reservoir of the organism within populations. This carrier state may even progress to Pneumocystis Pneumonia depending on host factors and immunity. The role of host immunity in the pathology of Pneumocystis is exhibited by an exaggerated immune response in the Immune Reconstitution Syndrome (IRIS) when opportunistic Pneumocystis results in a surge of immune mediators following antiretroviral therapy in HIV positive individuals leading to worsening symptoms following

reduction of immunosuppression [12]. Colonisation has been reported to be as high as 69% in HIV infected people [15]. A post-mortem study by Soeiro et al. in HIV positive adults in Brazil implicates Pneumocystis as the second most frequent organism (after bacterial Pneumonia), to be identified in HIV patients who die of acute respiratory failure (ARF) seen in 27% (68 cases) of 250 autopsies [24]. Studies in Thailand (HIV patients under treatment) and South America show high prevalence in HIV-patients with figures of 40% to 55% respectively [5,25,26].

Pneumocystis in Africa

Pneumocystis is thought to be rare in African populations but these low estimates may be attributable to limited diagnostic resources, death from other causes, environmental and seasonal differences, the presence of different Pneumocystis strains and perhaps a resistant population. Resistance to Pneumocystis, is a possibility as seen in a study that found African-Americans are less affected than white Americans [5]. Further studies are required to support these findings. Pneumocystis has long been considered more of a bystander organism in non-immunocompromised individuals [20]. This organism displays a wide spectrum of presentations from asymptomatic, mild infection to Pneumocystis Pneumonia in the immunosuppressed [4]. The evidence of its existence in healthy persons follows the introduction of polymerase chain reaction (PCR) that has helped to identify colonised people. Colonisation is defined as individuals carrying Pneumocystis yet have no clinical disease and do not progress to active clinical disease either [5]. These persons are reservoirs of Pneumocystis with potential to spread infection.

Previous studies in Africa

According to Vargas et al. Pneumocystis is the most prevalent microorganism identified in lungs of infants autopsied [11]. The most comprehensive autopsy study in Africa, on fatal respiratory infections was conducted on 264 children in Zambia [27]. Children were aged between 1 month and 16 years. Lung diseases frequently identified included pyogenic Pneumonia, Pneumocystis Pneumonia and tuberculosis (44%, 22% and 20%) respectively. Chintu et al. observed that 52 children out of the 58 with Pneumocystis were HIV positive. In children between 1 and 5 months the most common infection in Zambia, is Pneumocystis in HIV positive cases and acute pyogenic Pneumonia in HIV negative children [27]. Children above the age of 6 months suffered acute pyogenic infection more commonly. Chintu et al. however observed that Pneumocystis is the second most common infection in all age groups with positive HIV status. This study from Zambia, demonstrated 15 out of the 58 cases (26%) had Pneumocystis as a sole finding. As an outcome of the study Chintu et al. recommended UNAIDS guidelines for Pneumocystis prophylaxis needed revisiting as African children showed Pneumocystis as a significant cause of death [27]. Soeiro et al. investigated 250 autopsies of HIV/AIDS patients with acute respiratory failure for their aetiology and histopathologic findings to elucidate the pathophysiologic mechanisms involved in AIDS-related disease [24]. The findings revealed bacterial Pneumonia as the most frequent lung pathology but 27% autopsies (68 cases) showed Pneumocystis Pneumonia as a second most common infection surprisingly more common than tuberculosis [24].

Pneumocystis in Kenya

At present, Kenyan data is limited to a study conducted on 51 adults at Mbagathi hospital by Chakaya et al. and observed a significant increase in the prevalence of Pneumocystis from 2% in 1990 to 37% in 2003 [7]. However, this data is limited to a group of symptomatic adults with clinical and radiological features of Pneumonia in a background of immunosuppression by HIV. The cohorts were 37.2% adults initially suspected to have tuberculosis but negative for Acid Fast Bacilli (AFB) on testing therefore screened for Pneumocystis. These adults with negative AFBs underwent a fibreoptic BAL as their radiological findings showed bilateral pulmonary shadows suspicious for infections. They were found to have Pneumocystis by immunofluorescence on their BAL and sputum samples [7]. Patients in this adult cohort were from both sex and 27% men and 37% women were positive for Pneumocystis [7]. Mortality was higher in the HIV positive population [7]. A Kenyan autopsy study by Rana et al. on 122 autopsies found tuberculosis to be the main infection in HIV positive cadavers and bacterial Pneumonia in HIV negative cadavers whereas Pneumocystis was found to be rare (n=3, 4%) in the HIV positive cadavers (n=75) and was not found at all in the remaining autopsies who were HIV negative [28]. Difficulties in diagnosing Pneumocystis and a low index of suspicion in children presenting with severe respiratory tract infections hampers comparative studies in children despite evidence that children in other populations have shown higher rates of Pneumocystis than adults necessitating such investigations [3,15].

Histology of Pneumocystis

The most frequent histological appearance in Pneumocystis is an eosinophilic intra-alveolar foamy exudate with mild plasma cell interstitial infiltrate. Cysts of Pneumocystis are identified with special stains like toluidine-O and Grocott's methenamine silver stain. Cysts can be seen lying within the foamy exudate. Electron microscopy displays trophozoites within these exudates [29]. Unusual histological appearances can occasionally be seen as granulomatous Pneumonia or diffuse alveolar damage [29]. Most early data on Pneumocystis was obtained from post-mortem studies since transbronchial biopsies are rarely done due to the high risk for pneumothorax and haemorrhage. Furthermore, the yield would often be low in transbronchial biopsies discouraging its utility [29]. BAL has a higher yield and better diagnostic sensitivity and specificity than bronchial biopsies but histological changes cannot be evaluated by this method [29].

Material and Methods

Training was undertaken at Kenyatta National Hospital in Nairobi, to attain the highest autopsy standards and use of aseptic techniques for lung biopsy acquisition, handling and processing. Trainings incorporated a team of pathologists and senior residents of pathology to enable perfection in standard operating procedures particularly in autopsies and sample collection. Discussion forums were conducted at intervals to share data and involved academic discussions case by case with a team of pathologists, pediatricians, researchers and technicians. The study population included all children aged 0-59 months of age who died following admission for severe acute respiratory infection (SARI) in the wards (ICU, HDU and children's ward). SARI was defined as any history of 11 reported or measured fever of $\geq 38^{\circ}\text{C}$ or hypothermia (for children below 12 months), and a cough severe enough to warrant admission to hospital. This autopsied population was selected from children who died following SARI but were enrolled

upon admission for SARI. Strict inclusion criteria was abided to for ideal tissue sampling: 1. Children aged 0-59 months of age who died following admission for SARI, provided the body of the deceased was refrigerated within 8 hours of their demise and autopsy interval did not exceed 5 days. 2. Lung biopsy collected appropriately and immediately fixed in formalin at the time of autopsy. Selected lung tissue samples from each lobe of both lungs were collected at the time of autopsy and immediately fixed in formalin in order to prevent autolysis. Formalin devitalized infectious material and stabilized tissue components, enhancing its avidity for dyes. Contamination of lung tissue during autopsy was excluded by immediate acquisition upon opening the chest cavity using sterile forceps and scissors for each lobe. Specimens were designated a unique accession number and all five lobes were placed in a single cassette. Cassettes measure 3 × 2.5 × 0.4 cm and each tissue fragment approximately 0.3 cm or less was processed, to fit into a single cassette and onto a single slide for standard microscopy. A second cassette was prepared from specific abnormal looking areas. The presence of Pneumocystis in lung biopsies was evaluated using Grocott's Methenamine Silver (GMS) stain with and observation for distinctive histopathologic alterations in lung tissue using direct observation microscopy. A flow chart depicting the SARI cases triaged for autopsy is shown in Figure 1.

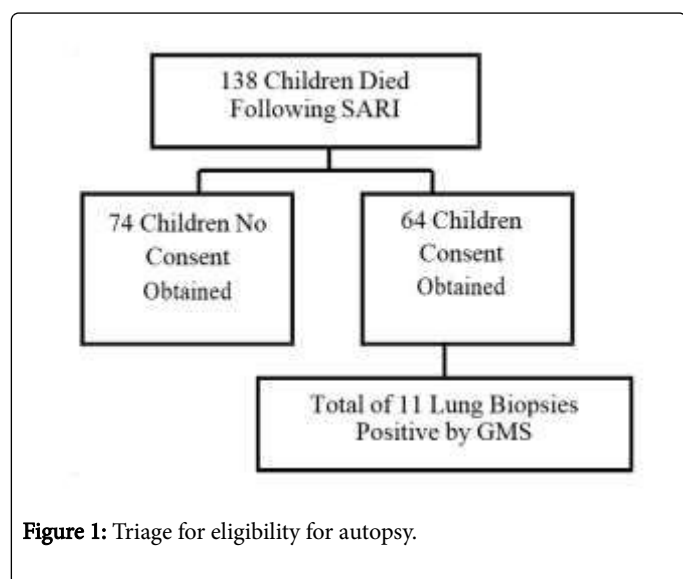


Figure 1: Triage for eligibility for autopsy.

Results

Between January 2015 and December 2016, 138 children died at KNH following admission for severe acute respiratory infections. Out of the 138 cases, 64 met the criteria for a medical autopsy to be performed to ascertain cause of death and to determine presence or absence of Pneumocystis in their lungs. The remaining 74 cases were not included for autopsy due to socio-cultural reasons and lack of consent. These results are from lung biopsies from all of the 64 cases that underwent autopsy and ages ranged from 1 month to 24 months. Socio-demographic data included the sex and HIV status of each child and was also abstracted from patient's files before their demise, to correlate with presence versus absence of Pneumocystis (Table 1).

Characteristics	Frequency	Percent
Age-Group		

Median age in months (IQR)	7	
0-6	26	40.6
7-12	23	35.9
12-24	15	23.4
Sex		
Male	31	48.4
Female	33	51.6
HIV status		
Positive	5	7.8
Negative	59	92.2
GMS results		
Positive	11	17.2
Negative	53	82.8

Table 1: Socio-demographic characteristics of children aged 1-24 months who have Pneumocystis.

SARI autopsy findings

Most of the children in this cross-section had one or more comorbidity known prior to their death. These conditions are summarised in Table 2. Comorbidities included malnutrition of with almost half the children, 28 out of the 64 cases demonstrated deranged Mid Upper Arm Circumference (MUAC) measurements indicating clinical malnutrition. However, only 3 of the 28 malnourished children had Pneumocystis in their lung biopsies. Previous studies report a higher incidence of Pneumocystis in children with malnutrition [3,23,30]. Despite a variety of comorbid conditions, it was noted that cases were few in this cross-section to correlate to presence of Pneumocystis. Table 3 shows a list of preliminary autopsy diagnoses for cases that tested positive for Pneumocystis via GMS. Some of the children also had underlying conditions that were confirmed at autopsy. Refer to Table 4 which shows various conditions noted during autopsy of the total cross section of 64 children, 11 (17%) children showed definite Pneumocystis with GMS staining of lung biopsies while 53 (83%) cases were negative. The median age of children in the study was 7 months (IQR 4-12 months). Children were categorised into age ranges of 0-6 months, 7-12 months and 12-24 months for ease of analysis. These ranges were selected following trends in previous studies. None of the children in this study exceeded two years of age. Since 74 of the 138 children who died of SARI were lost to sampling, data on their ages was availed and noted to be between 1-24 months comparable to the autopsied cross-section except for one child who was 55 months old (exceeded two years of age).

Comorbidity	No. of Cases
Malnutrition	28
Prematurity	8
Heart Disease	6
Liver Disease	1

Myeloproliferative Disorder	1
Hydrocephalus	1
Downs Syndrome	4
Cerebral Palsy	2
Developmental Delay	1
Multiple Congenital Disorders	1
Rickets	1
HIV	5
Congenital CMV	1
Sickle Cell Disease	1
Renal Failure	5
Aspiration	3
Meningitis	2

Table 2: Comorbids in autopsied children.

Case number	Age of child	Sex	Exposure to second hand cigarette smoke	Exposure to second hand cigarette smoke	Preliminary diagnosis
5	2 months	male	no	LPG gas	Underlying obstructed inguinal hernia with diagnosis of severe Pneumonia.
6	15 months	female	no	Data N/A	Underlying malnutrition and generalised sepsis with Severe Pneumonia.
7	1 month	male	no	Kerosene/paraffin	Underlying Prematurity with underdeveloped kidney and malnutrition. Sepsis Pneumonia and acute renal failure.
14	5 months	male	no	charcoal	No underlying illness but Gastroenteritis with severe Dehydration.
15	7 months	male	no	Kerosene/paraffin	No underlying illness but gastroenteritis with severe Pneumonia.
16	2 months	male	no	Kerosene/paraffin	Underlying congenital disease) PDA heart with respiratory failure (ARDS).

17	4 months	male	no	Kerosene/paraffin	Underlying ileocecal intussusception and HIV with Severe Pneumonia and respiratory failure (ARDS).
19	3 months	male	no	charcoal	No underlying conditions but enteritis, severe Pneumonia and respiratory failure (ARDS).
34	2 months	female	no	Kerosene/paraffin	Underlying HIV with interstitial Pneumonia.
43	3 months	female	no	Kerosene/paraffin	Underlying prematurity moderate malnutrition and severe interstitial Pneumonitis.
56	10 months	female	no	Kerosene/paraffin	Underlying severe malnutrition rickets, developmental delay with Pneumonia.

Table 3: Grocott's positive cases versus preliminary autopsy diagnosis.

Condition	No. of Cases
Malnutrition	28
Gastroenteritis	17
Dehydration	16
HIV	8
Disseminated Tuberculosis	2
Parasitic Infections	2
Head Injury	5
Congestive Cardiac Failure	3
Abdominal Injury	1

Table 4: Underlying conditions noted at autopsy.

GMS results and socio-demographic data

Of the 64 autopsied cases 11 were positive for Pneumocystis by histology and GMS staining. Table 5 demonstrates the bivariate relation between socio-demographic conditions and a positive Grocott's stain in autopsied children from this study. An almost equal number from either sex presented for autopsy with 48.4% (31 children) male and 51.6% (33 children) female with 4 (12.1%) females positive for Pneumocystis and 7 (22.6%) males positive for Pneumocystis however this data is statistically insignificant thus suggesting sex predilection for Pneumocystis is not possible from this data due to the low population of this cross-section.

Pneumocystis				
characteristics	Positive (%)	Negative (%)	Total (%)	Exact p-value
Age-group				
0-6	8(30.8)	18 (69.2)	26 (40.6)	0.08 (NS)
07-12	2 (8.7)	21 (91.3)	23 (35.9)	
13-24	1 (6.7)	14 (93.3)	15 (23.4)	
Sex				
Male	7(22.6)	24 (77.4)	31(48.4)	0.75(NS)
Female	4(12.1)	29(87.9)	33 (51.6)	
HIV status				
Positive	2(40.0)	3(60.0)	5(7.8)	0.2(NS)
Negative	9(15.3)	50(84.7)	59 (92.2)	

Table 5: Bivariate association between Pneumocystis (GMS stain) and sociodemographic factors.

HIV status

Data on maternal HIV status was available for 29 of the 64 children who were autopsied. Some of the maternal HIV status was unavailable due to refusal to test for HIV or absent mothers. Table 6 demonstrates the bivariate analysis of autopsied children who were exposed to HIV mothers and were GMS positive for Pneumocystis versus the exposed children who were exposed to HIV mothers yet negative for the organism in their lung biopsy samples. When maternal HIV status was compared to HIV-exposed and un-exposed children we found that one child was HIV exposed and Pneumocystis positive while 24 of the cases were HIV exposed and Pneumocystis negative. Majority children in this cross-section were HIV negative as well as non-exposed, out of which two were Grocott's 13 positive for Pneumocystis despite being non-exposed with negative maternal status. Our sample size is too small to accurately correlate the prevalence of Pneumocystis to HIV exposure status (Table 7).

Mothers HIV Status	GMS Positive Children	GMS Negative Children	Total Number of Children
HIV Positive	1(33.3)	2(66.7)	3(4.7)
HIV Negative	0(7.7)	24(92.3)	26(40.6)
Unknown Status	8(22.9)	27(77.1)	35(54.7)

Table 6: HIV exposure in entire population of autopsied children.

Case number	HIV status	Exposure to HIV (in mother)
5	Negative	N/A
6	Negative	N/A
7	Negative	N/A
14	Negative	N/A

15	Negative	N/A
16	Negative	Negative
17	Positive	N/A
19	Negative	N/A
34	Positive	Positive
43	Negative	Negative
56	Negative	N/A

Table 7: HIV status and HIV exposure in Pneumocystis positive children by GMS staining.

Refer to Table 7 for HIV status and HIV exposure in Pneumocystis positive children by GMS stain versus numerical individual cases. A unique observation in our study is the apparently greater proportion of Pneumocystis positive cases in HIV negative children with fatal outcome from SARI. Further studies are required on this subject. Refer to Table 8 for a summary of Grocott's staining in comparison to HIV status of the autopsied children. Nine of eleven (81.8%) of the Grocott's positive Pneumocystis cases were HIV negative children whilst two of these eleven cases were both Grocott's and HIV positive. By this limited data, a greater proportion of HIV positive children (81.8%) were GMS negative, another promising research area for enhanced scientific knowledge. This data does not suggest a trend due to sample size limitations.

HIV (child)	GMS Positive
HIV negative	9 (81.8%)
HIV positive	2 (18.2%)

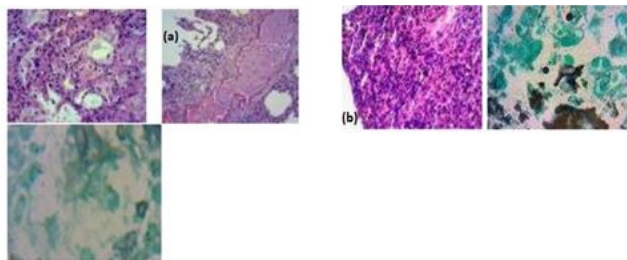
Table 8: HIV versus GMS positive for Pneumocystis on lung histology.

Histological findings and GMS positivity

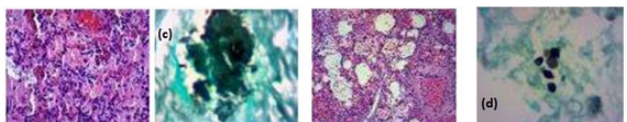
Histological findings were summarised into seven categories based on the most common findings encountered on H and E examination namely alveolar collapse, hyaline membranes alveolar exudates, pulmonary oedema, alveolar haemorrhage, chronic interstitial infiltrates, granular alveolar material. These are features derived from commonly identified patterns which favour the presence of Pneumocystis including: Diffuse Alveolar Damage (DAD): diffuse involvement of lung tissue and uniform temporal appearance of alveolar collapse, hyaline membranes, moderate to obliterated fibrosis and neo-septa formation.

- Pulmonary oedema (PE): accumulation of proteinaceous fluid in the alveolar spaces, with appearance of a granular, pink coagulate within alveoli
- Alveolar haemorrhage (AH): presence of blood in alveolar spaces

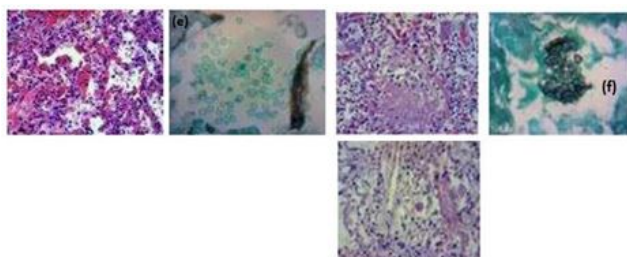
Acute interstitial Pneumonia (AIP): widened and oedematous alveolar septa, often accompanied by mononuclear inflammatory infiltrate of lymphocytes, histiocytes, plasma cells, and neutrophils (Figure 2 (a-j)).



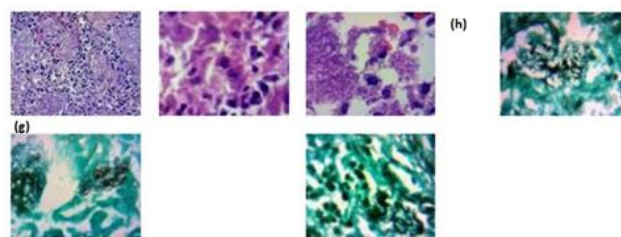
(a) Case 5: 2 months old, male: Interstitial widening by chronic inflammatory infiltrates seen in lung tissue. GMS showed cysts consistent with morphology of Pneumocystis. **(b) Case 6: 15 month female:** Prominent Bronchus Associated Lymphoid Tissue (BALT). Varied histological findings in each lobe. Multiple foci of basophilic cocci and bacilli in clustered colonies were noted. GMS showed scanty focal Pneumocystis cysts.



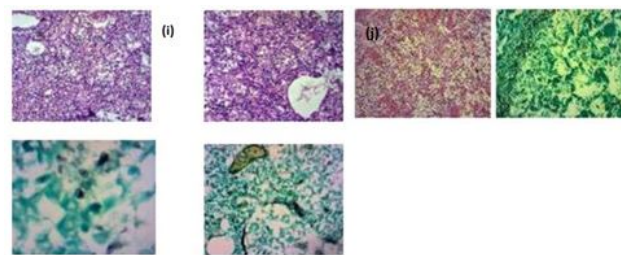
(c) Case 7: 1 month male: Prominent interstitial inflammation with focal pulmonary oedema. Interstitial Pneumonia and focal haemorrhage. Features of Meconium aspiration syndrome noted. GMS showed clusters interpreted as positive for Pneumocystis. **(d) Case 14: 5 month male:** Patchy interstitial inflammation GMS stain showed Pneumocystis cysts with central indentation.



(e) Case 15: 7 month male: Mixed infection observed, with heavy bacterial colonies, patchy interstitial inflammation, features of ARDS, GMS showed distinct Pneumocystis cysts intermixed with red blood cells within alveoli. **(f) Case 16: 2 month old, male:** Displayed frothy exudates within alveoli on H&E special staining with GMS showed Pneumocystis cysts. This case showed mixed aetiology with prominent owl-eyed cells consistent with CMV. Cells were large with a prominent basophilic nuclear inclusion, with a clear halo, and smaller basophilic cytoplasmic inclusion classical appearance of CMV cytomegalovirus.



(g) Case 17: 4 months old, male: Shows extensive foamy exudates on H&E, on staining with Grocott's methenamine stain cysts of Pneumocystis with indentation were highlighted confirming their presence within the exudates. Diffuse alveolar damage is noted in this case. **(h) Case 19: 2 months old, male:** Granular exudates were noted with surrounding interstitial inflammation and mild alveolar haemorrhage. GMS showed classic Pneumocystis cysts.



(i) Case 43: 3 months old female: Acute Interstitial inflammation with remarkable intra alveolar frothy exudates. Interstitial vessel were dilated however no haemorrhage was appreciate. A GMS showed classic Pneumocystis cysts. **(j) Case 56: 10 month female:** Patchy interstitial inflammation was noted with no other significant histological changes associated with damage however GMS stained for cysts of Pneumocystis. **Figure 2 (a-j):** Positive for Pneumocystis on histology and special staining with GMS.

Granular material implies denser eosinophilic intraalveolar material within which is seen macrophages and disquamated alveolar lining cells. In case 5 and 56 organisms were found within the alveoli with minimal (inconspicuous) alveolar exudates. The bar chart in Figure 3 depicts the number of cases noted for each of the histological findings defined above for qualitative analysis of microscopic lung changes associated with the presence of this fungus within lung tissue. On qualitative evaluation of microscopic patterns we noted the least common pattern seen on microscopy is the presence of hyaline membranes and most common patterns are alveolar exudates and interstitial inflammation in lung tissue infected with Pneumocystis.

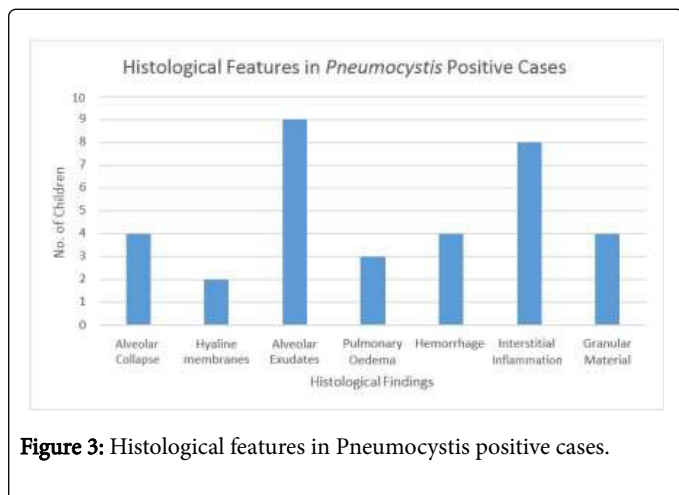


Figure 3: Histological features in *Pneumocystis* positive cases.

Pictorial data

Microscopic evaluation also detected incidental lung pathology that contributed to the demise of these children including aspiration, thrombosis following Disseminated Intravascular Coagulation (DIC), bacterial infections, tuberculosis and viral infections. Pictorial data was constructed following visualization of interesting findings on microscopy which were photographed by slide imaging techniques and saved as a digital library. Five lung biopsies were found to have *Pneumocystis* alone as the offending organism however molecular studies and clinical correlations may help detect the possibility of other pathogens in these cases (Figure 4 (a-f) for histological images of suspicious cases negative for definitive cysts on special staining following deeper sections and repeated evaluation). One of the cases demonstrates co-infection with Cytomegalovirus (CMV). Two cases are positive for acid fast bacilli highlighted via Ziehl-Neelsen staining for mycobacteria however are both negative for *Pneumocystis*. The Grocott's- methenamine stain is positive for other fungi in ten lung tissue biopsies. Of these cases, three of them appear morphologically consistent with *Aspergillus* infections displaying fruiting bodies and septate hyphae with 45 degree branching patterns and the remaining cases are defined as unknown fungi on morphology alone. Heavy bacterial infection microscopically detected as large basophilic colonies is seen in samples from four of the 64 children autopsied. These organisms were not cultured as this was out of the scope of this study.

(a) Case 1: 7 months female: Interpreted as 'other fungus' by fungal morphology which showed budding and darker silver staining not consistent with classical appearance of *Pneumocystis*. **(b) Case 18: 4 months female:** Interpreted as 'strongly suspicious for *Pneumocystis*' on histology, however no cysts seen on GMS'. Frothy exudates were present.

(c) Case 28: 4 months female: Prominent alveolar haemorrhage with interstitial Pneumonia. No alveolar exudates noted. **(d) Case 33:** Interpreted as suspicious on histology. No cysts seen even on recutting and restaining.

(e) Case 48: 9 months female: Patchy necrotizing picture with vague granulomas, suspicious for tuberculosis despite a negative ZN stain. Interpreted as negative for *Pneumocystis*, favour Tuberculosis. **(f) Case 61: 10 months female:** Interpreted as 'other fungus' which displayed narrow based budding.
Figure 4 (a-f): Cases which were histologically highly suspicious but negative for *Pneumocystis*.

Discussion

We found a prevalence of 17% of Pneumocystis in this cross-section of SARI children using GMS stain in lung biopsies from children. This is the first data of Pneumocystis in Kenyan children at a national referral hospital (KNH). Previous Kenyan data are limited to adults from a cohort of symptomatic adults in Mbagathi hospital in 2003 using bronchoscopy samples. The cohort of 51 HIV positive adults demonstrated 19 (37.2%) tested positive for Pneumocystis by immunofluorescence techniques [7]. Our study demonstrates 17% prevalence in Kenyan children less than 2 years of age. This data compares well with studies in Botswana with a prevalence of 11% (on 104 autopsied children) [30] and Ethiopia with a prevalence of 11% (119 sputum samples). Ansari et al. with a cohort of 47 children in Botswana, demonstrated Pneumocystis caused 8 of 12 deaths in HIV negative children. They showed Pneumocystis resulted in 31% of all deaths of which 48% deaths occurred in children below 1 year [31]. In Zambia, Chintu et al. demonstrated 6 of 84 (17.6%) HIV negative children [27] with Pneumocystis thus, compares well with our Kenyan cohort. Although an inaccurate comparison to make as our sample consisted of only two HIV positive children of the total of 11 children showing presence of Pneumocystis in their lung tissue. This is somewhat suggestive of a trend warranting further investigations, in view of the fact that majority of the children positive for Pneumocystis in our cross-section were HIV negative. This would however, require larger studies to investigate for significant correlation. The causes of death of children in this autopsy study varied in each case. But underlying conditions were few and the study was not powered to make such correlations. In summary, a prevalence of 17% children with Pneumocystis is noted by microscopy using special staining techniques with GMS. The most commonly affected age group is between 0-6 months demonstrating a percentage of 40.6% children with Pneumocystis in this age group. There is decreasing prevalence with increasing age, falling to 32.9% in 7-12 months and 23.4 % in the 12-24 months age groups respectively. There were no children above 24 months who presented for autopsy indicating a generally lower mortality from SARI in the above two year age hence determining the prevalence of Pneumocystis via this technique is not practical for over two years of age. Children in 0-24 age group have a higher risk of mortality if they present with SARI. With decreasing presence of Pneumocystis as children increase in age the question of the possibility of contribution to damage by Pneumocystis still exists. This could imply a pathological contribution by Pneumocystis which warrants in-depth scientific investigation. This study is not only the first documented prevalence of Pneumocystis in children in Kenya who die of SARI, but also demonstrates that Pneumocystis is prevalent in non-HIV/AIDS children. The children who were without comorbid and underlying conditions carried Pneumocystis more frequently than those with underlying conditions in this study. We have investigated its presence in lung tissue of all children who initially presented with respiratory illness irrespective of both their final cause of death at autopsy and their HIV status. We demonstrated two (18.2%) positive for Pneumocystis and HIV and 9 (81.8%) children Pneumocystis positive and HIV negative in this sample population and conclude that immunocompetent individuals also have a high prevalence of Pneumocystis in their lungs which may be latent infection but showed histological lung damage contributed by its presence. Molecular testing is known to have high sensitivity and good specificity and is a fairly suitable method of investigating for Pneumocystis, however is not infallible. We believe that due to Pneumocystis tropism for lung tissue autopsy studies are very reliable to confidently detect the incidence of

active infection and are a more reliable indicator of invasive disease compared to sampling of nasopharyngeal aspirates or oropharyngeal washes and investigating by molecular techniques. In our opinion, histologic identification is the gold-standard for "active" infection as it is a direct visualization of the organism within tissue biopsies and molecular techniques may detect cases that have cleared their lung infection, also possibly detecting non-viable Pneumocystis and may even detect false-positive cases. The clinical significance of Pneumocystis is still poorly understood [5] however colonization may lead to transmission within the population and lung damage in the host that may contribute to fatal outcome and therefore further investigations, preferable on lung biopsies is useful to better understand the organism's pathological damage at cellular level. We have not been able to correlate it to underlying medical conditions nor have we achieved an expected higher carrier-state in the HIV positive children. We cannot ascertain if lung damage noted on histology was solely caused by Pneumocystis however, we observed frequent alveolar exudates and interstitial inflammation in children carrying Pneumocystis in their lung tissue. We believe there is significant value in histopathologic studies to better define cellular damage by Pneumocystis which is currently poorly understood and can predispose carriers of this organism to accessory lung damage from other organisms or conditions perhaps amplifying the damage at cellular level. There is supportive evidence to this theory since Pneumocystis is seen more commonly in COPD (40).

Conclusion

This study concludes a prevalence of 17% of Pneumocystis in Kenyan children between 0-24 months who presented to a main referral hospital in Nairobi city. Our study demonstrates that Pneumocystis is common in children below two years of age and most prevalent between 0-6 months, decreasing in frequency with increasing age indicating higher susceptibility in a younger age group. Previous literature, suggests higher prevalence in HIV infected children compared to non-HIV infected children but our study shows latent infection exists irrespective of the HIV status. We suggest that the presence of Pneumocystis occurs independent of other comorbidity and underlying conditions. We acknowledge selection bias due to our sample size limitations as it was limited to children who died during the study period who met autopsy criteria as per our study protocol. Nevertheless, we believe Pneumocystis should be considered a potential comorbidity and investigated enthusiastically particularly in children between 0-24 months to further define histologic damage within lung tissue of sick children who succumb to lung pathologies comparing their histology to those who do not have Pneumocystis yet die from lung pathology. It would also be of value to genotype the organism in our children and compare it to genotypes elsewhere as well as comparing genotypes with those found in adults within our population. Pneumocystis contributes to morbidity and mortality and should be considered more than just a bystander organism whatever the immune status of colonized individuals [4]. Despite some study limitations we have made salient observations in this study which require consideration of the presence Pneumocystis in children presenting with severe respiratory infections even though it is a difficult diagnosis to make in view of the limited diagnostic testing for this organism on a routine basis. We suggest a high index of suspicion of presence of Pneumocystis when children present with respiratory symptoms particularly between 0-6 months of age, as appropriate intervention may contribute to improving survival in children presenting with respiratory illness in this age category.

Recommendations

We encourage necropsy studies which add value in fatal outcome and contribute greater insight into lung pathology at a cellular level. Autopsies highlight several incidental findings that no other investigative methods can demonstrate to the same magnitude and are therefore essential to enhance scientific knowledge. Identifying pathogens ante mortem is also limited by various factors including difficulty in sputum collection from children. Samples like bronchioalveolar wash are also challenging to obtain particularly in resource limited settings. Most children therefore die prior to investigation with the role of Pneumocystis in fatal respiratory infection less understood. Thus, it is useful to conduct post-mortem studies to obtain definitive diagnoses and to characterize its contribution to fatal Pneumonia.

Acknowledgments

We acknowledge the Centre for Global Health Research and KEMRI/CDC partnership for authorization of this study and support, encouragement and provision of equipment to conduct highly standardized autopsies for all the children included in this study. We wish to acknowledge the Mr. Maurice Otunga for his technical assistance ensuring high quality tissue processing skills and assisting with special staining techniques. We are also grateful for the assistance of CDC-PI, Henry Njuguna for involving residents in educational sessions and discussions in liaison with CDC and supervising and coordinating material flow during each autopsy. We appreciate James Orwa for his assistance in data analysis. We acknowledge Professor Rodney Adam (Infectious Disease Specialist, Department of Laboratory Medicine, Aga Khan University Hospital Nairobi, Kenya) for his general support and editing assistance. IM designed the study and wrote the manuscript. We are grateful to AG who supported and supervised autopsy sampling and PO who provided microscopic expertise. ZS for his expertise in microscopy and assistance in reviewing preliminary stages of this work.

Disclosure

The author reports no conflicts of interest in this work. This research does not incorporate without acknowledgement any material previously published or written by another person except where due reference have been made in the text.

References

1. George A, Rodríguez DC, Rasanathan K, Brandes N, Bennett S (2015) iCCM policy analysis: strategic contributions to understanding its character, design and scale up in sub-Saharan Africa. *Health Policy Plan* 30:I i3-ii11.
2. Turner GD, Bunthi C, Wonodi CB, Morpeth SC, Molyneux CS, et al. (2012) The role of postmortem studies in Pneumonia etiology research. *Clin Infect Dis* 54: S165-s171.
3. Ikeogu M, Wolf B, Mathe S (1997) Pulmonary manifestations in HIV seropositivity and malnutrition. *Arch Dis Child* 76: 124-128.
4. Nevez G, Magois E, Duwat H, Gouilleux V, Jounieaux V, et al. (2006) Apparent absence of Pneumocystis jirovecii in healthy subjects. *Clin Infect Dis* 42: e99-e101.
5. Morris A, Lundgren JD, Masur H, Walzer PD, Hanson DL, et al. (2004) Current epidemiology of Pneumocystis Pneumonia. *Emerg Infect Dis* 10: 1713-1720.

6. Schildgen V, Mai S, Khalfaoui S, Lusebrink J, Pieper M, et al. (2014) Pneumocystis jirovecii can be productively cultured in differentiated CuFi-8 airway cells. *Am Soc Microbiol* 5: e01186-e1214.
7. Chakaya JM, Bii C, Ng'ang'a L, Amukoye E, Ouko T, et al. (2003) Pneumocystis carinii Pneumonia in HIV/AIDS patients at an urban district hospital in Kenya. *East Afr Med J* 80: 30-35.
8. Thomas CF, Limper AH (2007) Current insights into the biology and pathogenesis of Pneumocystis Pneumonia. *Nat Rev Microbiol* 5: 298-308.
9. Vargas SL, Ponce CA, Hughes WT, Wakefield AE, Weitz JC, et al. (1999) Association of primary Pneumocystis carinii infection and sudden infant death syndrome. *Clin Infect Dis* 29: 1489-1493.
10. Huang L (2011) Clinical and translational research in Pneumocystis and Pneumocystis Pneumonia. *Parasite* 18: 3-11.
11. Vargas SL, Ponce CA, Gallo M, Pérez F, Astorga JF, et al. (2013) Near-universal prevalence of Pneumocystis and associated increase in mucus in the lungs of infants with sudden unexpected death. *Clin Infect Dis* 56: 171-179.
12. Eddens T, Kolls JK (2015) Pathological and protective immunity to Pneumocystis infection. *Semin Immunopathol* 37: 153-162.
13. Morris A, Sciarba FC, Lebedeva IP, Githaiga A, Elliott WM, et al. (2004) Association of chronic obstructive pulmonary disease severity and Pneumocystis colonization. *Am J Respir Crit Care Med* 170: 408-413.
14. Beard CB, Fox MR, Lawrence GG, Guarner J, Hanzlick RL, et al. (2005) Genetic differences in Pneumocystis isolates recovered from immunocompetent infants and from adults with AIDS: Epidemiological Implications. *J Infect Dis* 192: 1815-1818.
15. Morris A, Norris KA (2012) Colonization by Pneumocystis jirovecii and its role in disease. *Clin Microbiol Rev* 25: 297-317.
16. De Armas Rodríguez Y, Wissmann G, Müller AL, Pederiva MA, Brum MC, et al. (2011) Pneumocystis jirovecii Pneumonia in developing countries. *Parasite* 18: 219-228.
17. Lowe DM, Rangaka MX, Gordon F, James CD, Miller RF (2013) Pneumocystis jirovecii Pneumonia in tropical and low and middle income countries: a systematic review and meta-regression. *PLoS One* 8: e69969.
18. Madhi SA, Cutland C, Ismail K, O'Reilly C, Mancha A, et al. (2002) Ineffectiveness of trimethoprim-sulfamethoxazole prophylaxis and the importance of bacterial and viral coinfections in African children with Pneumocystis carinii Pneumonia. *Clin Infect Dis* 35: 1120-1126.
19. Rojas P, Friaza V, Garcia E, de la Horra C, Vargas SL, et al. (2017) Early acquisition of Pneumocystis jirovecii colonization and potential association with respiratory distress syndrome in preterm newborn infants. *Clin Infect Dis* 65: 976-981.
20. Larsen HH, von Linstow M-L, Lundgren B, Høgh B, Westh H, et al. (2007) Primary Pneumocystis infection in infants hospitalized with acute respiratory tract infection. *Emerg Infect Dis* 13: 66-72.
21. Ponce CA, Gallo M, Bustamante R, Vargas SL (2010) Pneumocystis colonization is highly prevalent in the autopsied lungs of the general population. *Clin Infect Dis* 50: 347-353.
22. Khalife S, Aliouat EM, Aliouat-Denis CM, Gantois N, Devos P, et al. (2015) First data on Pneumocystis jirovecii colonization in patients with respiratory diseases in North Lebanon. *Microbes Infect* 6: 11-14.
23. Morrow BM, Samuel CM, Zampoli M, Whitelaw A, Zar HJ (2014) Pneumocystis Pneumonia in South African children diagnosed by molecular methods. *BMC Res Notes* 7: 26.
24. Soeiro AdM, Hovnanian AL, Parra ER, Canzian M, Capelozzi VL (2008) Post-mortem histological pulmonary analysis in patients with HIV/AIDS. *Clinics* 63: 497-502.
25. Lumbiganon P, Kosalaraksa P, Loapaiboon M (2000) Survival of children with AIDS: experience in a university hospital in northeast Thailand. *J Med Assoc Thai* 83: 652-656.
26. Wannamethee SG, Sirivichayakul S, Phillips AN, Ubolyam S, Ruxrungtham K, et al. (1998) Clinical and immunological features of

-
- human immunodeficiency virus infection in patients from Bangkok, Thailand. *Int J Epidemiol* 27: 289-295.
27. Chintu C, Mudenda V, Lucas S, Nunn A, Lishimpi K, et al. (2002) Lung diseases at necropsy in African children dying from respiratory illnesses: a descriptive necropsy study. *The Lancet* 360: 985-990.
28. Rana F, Hawken M, Mwachari C, Bhatt S, Abdullah F, et al. (2000) Autopsy study of HIV-1-positive and HIV-1-negative adult medical patients in Nairobi, Kenya. *J Acquir Immune Defic Syndr* 24: 23-29.
29. Foley NM, Griffiths MH, Miller RF (1993) Histologically atypical *Pneumocystis carinii* Pneumonia. *Thorax* 48: 996-1001.
30. Ruffini DD, Madhi SA (2002) The high burden of *Pneumocystis carinii* Pneumonia in African HIV-1-infected children hospitalized for severe Pneumonia. *AIDS* 16: 105-112.
31. Ansari N, Kombe A, Kenyon T, Hone N, Tappero J, et al. (2002) Pathology and causes of death in a group of 128 predominantly HIV-positive patients in Botswana, 1997-1998. *Int J Tuberc Lung Dis* 6: 55-63.