

Research Article

Open Access

## The Occurrence of Spontaneous Lymphomas but Not Adenomas or Sarcomas in Rats Treated With Sustained Release Naltrexone

Erin Kelty<sup>1,3\*</sup>, Philip K. Nicholls<sup>2</sup>, George O'Neil<sup>1,3</sup>, Zoe Harrison<sup>3</sup>, Chin-Tark Chan<sup>1,3</sup>, Peter Symons<sup>3</sup>, Albert Stuart Reece<sup>1,4</sup> and Gary Hulse<sup>1</sup>

<sup>1</sup>Unit for Research and Education in Drugs and Alcohol, School of Psychiatry and Clinical Neurosciences (MDP 521), The University of Western Australia, Stirling Highway, Crawley, Western Australia, 6009

<sup>2</sup>School of Veterinary Biology and Biomedical Sciences, Murdoch University, South Street, Murdoch, Western Australia, 6150

<sup>3</sup>Go Medical Industries Ltd Pty, 200 Churchill Road, Subiaco, Western Australia, 6008

<sup>4</sup>Medical School, University of Queensland, St Lucia, Queensland, 4072

### Abstract

Naltrexone has been observed to have both a stimulatory and inhibitory effect on the development of tumours in rodents, potentially mediated by changes to the neuroendocrine system as a result of blockade of the opiate receptors, with the period of blockade and the tumour type thought to be influential. This study examined the occurrence of spontaneous tumours in rats treated with a sustained release naltrexone preparation. Materials and methods: 27 male and 27 female rats were randomized into three equal treatment groups (A, B and C). Rats in group A were implanted with a single naltrexone implant tablet, rats in group B were implanted with a single polymer implant tablet (placebo) and rats in group C underwent a sham procedure (control). Three different groups of spontaneous tumours were observed; lymphomas, adenomas and sarcomas. Lymphomas (4 tumours/3 rats) were observed solely in naltrexone treated rats, while adenomas (9 tumours/5 rats) and sarcomas (4 tumours/3 rats) were only observed in the placebo and the control groups. The data suggests that the association of naltrexone on the development of tumours maybe dependent on tumour type. Long term exposure to naltrexone appears to have both a stimulatory and inhibitory effect on tumours in rats, dependent on tumour type.

**Keywords:** Implant; Opiate antagonist; Tumours

### Introduction

Naltrexone is an opiate antagonist, primarily used in the treatment of opiate and alcohol dependence. Due to the opioid systems interactions with other systems, naltrexone has become a drug of interest in a number of different areas of research including substance dependence [1-3], autoimmune diseases such as Crohn's disease [4] and multiple sclerosis [5,6], compulsive behaviours such as kleptomania [7] and self-injuring behaviours [8,9], polycystic disease and infertility [10-12], glycaemic control in the metabolic syndrome [13-16] and cancer [17,18].

Research from the Pittsburgh group over several decades has demonstrated that tissue growth is under tonic opioid inhibition [24-26]. Hence opioid antagonists such as naltrexone stimulate tissue growth, and opioids themselves inhibit it in virtually all organ systems. This also applies to malignant tumours. In experimental systems in vitro and in preclinical models [27] naltrexone has been shown to stimulate the growth of tumours in the pancreas and squamous tumours of the head and neck, and to stimulate the growth of malignant cells in culture of the fibrosarcoma and neuroblastoma cell lines [28]. Indeed naltrexone's product information registered with the Australian Therapeutic Goods Administration documents increased rates of tumours of the breast in exposed rats [29]. However, naltrexone has been shown to have both stimulatory and inhibitory effects on the development cancers in rats and mice [18-22] associated with the duration to opiate receptor blockade, the dose and the period of administration [18,21]. In mice, single daily doses of naltrexone at low levels (0.1 and 0.4 mg/kg SC), resulting in partial blockade of the opiate receptors for periods of 4 to 10 hours have shown to significantly decrease the appearance of neuroblastomas (in mice inoculated subcutaneously with S20Y neuroblastoma), whereas equivalent doses given at multiple time points (4 x 0.1mg/kg SC) and larger doses (10 mg/kg SC) resulting in full blockade of the opiate receptors was associated with a decrease in the time taken for neuroblastomas to appear and increased the incidence

of tumours [21,23]. At high doses of 30 mg/kg/day and 100 mg/kg/day of oral naltrexone likely to achieve full receptor blockade, there is a reduction in the appearance of spontaneous pituitary adenomas and mammary fibroadenomas.

Oral naltrexone was approved by the US Food and Drug Administration (FDA) in 1984 for the treatment of opiate and alcohol dependence, however the clinical efficacy of oral naltrexone has been limited, primarily due to patient non-compliance with daily oral dosing regimes [24]. An alternative to oral naltrexone is the injection or surgical insertion of a sustained release preparation of naltrexone, which removes the onus on patients to use daily medication [25,26]. One such preparation is the O'Neil Long Acting Naltrexone Implant (OLANI) produced by Go Medical, using a biodegradable polymer to control the release of naltrexone. The OLANI is comprised of naltrexone loaded biodegradable polymer microspheres which, in humans, maintains blood naltrexone levels above 2 ng/ml for up to 6 months [27]. The development of sustained release naltrexone preparations for the treatment of opiate and alcohol dependence has increased interest in the potential stimulatory effects of sustained release naltrexone in relation to tumour development.

The effects of naltrexone on the development of tumours have been hypothesized to be related several mechanisms. The use of

**\*Corresponding author:** Erin Kelty, Go Medical Industries Ltd Pty, 200 Churchill Road, Subiaco, WA 6008, Australia. Tel: +61 8 9381 3226; Fax: +61 8 9382 4952; E-mail: [ekelty@gomedical.com.au](mailto:ekelty@gomedical.com.au)

**Received** November 25, 2011; **Accepted** January 02, 2012; **Published** April 21, 2012

**Citation:** Kelty E, Nicholls PK, O'Neil G, Harrison Z, Chan CT, et al. (2012) The Occurrence of Spontaneous Lymphomas but Not Adenomas or Sarcomas in Rats Treated With Sustained Release Naltrexone. Clin Exp Pharmacol 2:105. doi:[10.4172/2161-1459.1000105](https://doi.org/10.4172/2161-1459.1000105)

**Copyright:** © 2012 Kelty E, et al. This is an open-access article distributed under the terms of the Creative Commons Attribution License, which permits unrestricted use, distribution, and reproduction in any medium, provided the original author and source are credited.

small doses of naltrexone, providing short term opiate blockade is thought to reduce the presence of spontaneous tumours through the up-regulation of met-enkephalin, involved in the regulation of tissue and regeneration. Increase in met-enkephalin delays the replication of cells and while not destroying the cancer cells, it is thought to increase the likelihood of cancerous cell being destroyed by immunological mechanisms. Additionally met-enkephalin has been shown to inhibit angiogenesis, boost levels of natural killer cells and potentially have an immunostimulating/immunoregulating effect [28]. Alternatively, naltrexone is thought to mediate changes to the neuroendocrine system (34, 56, 58), increasing the number, density and sensitivity of opiate receptors in tissue, and increasing NK cell numbers [29-34].

High doses and frequent doses of naltrexone resulting in full receptor blockage have been shown to have both stimulatory and inhibitory effects on tumour development in rats and mice possibly related to the type of tumour. Due to the high frequency of spontaneous tumours in aging rats we may predict increases and decreases in the occurrence of different tumour types in rats treated with a sustained release naltrexone implant as compared with control animals.

## Methods

### Animals

54 Specific Pathogen Free (SPF) Wistar rats (27 males and 27 females) were purchased from an ISO9001:2000 certified laboratory animal producer at approximately 12 weeks of age. All rats were uncastrated, nulliparous and non-pregnant and were housed at the Animal Facility at Sir Charles Gairdner Hospital. The rats were randomized by sex into three treatment groups (A, B and C). Following a three week acclimatisation period to allow them to adjust to the new environment and to allow the researchers to assess the health of the animals, the rats in group A received a single OLANI tablet, rats in group B received a single poly-DL-lactide implant (placebo) and the rats in group C underwent a sham implant procedure (control). The rats were implanted under general anaesthetic (isoflurane). An 8 – 10 mm incision was made in to the subcutaneous tissue on the dorsal side, above the rat's hind leg approximately 15 mm from the spine. Blunt dissection was used to make a tunnel into the subcutaneous tissue. The implant was then positioned in the tunnel using the applicator. For the sham procedure an empty applicator was inserted into the tissue and removed. The incision was then sealed using 2 to 3 silk sutures. Following implantation the rats were closely monitored, with regular examination of the animal's overall health, body condition, local tissue reaction and implant characteristics.

Planned euthanasia was carried out following implantation at 3 weeks (6 from each treatment group), 6 months (5 from each treatment group), 12 months (4 naltrexone, 3 placebo) and following biodegradation of the implant (determined by palpation of the implant site) (5 naltrexone, 5 placebo and 7 control). Unplanned euthanasia and spontaneous death of 4 animals (2 naltrexone, 2 placebo) occurred during the study, primarily due to illness. Following euthanasia, the deceased animals were submitted for post mortem examination.

### Histology and pathology

In addition to general post mortem examination, major organs were weighed (liver, kidneys, adrenals, spleen, ovaries, uterus, testes, heart, lung, brain) and samples of 36 organs were collected for histology (including weighed organs and the salivary gland, trachea, thyroid, parathyroid, oesophagus, stomach, duodenum, pancreas,

small intestine, colon, urinary bladder, lymph node, aorta, mammary gland, eye, cerebrum, cerebellum, obex, thymus, peripheral nerve, implant site, cervical spinal cord, thoracic spinal cord, lumbar spinal cord, bone marrow and pituitary gland). Samples of the tumours that were removed during the study were also collected for histology.

Organs were fixed in 10% neutral buffered formalin. After fixation was complete the samples were trimmed by a pathologist and processed routinely to paraffin wax. The sections were cut at 5 µm and stained with haematoxylin and eosin. The tissues were examined by a veterinary pathologist by routine light microscopy.

Fibroadenomas detected during the study were removed by a veterinary surgeon under anaesthetic (isoflurane) prior to euthanasia. All removed fibroadenomas were examined by a veterinary pathologist and treated in the same way as other organs collect post mortem.

### Implants

Although the OLANI Implant maintains blood naltrexone levels for significantly longer than other sustained release naltrexone products, its blood naltrexone level of between 1 and 4ng/ml for the majority of this period is consistent with those achieved by single or sequential administration of other sustained naltrexone release products such as Vivitrol; Depotrex or Wedgewood [35-37].

The two implant preparations were manufactured by Go Medical Industries Ltd Pty in Perth, Western Australia. The active treatment (OLANI) was comprised of compressed naltrexone-polymer microspheres, while the placebo implant was comprised of only the polymer. In humans, each implant consists of 10 tablets, however only a single tablet (1/10<sup>th</sup> of an implant) was administered to each rat. Each active tablet contained a total of 117.3 mg of naltrexone. The dose given to the animals was calculated based on a surface area and was predicted to be approximately twice therapeutic dose.

### Results

Systematic pathological examination of the tissue and organs identified three different categories of tumours; adenomas, sarcomas and lymphomas. Adenomas and sarcomas were only found in the inactive treatment groups (placebo and control animals), while lymphomas were found only in the active naltrexone group (Table 1).

Tumours were more prevalent in the older animals, with none found in the 18 rats euthanized at 3 weeks post implantation. The earliest tumour was seen at the 6 month euthanasia time point (168 days post treatment).

#### Lymphoma

Four lymphomas were noted in rats, all of which were in the naltrexone treatment group. In two animals the lymphoma was located in the colon (at day 168 and 477) (Table 1). In the third animal lymphomas were found in the liver and the spleen (at day 350). All of the lymphomas were found at post mortem.

#### Adenomas

Adenomas were seen in six rats, in the pituitary (1), mammary tissue (4) and the pancreas (1) (Table 2). The adenomas were found in both the placebo and control group but not in the active naltrexone group. The first adenoma (a fibro-adenoma) was noted at 168 days following implantation; however the average occurrence was 364 ± 133.3 days. Rat number 2, which was found to have a pituitary tumour, was euthanized due to symptoms associated with the tumour

		Control		Placebo		Naltrexone	
		Rats	Tumours	Rats	Tumours	Rats	Tumours
Adenoma	Pituitary adenoma	0	0	1	1	0	0
	Fibroadenoma	2	6	2	2	0	0
	Islet adenoma	1	1	0	0	0	0
	Total	3	6	2	3	0	0
Sarcoma	Fibrosarcoma	1	1	2	3	0	0
	Metastatic sarcoma	0	0	1*	1	0	0
	Total	1	1	2	4	0	0
Lymphoma	Colon	0	0	0	0	2	2
	Liver	0	0	0	0	1	1
	Spleen	0	0	0	0	1	1
	Total	0	0	0	0	3	4
Total		4	7	4	7	3	4

\*Associated with a fibrosarcoma.

**Table 1:** Of the 54 rats in this study, 9 (16.7%) developed at least one type of tumour. While approximately equal numbers of tumours developed in the three treatment groups, the type of tumours in each group varied. Adenomas and sarcomas occurred only in the placebo and control group, while lymphomas were only present in the naltrexone group.

ID	Sex	Treatment	Type	No.	Days from implant	Description
2	F	Placebo*	Pituitary adenoma	1	287	Euthanized due to weight loss, lethargy, hunched posture, lack of coordination. Tumour 10 x 8 x 8 mm dark red soft tumour within the cranial cavity compressing overlying brain.
14	F	Placebo	Fibro-adenoma	1	168	Found at post mortem. Well-demarcated, soft, pale fatty mass, subcutaneously caudal to the left thigh muscle.
18a.	F	Placebo	Fibro-adenoma	1	287	Surgically removed. Positioned under left front leg.
18b.	F	Placebo	Fibro-adenoma	3	462	3 tumours surgically removed.
23	F	Control	Fibro-adenoma	1	511	Surgically removed from left side of chest.
42a.	M	Control	Fibro-adenoma	1	315	Surgically removed from right side of back, above its hind leg.
42b.	M	Control	Islet adenoma	1	515	Found at post mortem. Seen in the pancreas.
18	F	Placebo	Fibro-sarcoma	1	562	Found at post mortem. A 25mm sarcoma in subcutis (seen histologically)
22a.	F	Placebo	Fibro-sarcoma	2	562	Found at post mortem. Two 5 – 9 mm sarcomas in the subcutis (seen histologically)
22b.	F	Placebo	Metastatic sarcoma	1	562	Found at post mortem. Seen in the lymph node, in association with subcutaneous sarcoma.
42	M	Control	Fibro-sarcoma	1	515	Found at post mortem. 4mm x 6mm deep within the subcutis (seen histologically)
9	F	Naltrexone	Colon	1	477	Lymphoma
27	F	Naltrexone	Colon	1	168	Mural lymphosarcoma
51a.	M	Naltrexone	Liver	1	350	Lymphosarcoma with portal infiltrates of lymphocytes. Centrilobular hydropic degeneration and necrosis.
51b.	M	Naltrexone	Spleen	1	350	Lymphosarcoma with loss of lymphoid nodules and expansions of the Periarteriolar Lymphoid Sheath (PALS).

\* The implant was ejected at day 78 post implant and re-implanted with a placebo implant at day 170.

**Table 2:** The three types of tumours, adenoma, sarcoma and lymphomas observed in rats represent three basic types of tissue in the body; epithelial, mesenchymal and round cell tissue.

(lethargy, lack of coordination, weight loss). The Islet adenoma was also observed at post mortem, however euthanasia occurred as part of the study protocol as no clinical symptoms of the adenoma had been observed. All but one fibro-adenoma was found prior to post mortem. All adenomas were removed by the study veterinarian during the study for the welfare of the animals.

## Sarcomas

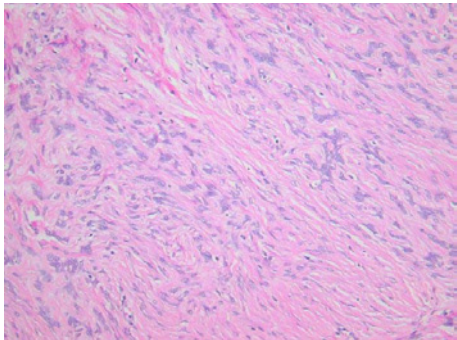
During the study 3 rats developed a total of 4 soft tissue sarcomas (presumptive fibrosarcomas), located in the subcutis of the flank, at the site of the implant (Table 2) (Figure 1). In one animal the sarcoma had metastasized to the lymph node (Figure 2). Tumours were only observed in placebo and control animals, with none observed in the active naltrexone treatment group. The sarcomas were only present in animals at the very end of the study (515 to 562 days post implant).

## Hyperplasia

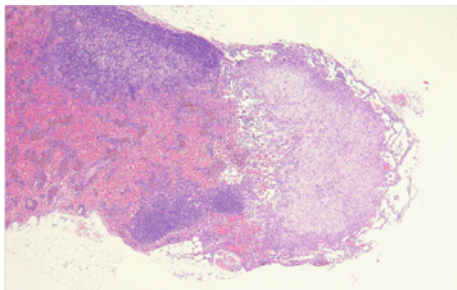
While hyperplasia is generally considered a reactive or non-neoplastic process, the presence of hyperplasia was included in this study because of the potential for hyperplasia to become a malignant process. Hyperplasia was observed in nine animals in the adrenal (in the medulla of 3 rats and in the cortex), pituitary (in the pars distalis of 5 rats) and thyroid (1 rat) (Table 3). Hyperplasia was predominately noted in animals euthanized towards the end of the study, with the first observed at 363 days, with a mean of 479 and a standard deviation of 70 days. Hyperplasia was present in rats from each treatment groups (1 rat in the naltrexone group, 2 in the placebo and 6 in the control).

In the past there has been some question as to the histological distinction between hyperplasia and neoplasia. In this study, neoplasia was distinguished from hyperplasia by the presence of a pseudocapsule





**Figure 1:** Light microscopy of fibrosarcoma from rat 42. There are randomly oriented plump fibroblasts amongst a disorganised collagenous stroma.



**Figure 2:** Lymph node from rat 22, to show an infiltrate of poorly organised mesenchymal cells at the right edge (metastatic sarcoma).

separating the tumour from the adjacent tissue or compression of the adjacent tissue as defined by Percy and Barthold [38].

**Discussion**

Data from several studies have suggested that exposure of both rats and mice to naltrexone sufficient to achieve total opiate receptor blockade have been shown to have both stimulatory and inhibitory effects on the appearance and development of both spontaneous and chemically induced tumours. Current study data is the first to report outcomes associated with a sustained release naltrexone product and suggests that naltrexone’s effect maybe dependent on tumour type, with an increase in lymphomas but a reduction in adenomas and sarcomas.

Recent research into the treatment of lymphomas has produced evidence to suggest that dopamine may play an important role in the expression and regulation of lymphomas. In vitro, low levels of dopamine has shown to rapidly arrest the proliferation of normal and

malignant B cells [39] and resulted in the rapid and extensive cell death in a culture of Burkett lymphoma cells [40]. Linkages between the opiate and dopamine system have been demonstrated in rats [41,42] and provide the evidence to support the use of naltrexone in the treatment of amphetamine and alcohol dependence and compulsive behaviours. Research suggests that by blocking the opiate receptors, naltrexone attenuates increases in dopamine. It may be expected that by blocking the opiate receptors for extensive periods, for example with a sustained release naltrexone implant, that there would be less circulating dopamine and thus the prevalence of lymphomas may be increased as observed in our naltrexone rats. In the naltrexone group 3 of the 18 rats (16.6%) were observed to have lymphomas with none in placebo or control group and historical controls measuring rates of spontaneous tumours at 2.3% in females and 1.3% in males (sample of 930 animals) [43].

Similarly it could be expected the by administering small doses of naltrexone, that block a small number of receptors for a short period of time, resulting in up-regulation or increased sensitivity of the receptors that dopamine may in turn be increased in the system. Alternatively the use of small doses of naltrexone may up regulate the production of met enkephalin or increased sensitivity of the opiate growth factor receptor, reducing tumour proliferation and angiogenesis. Such changes may be shown to reduce the incidence or growth of lymphomas as observed in a case study by Berkson et al. [44], in which a patient with stage III follicular lymphoma was successfully treated with low dose naltrexone (3mg, once daily). The authors reported that after 6 months of treatment, the patient’s enlarged cervical and lymph nodes, originally measuring 7.6 cm and 12.7 cm respectively, were no longer palpable had almost completely resolved. Similarly, CT/PET scans also showed significant improvements in the abnormal foci of activity seen in the neck, axillae, and groin.

Adenomas are especially common in rats, especially with age, with fibroadenomas (particularly involving mammary tissue) occurring in approximately 36% of female and 3% of male Wistar rats, while pituitary adenomas occur in approximately 50% of female and 34% of male Wistar rats [43]. There are a number of possible mechanisms which may explain reduced adenomas in naltrexone exposed rats. Such changes may be the result of naltrexone mediated change in reproductive hormones such as prolactin, oestrogen and progesterone. For example, naltrexone attenuates increases in dopamine [45], which is a known prolactin releasing factor [46]. Increases in prolactin have been linked to the promotion of murine mammary tumorigenesis [47] and increases in the risk of developing breast cancer in post-menopausal women [48]. Naltrexone could have resulted in decreases in beta-endorphins, which may also result in a decrease in prolactin secretion from the pituitary [49]. Alternatively, naltrexone may indirectly

Rat No.	Sex	Treatment	Location	Days from implant	Description
3	F	Control	Adrenal	363	Medulla hyperplasia of the adrenal
9a	F	Naltrexone	Pituitary	477	Nodular hyperplasia in the pars distalis
9b	F	Naltrexone	Adrenal	477	Medulla hyperplasia of the adrenal
10	F	Control	Adrenal	363	Focal nodular hyperplasia in the cortex of the adrenal
18	F	Placebo	Thyroid	563	Unilateral nodular hyperplasia in the thyroid
23	F	Control	Pituitary	563	Nodular hyperplasia in the pars distalis
31	M	Control	Pituitary	479	Nodular hyperplasia in the pars distalis
42	M	Control	Pituitary	517	Nodular hyperplasia in the pars distalis
44	M	Placebo	Pituitary	517	Nodular hyperplasia in the pars distalis
49	M	Control	Adrenal	477	Medulla hyperplasia of the adrenal

**Table 3:** Hyperplasia was noted in the adrenal, pituitary and thyroid in animals in each of the groups in this study.

decrease oestrogen or progesterone levels. Research has shown that the growth of transplanted mammary fibroadenomas is retarded by ovariectomy in rats, with the effect strengthened when combined with an adrenalectomy [50]. Similarly in ovariectomised rats, the growth of tumours could be stimulated using phenolic oestrogens, and even more so when combined with progesterone [50]. Abou-Issa and Tejwani found that DMBA induced tumours that responded to naltrexone had both estrogen and progesterone receptors while unresponsive tumours were negative for both receptor types [49].

Fibrosarcomas however are generally uncommon, with one study recording an incidence of only 3.2% of males and less than 0.5% in females [43]. Both tumour types were only observed in the placebo and control group. The fibrosarcomas in this study were predominately at the site of implantation in both the placebo (2 females) and the control rats (one male). Fibrosarcomas have also been associated with microchip identification devices in rats [51] and injections/vaccines and microchips in both cats and dogs [52,53]. The relative increase in the presence of fibrosarcomas in this study (5.6%), as compared with historical controls (up to 3.2%), may be due to the minor damage and associated inflammatory and reparative responses that occurred during the implant procedure. With such low numbers, it is difficult to conclusively determine if the presence of fibrosarcomas is treatment related.

Hyperplasia was noted in endocrine glands (adrenal, pituitary and thyroid) of 9 animals in the study. Although hyperplasia was noted in animals from each of the three treatment groups, the incidence of hyperplasia in the naltrexone group was relatively low (1 rat of 9). The absence of hormone related tumours and a lowered occurrence of hyperplasia may indicate that the stimulus required to induce hyperplasia may be reduced in naltrexone treated animals or that when the stimulus is present and hyperplasia does arise, the stimulus dose not persist long enough to produce a neoplasm. However studies with an increase number of animals may be required to determine more definitely if the incidence of hyperplasia is reduced by subcutaneously administered naltrexone.

Doses of naltrexone resulting in full opiate receptor blockade (i.e. 4 x 0.1 mg/kg/day or 10 mg/kg/day SC) have been shown to have both stimulatory and inhibitory effects on the appearance and development of both spontaneous and chemically induced tumours in both rats and mice [18,21,23,54]. Results from this study suggest that effects of exposure to sustained release naltrexone are largely dependent on the type of tumour involved. However these results many several limitations, especially in terms of sample size and should solely provide data to support further research into this area rather than make conclusions about the effect of naltrexone in the development or absence of tumours. The results are consistent with data from other studies, with naltrexone exposure through injection or ingestion. Both adenomas and sarcomas were only located in the non-naltrexone groups (the placebo and the control), while lymphomas were only detected in rats in the naltrexone group. Hyperplasia was also noted in animals in all three treatment groups, occurring in the adrenal, pituitary and thyroid.

This study raises the obvious question as to the likely carcinogenic impact of depot and long acting naltrexone formulations in human patients, given the inter-species differences in biology and incidence alluded to above. In the context of the present study it is important to note that whilst depot medication for six months represents about 25% of the experimental subject's life, this period represents only 0.63%

of the typical Australian human's lifespan of 79 years. Treatment of human patients for this extent of their life span has not been reported. In terms of exposure, rats euthanized at 3 weeks post treatment may be a better representation of the amount of exposure observed in humans, with 3 weeks equating to approximately 3% of a rat's life. No tumours were observed in these rats. At this age, (4 to 5 months old) the development of spontaneous tumours is generally uncommon. However it is also worth noting, that in most cases presence or absence of the tumours occurred after naltrexone was no longer being released from the implant.

Moreover the peak cancer incidence in man is in the over-55-year age group, an age bracket which contains only about 2% of most Australian series of opiate-dependent patients [55]. It is further noted that no cases of cancer have been reported in either clinical trials of naltrexone implants [56,57] nor in large comparative case review series [58]. Contrariwise one notes that greatly elevated rates of malignancies affecting the bladder, oesophagus, larynx and oropharynx have been noted in patients who are exposed to long term opiate agonist treatment [59-62]. Furthermore important considerations of clinical co-carcinogenicity by way of interactions with other toxins such as tobacco have been raised in oncological [63] and other [64] contexts. Clearly further studies are required to examine this issue for both opiate agonist- and opiate antagonist-treated patients in western clinical populations. It is conceivable that just as the elevated rate of malignancy in organ transplant patients remained obscure until specifically studied, and a 100-fold elevation of the rate of bladder cancer in opiate addicts in Iran was not noted until interrogated epidemiologically [65], similar hidden major elevations of the prevalence of malignancies may be operating unobserved. Such a finding if replicated would have major implications for both the type of treatment recommended (viz. agonist vs. antagonist) and the duration for which it is proposed.

## Conclusions

Long term continuous exposure to naltrexone appears to have both stimulatory and inhibitory effects on the development of tumours, primarily dependent on the tumour type. All though this study was relatively small and may require repeating in a large sample size, the results were congruent with previously published studies using repeat dose studies using oral and injectable naltrexone. Future study would be directed at examining the mechanism behind naltrexone's effect on tumours, in the hope it may aid tumour treatment.

## Acknowledgements

The authors would like to acknowledge the assistance of the Animal Care Unit at M Block Animal Facility at Sir Charles Gardiner Hospital for their assistance with care of the animals in this study and Dr Yandi Liu for his assistance with the surgical procedure. Michael Slaven and Gerard Spoelstra are thanked for the CD79a and CD3 immunohistochemistry used in tumour immunophenotyping

## References

1. Jayaram-Lindström N, Wennberg P, Beck O, Franck J (2005) An open clinical trial of naltrexone for amphetamine dependence: compliance and tolerability. *Nord J Psychiatry* 59: 167-171.
2. Dean RL (2005) The preclinical development of Medisorb Naltrexone, a once a month long acting injection, for the treatment of alcohol dependence. *Front Biosci* 10: 643-655.
3. O'Malley SS, Garbutt JC, Gastfriend DR, Dong Q, Kranzler HR (2007) Efficacy of extended-release naltrexone in alcohol-dependent patients who are abstinent before treatment. *J Clin Psychopharmacol* 27: 507-512.
4. Smith JP, Stock H, Bingham S, Mauger D, Rogosnitzky M, et al. (2007) Low-dose naltrexone therapy improves active Crohn's disease. *Am J Gastroenterol* 102: 820-828.

5. Agrawal YP (2005) Low dose naltrexone therapy in multiple sclerosis. *Med Hypotheses* 64: 721-724.
6. Gironi M, Martinelli-Boneschi F, Sacerdote P, Solaro C, Zaffaroni M, et al. (2008) A pilot trial of low-dose naltrexone in primary progressive multiple sclerosis. *Mult Scler* 14: 1076-1083.
7. Grant JE (2005) Outcome study of kleptomania patients treated with naltrexone: a chart review. *Clin Neuropharmacol* 28: 11-14.
8. White T, Schultz SK (2000) Naltrexone treatment for a 3-year-old boy with self-injurious behavior. *Am J Psychiatry* 157: 1574-1582.
9. Griengl H, Sendera A, Dantendorfer K (2001) Naltrexone as a treatment of self-injurious behavior--a case report. *Acta Psychiatr Scand* 103: 234-236.
10. Eyvazzadeh AD, Pennington KP, Pop-Busui R, Sowers M, Zubieta JK, et al. (2009) The role of the endogenous opioid system in polycystic ovary syndrome. *Fertil Steril* 92: 1-12.
11. Ahmed MI, Duleba AJ, El Shahat O, Ibrahim ME, Salem A (2008) Naltrexone treatment in clomiphene resistant women with polycystic ovary syndrome. *Hum Reprod* 23: 2564-2569.
12. Fruzzetti F, Bersi C, Parrini D, Ricci C, Genazzani AR (2002) Effect of long-term naltrexone treatment on endocrine profile, clinical features, and insulin sensitivity in obese women with polycystic ovary syndrome. *Fertil Steril* 77: 936-944.
13. Guido M, Romualdi D, Lanzone A (2006) Role of opioid antagonists in the treatment of women with glucoregulation abnormalities. *Curr Pharm Des* 12: 1001-1012.
14. Fulghesu AM, Lanzone A, Fortini A, Guido M, Caruso A, et al. (1993) Evaluation of ovarian and adrenal sources of androgens in women with polycystic ovary syndrome. Dexamethasone and GnRH-agonist administration. *J Reprod Med* 38: 387-392.
15. Armeanu MC, Lambalk CB, Berkhout GM, Schoemaker J (1992) Effects of opioid antagonism with naltrexone on pulsatile luteinizing hormone secretion in women with hypothalamic amenorrhea in basal conditions and after discontinuation of treatment with pulsatile LHRH. *Gynecol Endocrinol* 6: 3-12.
16. Armeanu MC, Berkhout GM, Schoemaker J (1992) Pulsatile luteinizing hormone secretion in hypothalamic amenorrhea, anorexia nervosa, and polycystic ovarian disease during naltrexone treatment. *Fertil Steril* 57: 762-770.
17. Hytrek SD, McLaughlin PJ, Lang CM, Zagon IS (1996) Inhibition of human colon cancer by intermittent opioid receptor blockade with naltrexone. *Cancer Lett* 101: 159-164.
18. Koo KL, Tejwani GA, Abou-Issa H (1996) Relative efficacy of the opioid antagonist, naltrexone, on the initiation and promotion phases of rat mammary carcinogenesis. *Anticancer Res* 16: 1893-1898.
19. Zagon IS, McLaughlin PJ (1983) Opioid antagonists inhibit the growth of metastatic murine neuroblastoma. *Cancer Lett* 21: 89-94.
20. Tejwani GA, Gudehitlu KP, Hanissian SH, Gienapp IE, Whitacre CC, et al. (1991) Facilitation of dimethylbenz[a]anthracene-induced rat mammary tumorigenesis by restraint stress: role of beta-endorphin, prolactin and naltrexone. *Carcinogenesis* 12: 637-641.
21. Zagon IS, McLaughlin PJ (1984) Duration of opiate receptor blockade determines tumorigenic response in mice with neuroblastoma: a role for endogenous opioid systems in cancer. *Life Sci* 35: 409-416.
22. Gupta K, Kshirsagar S, Chang L, Schwartz R, Law PY, et al. (2002) Morphine stimulates angiogenesis by activating proangiogenic and survival-promoting signaling and promotes breast tumor growth. *Cancer Res* 62: 4491-4498.
23. Zagon IS, McLaughlin PJ (1983) Naltrexone modulates tumor response in mice with neuroblastoma. *Science* 221: 671-673.
24. Tennant FS Jr, Rawson RA, Cohen AJ, Mann A (1984) Clinical experience with naltrexone in suburban opioid addicts. *J Clin Psychiatry* 45: 42-45.
25. Chiang CN, Hollister LE, Gillespie HK, Foltz RL (1985) Clinical evaluation of a naltrexone sustained-release preparation. *Drug Alcohol Depend* 16: 1-8.
26. Comer SD, Sullivan MA, Hulse GK (2007) Sustained-release naltrexone: novel treatment for opioid dependence. *Expert Opin Investig Drugs* 16: 1285-1294.
27. Hulse GK, Arnold-Reed DE, O'Neil G, Chan CT, Hansson R, et al. (2004) Blood naltrexone and 6-beta-naltrexol levels following naltrexone implant: comparing two naltrexone implants. *Addict Biol* 9: 57-63.
28. Zagon IS, Verderame MF, McLaughlin PJ (2002) The biology of the opioid growth factor receptor (OGFr). *Brain Res Brain Res Rev* 38: 351-376.
29. Zagon IS, Verderame MF, McLaughlin PJ (2002) The biology of the opioid growth factor receptor (OGFr). *Brain Res Brain Res Rev* 38: 351-376.
30. Morris BJ, Millan MJ, Herz A (1988) Antagonist-induced opioid receptor up-regulation. II. Regionally specific modulation of mu, delta and kappa binding sites in rat brain revealed by quantitative autoradiography. *J Pharmacol Exp Ther* 247: 729-736.
31. Yoburn BC, Sierra V, Lutfy K (1989) Chronic opioid antagonist treatment: assessment of receptor upregulation. *Eur J Pharmacol* 170: 193-200.
32. Yoburn BC, Paul D, Azimuddin S, Lutfy K, Sierra V (1989) Chronic opioid antagonist treatment increases mu and delta receptor mediated spinal opioid analgesia. *Brain Res* 485: 176-178.
33. Tempel A, Zukin RS, Gardner EL (1982) Supersensitivity of brain opiate receptor subtypes after chronic naltrexone treatment. *Life Sci* 31: 1401-1404.
34. Zukin RS, Sugarman JR, Fitz-Syage ML, Gardner EL, Zukin SR, et al. (1982) Naltrexone-induced opiate receptor supersensitivity. *Brain Res* 245: 285-292.
35. Hulse, G.K., et al., Naltrexone implants in the treatment of heroin addiction, in *Trends in Substance Abuse Research*, C.R. McKenna, Editor. 2007, Nova Science Publishers Inc: New York. 71-88.
36. Dunbar JL, Turncliff RZ, Dong Q, Silverman BL, Ehrich EW, et al. (2006) Single- and multiple-dose pharmacokinetics of long-acting injectable naltrexone. *Alcohol Clin Exp Res* 30: 480-490.
37. Johnson BA (2007) Naltrexone long-acting formulation in the treatment of alcohol dependence. *Ther Clin Risk Manag* 3: 741-749.
38. Percy DH, Barthold SW (2007) *Pathology of the laboratory rodents and rabbits*. (3rd edn), Blackwell Publishing.
39. Meredith EJ, Holder MJ, Rosén A, Lee AD, Dyer MJ, et al. (2006) Dopamine targets cycling B cells independent of receptors/transporter for oxidative attack: Implications for non-Hodgkin's lymphoma. *Proc Natl Acad Sci U S A* 103: 13485-13490.
40. Braesch-Andersen S, Paulie S, Stamenkovic I (1992) Dopamine-induced lymphoma cell death by inhibition of hormone release. *Scand J Immunol* 36: 547-553.
41. Di Chiara G, Imperato A (1988) Drugs abused by humans preferentially increase synaptic dopamine concentrations in the mesolimbic system of freely moving rats. *Proc Natl Acad Sci U S A* 85: 5274-5278.
42. Spanagel R, Herz A, Shippenberg TS (1990) Identification of the opioid receptor types mediating beta-endorphin-induced alterations in dopamine release in the nucleus accumbens. *Eur J Pharmacol* 190: 177-184.
43. Poteracki J, Walsh KM (1998) Spontaneous neoplasms in control Wistar rats: a comparison of reviews. *Toxicol Sci* 45: 1-8.
44. Berkson BM, Rubin DM, Berkson AJ (2007) Reversal of signs and symptoms of a B-cell lymphoma in a patient using only low-dose naltrexone. *Integr Cancer Ther* 6: 293-296.
45. Jayaram-Lindstrom N (2007) Evaluation of naltrexone as a treatment for amphetamine dependence, in *Department of Clinical Neurosciences*. Karolinska Institutet: Stockholm.
46. McCann SM, Lumpkin MD, Mizunuma H, Khorram O, Ottlecze A, et al. (1984) Peptidergic and dopaminergic control of prolactin release. *Trends in Neuroscience* 7: 127-131.
47. Welsch CW, Nagasawa H (1977) Prolactin and murine mammary tumorigenesis: a review. *Cancer Res* 37: 951-963.
48. Hankinson SE, Willett WC, Michaud DS, Manson JE, Colditz GA, et al. (1999) Plasma prolactin levels and subsequent risk of breast cancer in postmenopausal women. *J Natl Cancer Inst* 91: 629-634.
49. Abou-Issa H, Tejwani GA (1991) Antitumour activity of naltrexone and

- correlations with steroid hormone receptors. *Biochem Biophys Res Commun* 175: 625-630.
50. Huggins C, Mainzer K, Torralba Y (1956) Hormonal influences on mammary tumors of the rat: Acceleration of growth of transplanted fibroadenoma in ovariectomized and hypophysectomized rats. *J Exp Med* 104: 525-538.
  51. Elcock LE, Stuart BP, Wahle BS, Hoss HE, Crabb K, et al. (2001) Tumours in long-term rat studies associated with microchip animal identification devices. *Exp Toxicol Pathol* 52: 483-491.
  52. Vascellari M, Melchioni E, Bozza MA, Mutinelli F (2003) Fibrosarcomas at presumed sites of injection in dogs: Characteristics and comparison with non-vaccination site fibrosarcomas and feline post-vaccinal fibrosarcoma. *J Vet Med A Physiol Pathol Clin Med* 50: 286-291.
  53. Vascellari M, Melchioni E, Mutinelli F (2006) Fibrosarcoma with typical histological features of post-injection sarcoma at site of microchip implant in a dog: Histologic and immunohistochemical study. *Vet Pathol* 43: 545-548.
  54. Anon, Revia, in MIMS Annual, E. Donohoo, et al., Editors. 2006, CMP United Business Media: St Leonards, NSW. p. 1760-1762.
  55. Tait RJ, Ngo HT, Hulse GK (2008) Mortality in heroin users 3 years after naltrexone implant or methadone maintenance treatment. *J Subst Abuse Treat* 35: 116-124.
  56. Comer SD, Sullivan MA, Yu E, Rothenberg JL, Kleber HD, et al. (2006) Injectable, sustained-release naltrexone for the treatment of opioid dependence: a randomized, placebo-controlled trial. *Arch Gen Psychiatry* 63: 210-218.
  57. Kunøe N, Lobmaier P, Vederhus JK, Hjerkin B, Hegstad S, et al. (2009) Naltrexone implants after in-patient treatment for opioid dependence: randomised controlled trial. *Br J Psychiatry* 194: 541-546.
  58. Reece AS (2009) Comparative treatment and mortality correlates and adverse event profile of implant naltrexone and sublingual buprenorphine. *J Subst Abuse Treat* 37: 256-265.
  59. Mousavi MR, Damghani MA, Haghdoust AA, Khamesipour A (2003) Opium and risk of laryngeal cancer. *Laryngoscope* 113: 1939-1943.
  60. Fahmy MS, Sadeghi A, Behmard S (1983) Epidemiologic study of oral cancer in Fars Province, Iran. *Community Dent Oral Epidemiol* 11: 50-58.
  61. Sadeghi A, Behmard S (1978) Cancer of the bladder in Southern Iran. *Cancer* 42: 353-356.
  62. Sadeghi A, Behmard S, Shafiepoor H, Zeighmani E (1977) Cancer of the esophagus in southern Iran. *Cancer* 40: 841-845.
  63. Li JH, Lin LF (1998) Genetic toxicology of abused drugs: a brief review. *Mutagenesis* 13: 557-565.
  64. Reece S (2009) Dental health in addiction. *Aust Dent J* 54: 185-186.
  65. Behmard S, Sadeghi A, Mohareri MR, Kadivar R (1981) Positive association of opium addiction and cancer of the bladder. Results of urine cytology in 3,500 opium addicts. *Acta Cytol* 25: 142-146.