

Case Report

Open Access

The Edentulous Maxillary Arch: A Novel Approach to Prosthetic Rehabilitation with Dental Implants, Based Upon the Combination of Optimum Mechanical Resources

Cabello G^{1*}, González D², and G. Fábrega J³

¹Private Practice, Málaga and Visiting Professor Master's degree in Periodontics and Esthetic Dentistry, Complutense University of Madrid; Spain.

²Private Practice, Murcia and Visiting Professor, Master's degree in Periodontics, University of Barcelona, Spain

³Private Practice, Madrid and Visiting Professor, Master's degree in Esthetic Dentistry, Complutense University of Madrid, Spain

Abstract

This article presents a novel prosthodontic approach to restore the maxillary edentulous arch. The treatment proposal consists on a full-arch implant-supported restoration with a segmented design, where the different fixed partial dentures will biomechanically behave as a splinted prosthesis, when connected by means of spark erosion technology. This design benefits from the advantages of both, screw-retained and cemented restorations that will be reviewed in the text.

Keywords: Edentulous maxilla; Fixed implant-supported prostheses; Fully edentulous patient; Dental implants; Biomechanics; Spark erosion

Introduction

Rehabilitation of the edentulous maxilla with dental implants usually presents more challenges when compared to the mandibular edentulous arch. The main difficulty often resides in the choice of the type prostheses [1,2]. When the intermaxillary discrepancies are large (Angle Class III and/or certain cases of atrophic maxillae) or additional lip support is required, an implant-supported fixed prosthesis may be contraindicated. In these types of patients, choosing an implant-supported overdenture may be the best option to reach the treatment goals that include function, esthetics and ease of maintenance [2-5].

However, in many cases patient expectations lean towards a fixed prosthesis. Implant-supported fixed prostheses have been associated with phonetic [3,4] and aesthetic problems. However, both limitations could be addressed through an adequate prosthodontic approach. In situations of atrophic maxillae, provided there is not an excessive horizontal deficiency, esthetic pink ceramic with a gingival-like appearance, can be utilized by the dental technician, to solve this vertical deficiency. Innovative designs have been suggested for its implementation [5,6].

Metal-resin fixed hybrid prostheses have also been reported to often present aesthetic, maintenance and phonetic problems [1,4], as they frequently have to compensate for severe tissue vertical and/or horizontal deficiencies. In addition, non-axially applied forces upon function may cause fracture of the resin teeth in these types of restorations in the upper hybrid prostheses [1,3].

Another issue related to the rehabilitation of the edentulous maxilla is the achievement of a passive fit of the superstructure on the implants or implant abutments. Different strategies [7], including spark-erosion [8] or a segmented design of the restoration have been proposed to overcome this problem, particularly relevant when multiple implants with a curvilinear distribution are present [9,10].

Finally, as an additional argument to the clinical approach suggested below, it is important to consider the advantages and limitations of the screw-retained versus cemented prosthetic restorations, thoroughly described in the available literature [11-23].

Based on the combination of all of these arguments, the following clinical approach is recommended for rehabilitating patients with an edentulous upper maxilla.

Clinical Case 1

A 63-year old patient who has type II diabetes (controlled by using hypoglycemics) and smokes 20 cigarettes per day, visits the clinic requesting oral rehabilitation. The patient has an edentulous upper maxilla, which had been rehabilitated in another clinic by means of an overdenture retained by an implant at the level of 27, but the result was not satisfactory for the patient. The patient's first and second molars were found to be absent in the inferior maxilla. The intermaxillary relationship was not favorable, as it presented a mild skeletal class III relationship. On the other hand, the patient suffered a generalized moderate chronic and advanced localized periodontal disease and periimplantitis, which had caused extensive bone loss in the aforementioned implant (Figures 1 and 2). The following course of treatment was carried out:

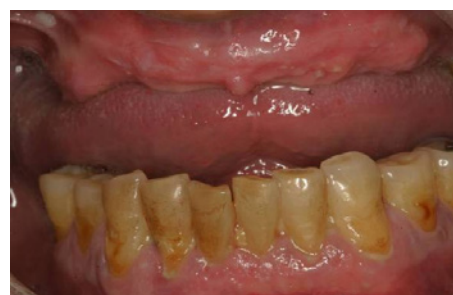

Figure 1: Initial clinical situation. The patient presented with moderate generalized and localized advanced chronic periodontitis. In a previous treatment, he had received an implant at the level of sextant III, which presented severe periimplantitis. A course of periodontal treatment was completed prior to the implant treatment.

***Corresponding author:** Gustavo Cabello Domínguez, Clínica NEXUS, Calle Méndez Núñez, nº 12; 1ª Planta, 29008 Málaga, Spain, Tel: +34 625 693 980; E-mail: info@clinicanexus.com

Received January 17, 2014; **Accepted** February 25, 2014; **Published** February 27, 2014

Citation: Cabello G, González D, G. Fábrega J (2014) The Edentulous Maxillary Arch: A Novel Approach to Prosthetic Rehabilitation with Dental Implants, Based Upon the Combination of Optimum Mechanical Resources. Dentistry 4: 217. doi:[10.4172/2161-1122.1000217](https://doi.org/10.4172/2161-1122.1000217)

Copyright: © 2014 Cabello G, et al. This is an open-access article distributed under the terms of the Creative Commons Attribution License, which permits unrestricted use, distribution, and reproduction in any medium, provided the original author and source are credited.

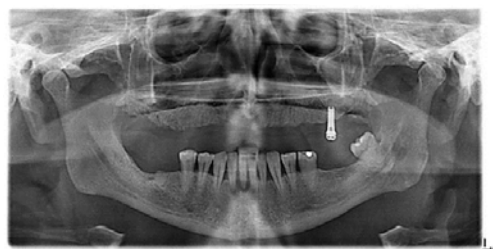

Figure 2: Radiological situation.

Periodontal treatment

Consisting of oral hygiene instructions, scaling and root planing by quadrants and information about the effects of tobacco on the periodontium and dental implants, as well as motivating the patient to reduce or get rid of the habit. Once the objectives of the initial periodontal treatment were fulfilled, we then planned out the prosthetic phase.

Planning the prosthetic treatment

A diagnostic wax-up and an upper and lower surgical guide were created. In order to create the upper surgical guide, a new wax-up was made, which was duplicated using a guide without a buccal flank, which allowed evaluating the patient's degree of lip support and considering issues related to aesthetics and phonetics. In addition, having analyzed the models in the articulator, we determined it necessary to put crowns in the four lower premolars, in an effort to avoid occlusal problems derived from a flat occlusal anatomy and the presence of inverted cusps, while we also tried to correct the posterior crossbite. Based on the aforementioned reasons and on the Denta-Scan assessment, we proceeded with the surgical phase.

Surgical phase of placing implants

The following Straumann® implants (Figure 3) were placed at the SLA active® surface using local anesthesia and intravenous sedation: Wide neck® at the level of number 16, 26, 36 and 46, Standard plus® at the level of 14, 13, 23 and 24 and 3.3 Bone level® at the level of 41 (post-extraction). During the same surgical procedure, and prior to inserting the implants, tooth number 41 was extracted (loss of insertion up to the apex and type III mobility) as well as the implant located at the level of 17 (active periimplantitis with significant horizontal bone loss).

Prosthetic rehabilitation

Provisional phase of prosthesis: Immediate upper provisional implant-supported prosthesis on provisional abutments for screw-retained prostheses. Implant 41i was initially restored (relieving it from occlusal load) using a provisional abutment to be cemented. Both prostheses were inserted 3 days after placement of the implants, once the most critical phase of the surgical post-operative period was over. The patient was recommended to follow a soft diet, avoiding excessive pressure of chewing during the osseointegration phase of the implants (4 weeks).

Permanent oral rehabilitation: (Figures 4-7)

Mandibular arch

- Implant-supported metal-ceramic single crowns on 36i and 46i. Various 5.5 mm solid abutments® were used for cement-retained crowns. On free lower ends rehabilitated with a single implant, this abutment guarantees maximum stability in the abutment-implant joint [24]. These crowns were cemented with

Premier Implant cement® (Premier dental).

- A single implant-supported metal-ceramic crown was placed on tooth 41i. On the 3.3 Bone level® implant, a screw-retained crown was placed on a gold abutment for overcasting.
- Metal-ceramic tooth-supported single crowns were placed on 34-35 and 44-45, using Rely-X® (3M ESPE) as cement.

Maxillary arch

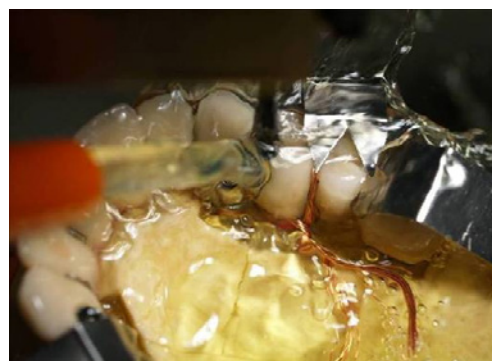
- Metal-ceramic implant-supported fixed prostheses were placed on synOcta® abutments for cementing in posterior sections

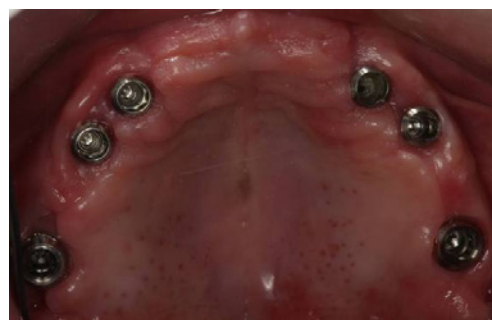
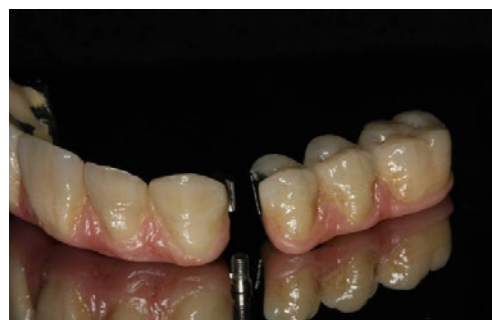
Figure 3: Detail of the distribution of the six Straumann® implants. The implants were placed at the level of 16, 14, 23, 24 and 26. Avoiding implants at the level of the upper incisors would prevent problems associated with hygiene, as this case involved a patient with a moderate Angle Class III.



Figures 4: Detail of two of the sections of the rehabilitation (the posterior section that will be cemented on SynOcta® abutments to be cement-retained; and the anterior section that will be screwed into SynOcta® abutments to be screw-retained).



Figures 5: Process of elaborating the Spark-erosion attachment in the electrolytic bath (which will connect the anterior section with the two posterior sections).

(14i-15-16i and 24i-25-26i). Both were cemented with Premier Implant cement® (Premier Dental).

- A metal-ceramic implant-supported fixed prosthesis was placed on synOcta® abutments for screwing into the anterior section (13i-12-11-21-22-23i).
- Posterior and anterior sections were connected using attachments made by Spark-erosion (Figures 4 and 5).

Clinical Case 2

A 59-year patient who has hypertension (controlled using diuretics) and is an ex-smoker. Upon examination, the patient has an edentulous upper maxilla that had been rehabilitated with a full prosthesis. The four incisors and a second left premolar of an impossible prognosis (loss of insertion up to the apex) appeared to be missing in the inferior maxilla. The intermaxillary relationship was favorable and a slight alveolar ridge resorption was observed. On the other hand, the patient suffered chronic advanced periodontal disease (Figure 8). The following treatment plan was carried out:

Basic periodontal treatment

Consisting of oral hygiene instructions, scaling and root planing was performed and only in areas with remaining deep pockets surgery was carried out. Once the initial periodontal treatment objectives were met, we proceeded to plan the prosthesis phase.

Prosthetic treatment plan

A diagnostic wax-up and an upper and lower surgical guide were created. In order to create the upper surgical guide, the full upper prosthesis was doubled (which was appropriate with respect to the lip support and the occlusal and aesthetic criteria) and a surgical-radiological guide was developed without a vestibular side, thus making

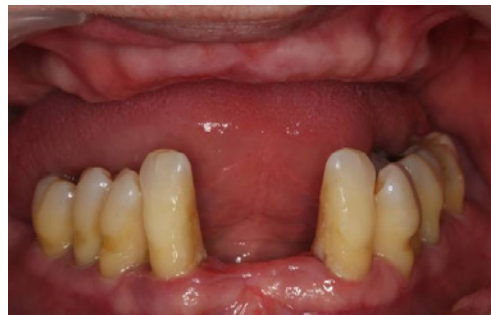

Figure 8: Initial intraoral image of the clinical situation to be rehabilitated. The patient presented advanced chronic periodontitis that was treated prior to commencing oral rehabilitation.

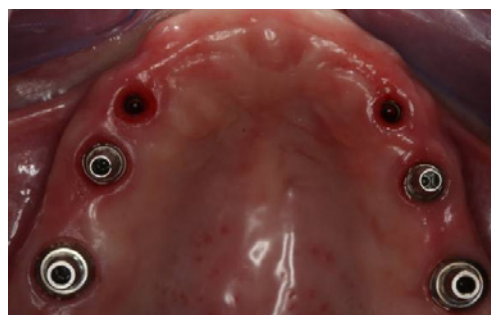
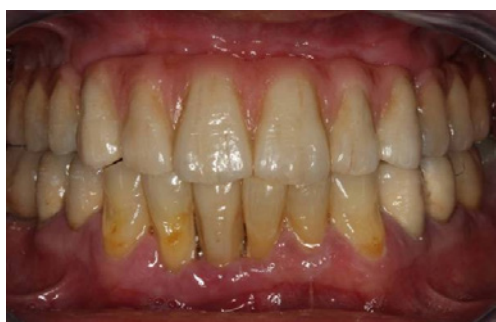
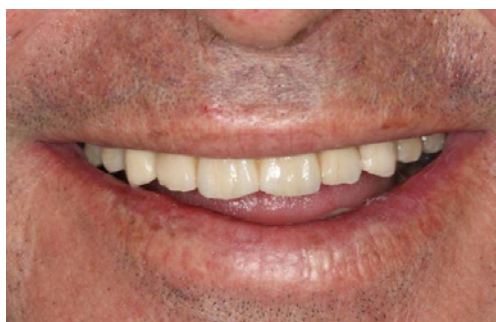Figure 9: Detail of the clinical situation before insertion of the oral rehabilitation. In this case, bone level® implants were used at the level of 13 and 23, and tissue level® implants were used in the posterior areas.



Figures 6: Intraoral rehabilitation aspect.



Figures 7: Extraoral rehabilitation aspect.

it possible to evaluate the patient's degree of lip support (lacking the support resin) and consider issues related to aesthetics and phonetics. Additionally, based on the analysis of the models in the articulator, it was determined that a tooth-supported fixed prosthesis with abutments in 33 and 43 was required—a procedure that would enable replacing the four missing lower incisors. The treatment choice was fixed prosthesis instead of an implant-supported prosthesis, given that the two inferior canine teeth were extruded, and in this manner, the alteration of the occlusal plane could be corrected [25]. Surgical extraction of 45 and immediate insertion of an implant during the same surgery was also planned. Based on the aforementioned reasons and after having evaluated the Denta-Scan, the surgical phase was carried out:

Surgical phase of placing implants: The following Straumann® SLA active surface implants were inserted (Figure 9) by using local anesthesia and intravenous sedation: Wide neck® at the level of 16 and 26, Standard plus® at the level of 14 and 24, TE® at the level of 45 (post-extraction) and 4.1 Bone level® at the level of 13 and 23. During the same surgical procedure, we also performed surgery to eliminate pockets in teeth 33-34-35-36-37 and 43-44-46.

Prosthetic rehabilitation:

Mandibular arch: An implant-supported metal-ceramic single crown was placed on tooth 45i. A synOcta® abutment for cementing was used and the screw-retained cemented crown technique was also used. This option was weighed against that of creating a screw-retained crown on the synOcta® abutment, given that posterior screw-retained crowns very often come loose [24].

- A tooth-supported metal-ceramic fixed prosthesis was placed

on 43pi-42-41-31-32-33pi. Rely-X® (3M ESPE) was used as cement.

Maxillary arch: (Figures10-14)

- Metal-ceramic implant-supported fixed prostheses were placed on synOcta abutments for cementing in posterior sections (14i-15-16i and 24i-25-26i). Both crowns were cemented with Premier Implant cement® (Premier Dental).
- A metal-ceramic implant-supported fixed prosthesis was placed on gold abutments for screwing into the anterior section (13i-12-11-21-22-23i).
- Posterior and anterior sections were connected using attachments made by Spark-erosion.

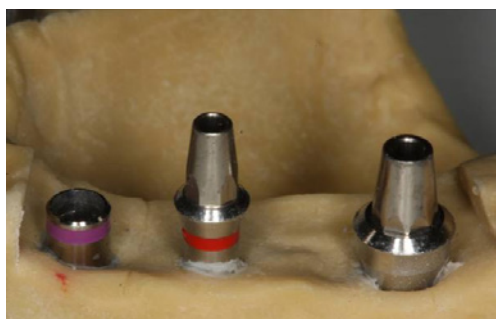
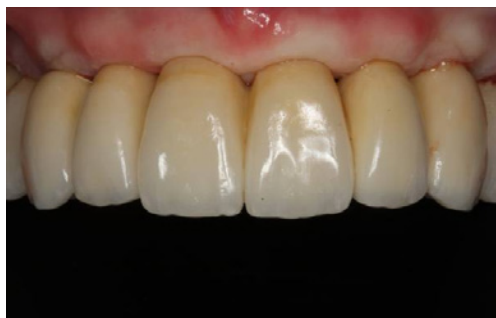
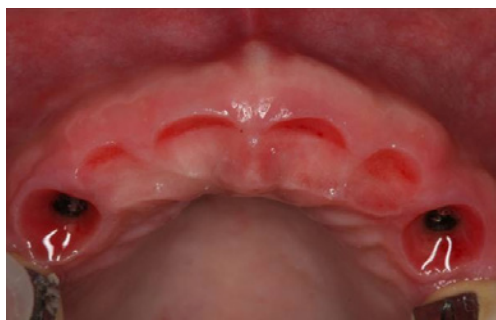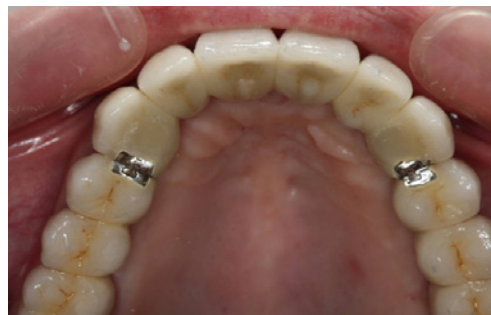Figure 10: Appearance of the synOcta® abutments to be cemented and the analogous of the Bone level® implant, which will be an abutment for the anterior screw-retained section.



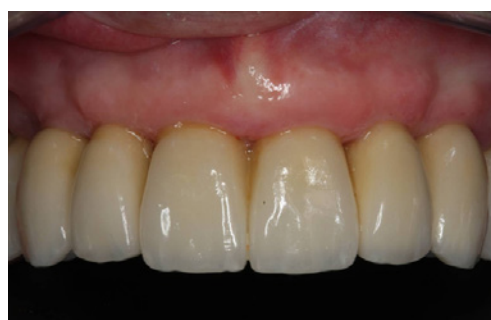Figures 11: The selective and sequential pressure (note the temporary ischemia that occurs) allows proper conformation of the gums in the pontic area, which minimizes aesthetic and phonetic complications.



Figures 12: Aspect of the pontic area after remotion of the anterior FDP.



Figures 13: Intraoral aspect of the oral rehabilitation.



Figures 14: Image of the tissue formation in the esthetic area one month after the insertion of the prostheses.

Discussion

Justification of the new approach to rehabilitation of the maxillary arch:

Advantage of cementing the posterior sections:

- Fewer incidents of mechanical problems (loosening) than with a screw-retained prosthesis [12].
- Less risk of aesthetic problems and/or fractures of the porcelain [17].
- The prosthesis may be removed in the event that it is necessary, provided that adequate cement is used [16,18-20].

Advantage of screwing in the anterior section and placing the implants at the level of the canines:

- It avoids the risk of leaving subgingival cement residue. In this area, the implants are usually seated somewhat deeper than in the posterior sections, making it difficult to remove the cement [21].
- Placement of the implants at the level of the canines enables an optimum alternation of abutments and pontics, and obtaining a more harmonious gingival architecture [22,23].
- The use of screw-retained prostheses, avoiding implants in the area of the incisors, enables optimum, selective and sequential pressure during the phase of inserting the prosthesis, which guarantees an excellent mucosal seal and minimizes the aesthetic, and above all, phonetic risks (Figures 11 and 12).
- Placing implants at the level of the canines enables correcting slight horizontal discrepancies (such as Angle Class III of the first case that we presented) without interfering with the

hygiene of the implants, which would result if they had been placed at the level of the incisors.

Advantage of working with sections connected by means of attachments:

- The placement of large implants with a curved structure is especially associated with significant levels of maladjustment, and consequently, makes it impossible to achieve an adequate passive fit [9,10]. Working in three sections reduces this risk.
- The connection of the three sections using attachments converts a structure into sections in a structure that is mechanically converted into a “horseshoe” (“cross arch bridge”). The use of spark-erosion for creating the attachments enables a much closer connection between the sections than when conventional cast or soldered attachments are used.
- In addition, attachments by spark-erosion do not block the connections, making possible to withdraw any of the sections independently while leaving the others in place (if desired). Thus, this offers an easy procedure for removing prostheses when necessary [24,25].

Conclusion

The purpose of both clinical cases is to document a new prosthodontic approach for rehabilitating the upper maxilla, which is based on the advantage of the prosthesis by means of sections, but guaranteeing its mechanical behavior by connecting the sections using spark-erosion attachments. At the same time, the new focus introduces the advantages of screw-retained and cemented prostheses, highlighting when the properties of each one of them can be more advantageous. Finally, the option of avoiding implants at the level of the incisors enables minimizing aesthetic and phonetic problems (by means of selective pressure in the pontics area), which also enables correcting certain conflicts at the horizontal level (such as a not very manifested Angle Class III), as can be seen in the first case illustrated by this clinical presentation.

Acknowledgements

The authors want to thank Damián Rodríguez (Dental technician. Laboratory specialized in passive fit by Spark-erosion and CAD-CAM, Málaga, Spain), Mr. Javier Pérez and Mrs. Beatriz Veiga (Dental technicians; Oral Design Centre, Lugo, Spain) and Juan Carlos Delgado (Dental technician, Ceramist. Oral Design. In memoriam) for their excellent laboratory works in the patients presented in this paper.

References

1. Jemt T (1991) Failures and complications of 391 consecutively inserted fixed prosthesis supported by Brånemark implants in edentulous jaws: A study of treatment from the time of placement to first annual check-up. *Int J Oral Maxillofac Implants* 6: 270-276.
2. Zitzmann UN, Marinello CP (1999) Treatment plan for restoring the edentulous maxilla with implant-supported restorations: Removable overdenture versus fixed partial denture design. *J Prosthet Dent* 82: 188-196.
3. Jemt T (1994) Fixed implant supported prosthesis in edentulous maxilla: a five year follow-up report. *Clin Oral Implants Res* 5: 142-147.
4. Heydecke G, Boudrias P, Awad MA, Albuquerque RF, Lund JP, et al. (2003) Within-subject comparisons of maxillary fixed and removable implant prostheses. Patient satisfaction and choice of prosthesis. *Clin Oral Implants Res* 14: 125-130.
5. Bryant SR, Jankowski D, Kim K (2007) Does the type of implant prostheses affect outcomes for the completely edentulous arch? *Int J Oral Maxillofac Implants* 22: 117-139.
6. Salenbauch MN, Langner J (1998) New ways of designing suprastructures for fixed-implant supported prostheses. *Int J Periodontics Restorative Dent* 18: 604-612.
7. Cabello G, González DA, Aixelá ME, Casero A, Jiménez J (2005) Biomecánica en implantología. *Periodoncia y Osteointegración* 9: 311-326.
8. Rübelling G (1999) New techniques in spark erosion: The solution to an accurately fitting screw-retained implant restoration. *Quintessence Int* 30: 38-43.
9. Jemt T, Lie A (1995) Accuracy of implant-supported prostheses in the edentulous jaw. *Clin Oral Implants Res* 6: 172-180.
10. Jemt T, Rubenstein JE, Carlsson L, Lang BR (1996) Measuring fit at the implant prosthodontic interface. *J Prosthet Dent* 75: 314-325.
11. Giménez Fábrega J (1996) Consideraciones Biomecánicas y de Oclusión en prótesis sobre implantes. *RCOE* 1: 63-76.
12. Weber HP, Sukotjo C (2007) Does the type of implant prostheses affect outcomes in the partially edentulous patient? *Int J Oral Maxillofac Implants* 22: 140-172.
13. Merz BR, Hunenbart S, Belser UC (2000) Mechanics of the implant-abutment connection: An 8-degree taper compared to a butt joint connection. *Int J Oral Maxillofac Implants* 15: 519-526.
14. Perriard J, Wiskott WA, Mellal A, Scherrer S, Botsis J, et al. (2002) Fatigue resistance of ITI implant-abutment connectors: A comparison of the standard cone with a novel internally keyed design. *Clin Oral Implants Res* 13: 542-549.
15. Çehreli MC, Akça K, İplikcioglu H, Sahin S (2004) Dynamic fatigue resistance of implant-abutment junction in an internally notched morse-taper oral implant: influence of abutment design. *Clin Oral Implants Res* 15: 459-465.
16. Chee W, Felton DA, Johnson PF, Sullivan DY (1999) Cemented versus screw-retained implant prostheses: which is better? *Int J Oral Maxillofac Implants* 14: 137-141.
17. Hebel KS, Gajjard RC (1997) Cement retained implant restorations: Achieving optimal occlusal and esthetics in implant dentistry. *J Prosthet Dent* 77: 28-35.
18. Michalakis KX, Hirayama H, Garefis PD (2003) Cement retained versus screw-retained implant restorations: A critical review. *Int J Oral Maxillofac Implants* 18: 719-728.
19. Covey DA, Kent DK, St Germain HA Jr, Koka S (2000) Effect of abutment size and luting cement type on the uniaxial retention force of implant supported crowns. *J Prosthet Dent* 83: 344-348.
20. Michalakis KX, Pissiotis AL, Hirayama H (2000) Cement failure loads of 4 provisional luting agents used for the cementation of implant-supported fixed partial dentures. *Int J Oral Maxillofac Implants* 15: 545-549.
21. Agar JR, Camerson SM, Hughbanks JC, Parker NH (1997) Cement removal from restorations luted to titanium abutments with simulated subgingival margins. *J Prosthet Dent* 78: 43-47.
22. Belser UC, Schmid B, Higginbottom F, Buser D (2004) Outcomes analysis of implant restorations located in the anterior maxilla: A review of the recent literature. *Int J Oral Maxillofac Implants* 10: 30-42.
23. Vailati F, Belser UC (2007) Replacement four missing maxillary incisor with a fixed dental prostheses. *Europ J Esthetic Dent* 2: 42-57.
24. Levine RA, Clem D, Beagle J, Ganeles J, Johnson P, et al. (2002) Multicenter retrospective analysis of the solid-screw ITI implant for posterior single-tooth replacements. *Int J Oral Maxillofac Implants* 17: 550-556.
25. Cabello Domínguez G, Casero Reina AI, Aixelá Zambrano ME, González Fernández DA, Giménez Fábrega J (2010) Pronóstico en prótesis fija implanto y dento soportada. Recomendaciones para un plan de tratamiento contemporáneo basado en la evidencia. *RCOE* 15: 33-50.