

# The Application of Digital Technology Aided Surgery to Temporomandibular Joint Ankyloses

Wei Bo, Yin Jia-Jia, Tao Ye, Feng Lin

Stomatology Department, Chinese PLA Hospital, China

## Abstract

**Objective:** To explore the effect of applying digital technology aided surgery to temporomandibular joint ankylosis (TMJA). **Methods:** A total of 17 cases of TMJA were involved to receive digital technology aided surgical treatment (digital technology aided surgery group). Besides, head model and navigation template intervention were designed by using digital technology aided approach. Furthermore, another 18 cases were treated with conventional arthroplasty (conventional surgery group). The operation time and the amount of bleeding were recorded in both groups, besides; curative effect was observed and evaluated postoperatively. **Results:** The duration of follow-up was 3~79 months, with an average of 46 months. A total of 17 cases were followed up in the digital technology aided surgery group, all of which achieved satisfied treatment outcome. In addition, 18 cases were followed up in the conventional surgery group, among which the results in 16 cases were satisfied, and 2 cases had recrudescence within 2 years after operation. Compared with the conventional treatment group, the amount of bleeding in the digital technology aided surgery group was less, the time of operation was shorter, and the difference after operation was statistically significant ( $P < 0.01$ ). **Conclusion:** The digital technology aided design of surgical procedure may contribute to the implementation of operation, especially for complex surgery with risk of recurrence. Meanwhile, it can also improve the accuracy of TMJA, shorten operative time and reduce operative bleeding. It is a safe and effective assistant method for surgical treatment of TMJA.

*Key Words:* Temporomandibular joint, Digital surgery, Ankylosis

## Introduction

Temporomandibular joint ankylosis (TMJA) is a serious lesion that destroys the structure of joints, mainly due to trauma, infection, etc [1,2]. It affects the growth and development of patients and the healthy diet. Surgical treatment is needed to relieve ankylosis, as well as improve patients' mouth opening and appetite, so as to increase their quality of life [3]. According to the different degree of TMJA, following methods are commonly applied, including distraction osteogenesis, autogenous coronoid process, costochondral rib graft, interposition of temporalis myofascial flap, folding of platysma myocutaneous flap, autogenous auricular cartilage interposition, autologous pericranium free grafting, as well as the application of new biological materials [4]. However, the risk and difficulty of TMJA are difficult to predict, such as intraoperative meningeal artery rupture, skull base perforating and bleeding volume. In recent years, the emergence and application of computer aided design and manufacturing (CAD/CAM) technology greatly improved the safety and precision of the operation [5]. Since 2009, our department has applied digital aided design to TMJA, and has made individualized plan for operation. It has accurately guided the location and bone volume determination of removing bone in TMJA operation. Furthermore, it effectively improves the accuracy of TMJ operation, shortens the operation time, reduces intraoperative bleeding, and has achieved satisfactory results. The purpose of this study was to compare the application and non-application of digital aided design of TMJA surgery, and to provide a reference for TMJA.

## Cases and Methods

### Clinical data

A total of 35 cases of patients with TMJA were treated in our department in December~2016 January 2009, of which 21 were male and 14 were female. Among them, 17 cases of TMJA received the treatment of digital technology aided surgery (digital technology aided surgery group), including 10 males and 7 females, with a mean age of 23.2 years (17~33 years). Another 18 cases were treated with conventional arthroplasty (conventional surgery group). The operation was selected according to the condition of the disease, including "sigmoid extensive osteotomy, costal cartilaginous joint reconstruction, semi-joint prosthesis knee joint reconstruction and artificial total joint replacement". In this group, there were 11 males and 7 females, with a mean age of 28.4 years ranging from 16~47 years.

### Data collection

CT plain scan and three-dimensional reconstruction were performed in all patients on the maxillofacial region, with a slice thickness of 1.00 mm. Scanning data were saved in acceptable DICOM format and imported in the ProPlan CMF 1.4 software. The maxillofacial cutting and three-dimensional reconstruction were performed with the obvious protruding point of intersection of three levels as the measurement datum. The nerve and vascular bundles of the upper and lower mandibles and the lower alveolus were identified in different colors, and then the final three-dimensional image of the jaw was obtained after software processing. According to the characteristics of the temporomandibular joint of the patient, surgery was simulated on the computer to make an auxiliary planning for the operation [6,7].

## Surgical design and operation planning

### Digital surgery simulation and guide plate making

- A computer simulation technique was used to design the relieving of ankylosis. The location and amount of bone removal were determined according to different surgical methods, including sigmoid extensive osteotomy, costal cartilaginous joint reconstruction, semi-joint prosthesis knee joint reconstruction and artificial total joint replacement, etc., in combination with the determination of autogenous bone graft or artificial joint implantation and permanent position.
- Mandibular guide plate: The position of the graft or prosthesis was prompted and fixed, followed by the exposure of bone cutting edge. The grinding bone depth was guided according to measured data, so that the bone graft or artificial prosthesis was fitted.
- Guide plate of the articular fossa: If the artificial total joint replacement was used, it was necessary to guide the articular fossa to take place. A guide plate was designed according to the position of the osteotomy to fit the lateral side of zygomatic arch. The final osteotomy height of the articular fossa was exposed, followed by grinding and trimming the lower part of the joint tubercle. The joint fossa measurement was classified according to the standard proposed by Oberg et al. The position of the artificial joint fossa was determined, the ankylosis was removed and the placement of the joint prosthesis was completed.
- Guide plate of ankylosis relieving: The hyperplastic bone ball was marked on the reconstruction model, and a guide plate was designed according to the bone mass needed to be removed to attach the surface of the bone ball closely. The position of osteotomy during ankylosis relieving was accurately marked, including the upper osteotomy line, the lower osteotomy line and the corresponding other osteotomy lines.
- After the design was completed, the surgical simulation was performed on the computer to measure the different osteotomy depth required for each position. Meanwhile, following situations were predicted, for example, whether the ideal osteotomy space was obtained after the prejudged osteotomy, whether the important structures such as the skull base, and whether important structures such as inferior alveolar nerve vascular bundle and the external auditory canal were damaged (Figure 1). Then, according to the designed guide plate, rapid prototyping (RP) technology was utilized to process and produce the model. It was possible to continue to be familiar with the process of operation on the model, communicate with the patient and family with it, and the guide board could be sterilized by low temperature plasma.

### Non-digital technology aided surgery design

X-ray or CT was used to observe the lesions, preset the osteotomy site, estimate the range of bone removal and bone removal, and design the operation plan.

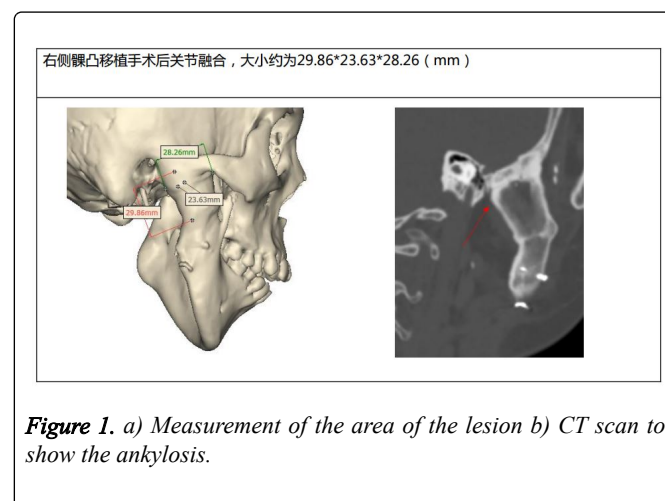
## Intraoperative application

### Digital technology aided surgery

After the success of general anesthesia through nasal intubation, modified approach of pretragal incision+posterior maxillary incision were performed to expose the joint tubercle, condyle and bone ball, as well as mandibular ramus. In accordance with the computer simulation operation scheme, the osteotomy guide plate was first placed to remove the hyperplastic bone and relieve the ankylosis. If the autogenous bone or artificial joint was needed, corresponding guide plate was used, and the bone surface was trimmed, besides, the implants were placed and fixed. For patients with artificial total joint replacement, intermaxillary ligation was conducted to fix the occlusal relationship and final position of the articular fossa was obtained. Besides, the edges of the periosteal bone were ground to smooth. The prosthesis of the articular fossa was fixed firmly at this time. The mandibular ramus was placed at the lower ramus of the mandible, which was ground to smooth according to schedule, and the mandibular prosthesis was implanted subsequently (Figure 2, Figure 3). The wound was sutured layer by layer and a negative pressure drainage tube was retained.

### Non-digital technology aided surgery

After the lesions were exposed, the bone was gradually removed and the ankylosis was relieved. If the autogenous bone or artificial half joint was needed, the implantation was performed after intermaxillary fixation, followed by immobilization.



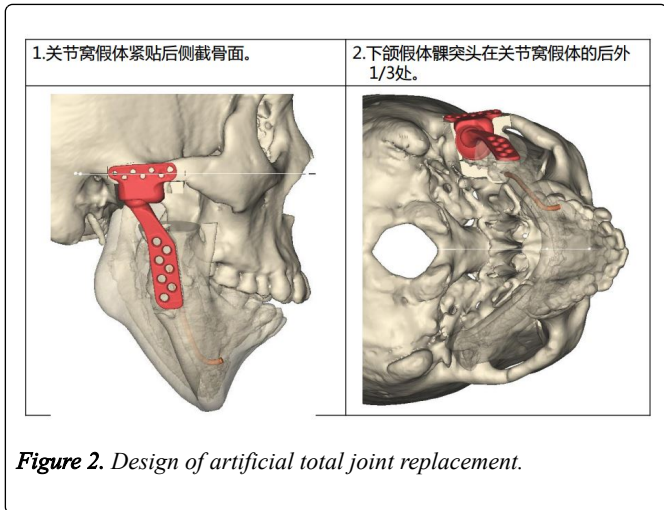


Figure 2. Design of artificial total joint replacement.

- The articular fossa was attached to the root of the zygomatic arch of the temporal bone. The mandibular prosthesis was fitted to the outer side of the mandibular ramus, and the condyle was located at the posterior 1/3 part of the artificial joint fossa.
- The condyle of artificial joint was located in the posterior 1/3 part of the artificial articular fossa.

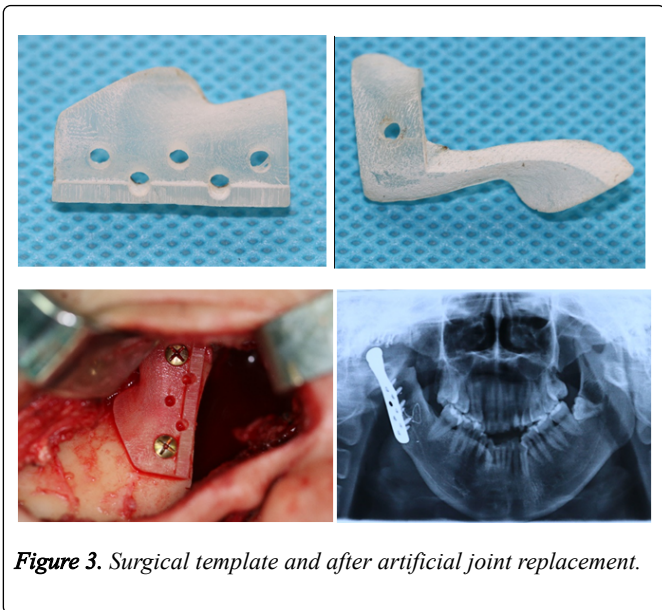


Figure 3. Surgical template and after artificial joint replacement.

### Data analysis

The time of digital assisted surgery and non-digital assisted surgery was compared, mainly recording the time to relieve the ankylosis and to relieve ankylosis plus fix implants. The experimental data were statistically analyzed by SPSS.17 software.

## Results

### Treatment of TMJA was carried out under the guidance of digital aided design

The surgeon not only observed the X-ray image before the operation, but also carefully observed the stimulated images after ankylosis relieving and the model printed by 3D, which might contribute to more comprehensive understanding of the dissection of the lesion, operation and possible problems.

Besides, it made the precise relieving of ankylosis and the accurate fixation of the autogenous bone or prosthesis become a reality. Under the guidance of the guide plate in the operation, the diseased bone tissue was quickly and accurately removed, the operation time was accelerated, and the surgical trauma was reduced at the same time (Table 1).

Table 1. Comparison of the amount of bleeding and the time of operation during the operation.

Operation mode	Cases	Amount of bleeding	Time relieving ankylosis	Total operation time
Digital technology aided surgery group	17	80 ml $\pm$ 20 ml	45 min $\pm$ 15 min	120 min $\pm$ 30 min
Conventional surgery group	18	200 ml $\pm$ 50 ml	90 min $\pm$ 30 min	210 min $\pm$ 48 min
t		2.73	2.34	2.27

### Non-digital technology aided surgery

X-ray or CT images were observed before operation to understand the extent of the lesion and to predict the part of the osteotomy. Osteotomy was gradually performed during the operation. It was necessary to trim the bone surface or bend titanium plate to fit the bone surface after implanting autogenous bone or artificial half joint.

### Follow-up

A total of 13 cases were followed up in digital technology aided surgery group, and 16 cases in conventional surgery group. The duration of follow-up was 3~79 months, with an average of 46 months. Compared with the conventional surgery group, the operation time of the digital technology aided surgery group was shorter and the bleeding was less during the operation. Corresponding statistical t values were shown in the table. There were significant differences in the amount of bleeding, the time of relieving ankylosis and the total operation time, indicating statistical significance ( $P < 0.01$ ). The postoperative function score was better than that of the conventional surgery group, but the difference was not statistically significant. This might be associated with fewer cases and relatively shorter duration of follow-up.

## Discussion

TMJA is a serious joint disease, which often causes facial deformity and affects the physical and mental health of the patients. Surgery is widely recognized as an effective treatment. It aims at relieving ankylosis, restoring patients' occlusal function, improving their facial morphology, and further promoting their mental health [8,9].

According to the articular stratigram, TMJA was divided into four types by Sawhney in 1985: Type 1: fibrous ankylosis; type 2: bone bridge formation of lateral joint; type 3: ossification of lateral joint; type 4: complete ossification of the whole joint structure. Corresponding operation method is adopted according to different degrees of disease. So far, major methods of treatment are gap arthroplasty, interpositional arthroplasty, reconstruction of autogenous or

artificial joint, etc. Extensive resection of the ankylosis is still considered as a major means of reducing recurrence. The choice of surgical procedures for TMJA depends mainly on the need to retain the remnants of the condyle. The remnants of the condyle are generally located in the anterior medial of the bone ball, with deep position and complex surrounding anatomy. There are great anatomic variations after the ankylosis, the vision of the surgeon can be restricted during the operation, and it is not easy to get the ideal operative effect. If the range of osteotomy is relatively small, the ankylosis cannot be removed, resulting in relatively larger range of osteotomy, and the skull base or the maxillary artery can be easily damaged, causing massive bleeding. Therefore, it is often exploratory to remove the bone gradually in a few times intraoperatively. Moreover, trimming after the removal of the ankylosis may lead to longer operation time and higher operation risk. Furthermore, the second operative area is also needed for patients with autologous bone graft that may increase patients' pain. Besides, there are risks of bone graft absorption, infection, and rejection of prosthesis implantation.

From the end of the 19th Century to the early 20th Century, some scholars used thin gold plate and button foil to replace the excised condyle for joint reconstruction. In 1950s, more scholars have made new developments in the design of artificial temporomandibular joint. In 1980s, three-dimensional images were obtained by Herman using surface feature extraction during CT scanning. In recent years, with the rapid development of medical imaging, image processing, and digital medicine, more updated technologies and services are applied to the field of surgery. Due to the characteristics of complex structure and function, maxillofacial surgery requires higher cosmetic results. Digital technology aided surgery is rapidly applied to preoperative diagnosis, design simulation and treatment.

Nowadays, some scholars have applied the technique of intraoperative navigation to TMJA operation to realize the real-time application of the three-dimensional reconstruction image of the patients in the operation. Schmelzeisen et al. performed arthroplasty in 2 cases under the guidance of navigation, and found that navigation technology could significantly improve the safety of surgery and reduce the incidence of complications. However, there are some problems in real time navigation. In addition to the unavoidable system errors, it also includes structural image drift, the instability of registration points selection and the complexity of operation, which will prolong the operation time and increase the exposure time of the operative area. When navigating, a positioner is placed on the head of the patient, and titanium nails need to be implanted to increase the discomfort of the patient. Besides, navigation requires operation by special personnel, associated with repeated calibration and positioning during the operation, and the patients must remain strictly inactive. For complex surgery, it is difficult to get the ideal operating space, which is more complicated. In addition, expensive navigation equipment also makes this surgical technique difficult to popularize quickly. In comparison, the digital aided design of the osteotomy guide

plate can solve these problems well. Repeated surgical simulations are performed on the computer preoperatively to prepare the osteotomy guide plate and pre-bending plate required, as well as prefabricated screw direction during the operation. In such way, no special personnel is needed for repeated calibration during the operation, and the operation is greatly simplified accordingly. A total of 13 patients were followed up in the digital technology aided surgery group, all of which reached the ideal opening and achieved satisfactory results. Without doubt, there are some problems in the application of the digital surgical aided design of preoperative guide plate. For example, the oversize of the guide plate and the undercut formation of the surface of the bone ball make it difficult for the guide plate to be in place smoothly. However, these problems can be foreseen and solved during the preoperative simulation of operation.

## Conclusion

In summary, digital technology aided surgical treatment of TMJA can significantly improve the accuracy and safety of the operation. It makes the operation of TMJA simpler, greatly reduces the exposure time of operation, and is of great significance to the surgical treatment of TMJA.

## References

1. Hong Min, Zhou Jilin. Further discussion on treatment of temporomandibular joint ankylosis with sigmoidectomy. *Oral and Maxillofacial Surgery*. 1994.
2. Giannakopoulos HE, Sinn DP, Quinn PD. Biomet microfixation temporomandibular joint replacement system: a 3-year follow-up study of patients treated during 1995 to 2005. *Journal of Oral and Maxillofacial Surgery*. 2012; **70**: 787-794.
3. Wolford LM, Mehra P. Custom-made total joint prostheses for temporomandibular joint reconstruction. *Proceedings (Baylor University Medical Center)*. 2000; **13**: 135-138.
4. Zhonglin L, Xiaoli C, Yi Z. Treatment of temporomandibular joint stiffness with jaw distraction osteogenesis: 1 case. *Journal of Oral and Maxillofacial Surgery*. 2004; **14**: 91-92.
5. Zhang SY, Liu H, Yang C, Zhang X, Abdelrehem A, et al. Modified surgical techniques for total alloplastic temporomandibular joint replacement: One institution's experience. *Journal of Cranio-Maxillo-Facial Surgery*. 2015; **43**: 934-949.
6. Bai G, Yang C, He D, Zhang X, Abdelrehem A. Application of fossa bone graft to stabilize stock total joint prosthesis in temporomandibular joint surgery. *Journal of Cranio-Maxillo-Facial Surgery*. 2015; **43**: 1392-1397.
7. Min H, Jian TX, Zeng QR, Kui LC, Feng LX, et al. The application of 3D printing technology in oral and maxillofacial surgery. *Chinese Journal of Practical Stomatology*. 2014; **7**: 335-339.
8. Sonnenburg M, Sonnenburg I. Development and clinical application of the total temporomandibular joint (TMJ) endoprosthesis. *Revue De Stomatologie Et De Chirurgie Maxillo-Faciale*. 1989; **91**: 165-169.
9. Wolford LM, Mercuri LG, Schneiderman ED, Movahed R, Allen W. Twenty-Year follow-up study on a patient-fitted temporomandibular joint prosthesis: The Techmedica/TMJ Concepts device. *Journal of Oral and Maxillofacial Surgery*. 2015; **73**: 952-960.