

Suspected Wilson's Disease Presenting with Normal Serum Ceruloplasmin Levels

Atul Singh Rajput*, Gunjan Singh Dalal and Jyoti Jain

Department of Biology and Medicine, Mahatma Gandhi Institute of Medical Sciences, India

Abstract

Wilson's disease, also known as 'Hepatolenticular degeneration' is a disorder of copper handling. The clinical picture parallels the pathophysiology with symptoms of basal ganglia (10 to 100%), cerebellar dysfunction (18 to 73%) and liver dysfunction (18 to 84%). The patient profile usually describes a young male or female with signs of cerebellar dysfunction (Ataxia, Dysarthria and Nystagmus), basal ganglia dysfunction (Choreoathetosis), Kayser Fleisher (KF) rings in cornea and hepatic involvement (any form of acute or chronic liver disease). The basic pathophysiology relates to improper handling of copper by the liver owing to the dysfunctional ATP7B gene. The diagnostic tests include an increased urinary copper excretion (100 ug/dl), reduced serum ceruloplasmin levels (< 25 mg/dl) and increased hepatic copper concentration (> 200 ug/gm of liver tissue). Although reduced serum ceruloplasmin levels are observed in most patients of Wilson disease, some proportion of patients particularly with acute hepatitis type of presentation can spuriously have raised ceruloplasmin levels thus posing the clinicians a diagnostic challenge especially in rural resource limited set ups. Presentations like these can be quite misleading as clinical suspicion index remains pretty low despite extensive laboratory work up. We report a case of such a patient of acute hepatitis with normal serum ceruloplasmin levels but significantly elevated urinary copper excretion. The patient showed wonderful response to oral zinc replacement evidenced with clinicobiochemical improvement.

Keywords: Wilson's; Hepatolenticular degeneration; Copper; Cerebellar; Hepatic; Kayser fleisher rings; ATP7B; Ceruloplasmin

Case Report

This patient a 34 years female presented with history of pain in right Hypochondrium, vomiting and yellowish discolouration of eyes. She had no history of fever/clay stools/itching/joint pains/hematuria/hepatotoxic drugs. She was not malenic and didn't give any history of spontaneous purpurae over the body. She had similar episodes of yellowish discolouration of her eyes, urine since she was 4. No history of blood transfusions/oral contraceptive pills. Steatorrhoea was absent. She hadn't had any rash in the past nor was arthralgia a complaint in the past. Her mother and her sister also had history of recurrent jaundice in the past, however the episodes being self-limiting.

She has stable hemodynamics and was deeply icteric upon admission. She didn't have any signs of coagulopathy/signs of chronic fat soluble vitamin deficiencies.

She was investigated to find the alanine and aspartate transaminases (>1000 IU/L). She had conjugated hyperbilirubinemia (Total bilirubin 19 IU/L, conjugated fraction of 12 IU/L). Alkaline phosphatase levels were only marginally raised 138 IU/L. Serum albumin was normal (4.2 mg/dl). Prothrombin time was prolonged with an INR of 2.3. The hemogram was perfectly normal with a normal peripheral smear (no Schistocytes/Microspherocytes) and so were the serum LDH levels. She had no feature of multi organ dysfunction. Urine had no RBC (dysmorphism/casts). She had no Hemoglobinuria/Myoglobinuria. An ultra-sonogram showed hepatosplenomegaly without any intrahepatic biliary radical dilatation. There was no thrombus in hepatic veins. There was no Cholelithiasis/ Cholelithiasis. Pancreas was normal.

A work up for causes of acute hepatitis was ordered only to reveal a negative viral /bacteriological screen, a normal antibody profile (ANA, SMA, LKM1, Soluble liver antigen and anti-mitochondrial antibodies) and normal inflammatory markers, Slit lamp examination didn't show any KF ring. However she had significantly raised urinary copper levels (340 ug/day), serum Ceruloplasmin levels were normal (32 mg/dl, N-25-40 mg/dl). Mutational analysis for testing of ATP7B couldn't

be done owing to financial constraints. Hepatic copper quantification was also not done. She was discharged with oral Zinc supplements and multivitamins to which she responded well with normalization of liver enzymes and urinary copper excretion.

Discussion

Wilson's disease, an autosomal recessive disorder is characterized by a mutated ATP7B enzyme [1-14]. The most common associated mutation is the H1069Q. ATP7B is a P-type ATPase that binds copper at the N-terminal domain and is responsible for the transport of copper across cellular membranes, using ATP as an energy source [15-17]. Figure 1 demonstrates the schematic representation of intracellular copper metabolism with the corresponding roles of ATP7A and B enzymes. The loading of ceruloplasmin levels is the crucial step for copper transport and is the affected process in the pathophysiology of Wilson's disease. The diagnostic clinicolaboratory set of a typical Wilson's is that of KF ring, pancerebellar dysfunction, liver insufficiency, raised urinary copper levels, reduced serum ceruloplasmin levels and raised hepatic copper deposition. Each of these peculiarities are met with some exceptions (Table 1) [18-23].

Serum ceruloplasmin a dubious biomarker in Wilson's

Ceruloplasmin a positive acute phase reactant rises in any form of

*Corresponding author: Atul Singh Rajput, Department of Biology and Medicine, Mahatma Gandhi Institute of Medical Sciences, Wardha, Maharashtra, India, Tel: +918390617843; E-mail: atl.rajput85@gmail.com

Received: September 09, 2016; Accepted November 02, 2016; Published November 09, 2016

Citation: Rajput AS, Dalal GS, Jain J (2016) Suspected Wilson's Disease Presenting with Normal Serum Ceruloplasmin Levels. Biol Med (Aligarh) 9: 362. doi: 10.4172/0974-8369.1000362

Copyright: © 2016 Rajput AS, et al. This is an open-access article distributed under the terms of the Creative Commons Attribution License, which permits unrestricted use, distribution, and reproduction in any medium, provided the original author and source are credited.

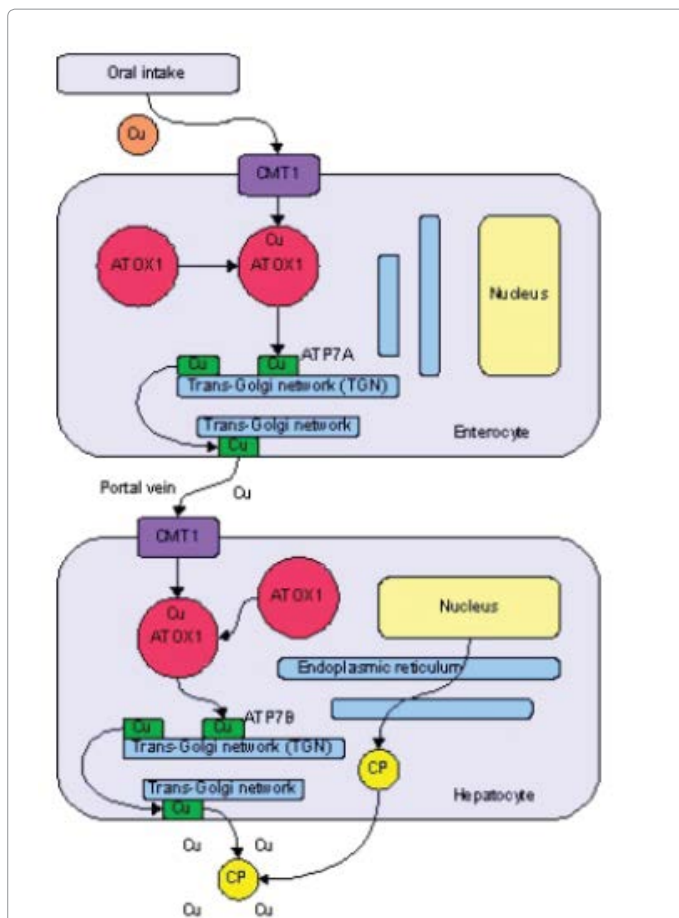


Figure 1: Schematic representation of intracellular copper handling by hepatocyte. Cu (Copper), CMT (Copper metal transporter), AT OX-Anti oxidant, CP (Ceruloplasmin) [18-20].

acute inflammation. It is a 132-kd protein synthesized by hepatocytes and secreted into the circulation. It is the major carrier of copper in the blood, with each molecule of ceruloplasmin carrying up to six copper atoms. Ceruloplasmin bound to copper is referred to as holoceruloplasmin (representing most of circulating ceruloplasmin), whereas ceruloplasmin that is not bound to copper is referred to as apoceruloplasmin. The genetic mutations causing Wilson disease impair the hepatic incorporation of copper into apoceruloplasmin, leading to a reduction in the total serum ceruloplasmin concentration due to the instability of the apoceruloplasmin relative to the holoprotein with its full complement of copper [24,25].

Serum ceruloplasmin alone has a low positive predictive value in patients undergoing evaluation for liver disease. One of the largest prospective studies to assess the value of serum ceruloplasmin in patients with liver disease focused on 2867 patients, of whom 17 had a low serum ceruloplasmin (<20 mg/dL or 200 mg/L). Only one of these patients was ultimately diagnosed with Wilson disease (positive predictive value of 6%) [13]. The other patients with low serum ceruloplasmin concentrations had a variety of conditions:

1. Heterozygous carriers for Wilson disease (three patients)
2. Acute viral hepatitis (three patients)

Parameter	Pathophysiology	Incidence in Wilson's disease	Remarks
KF rings	Copper deposition in Descemet's membrane of cornea	50% in non neurological 90% in neurological	Less sensitive ,but more specific
Neurologic dys-function	Copper deposition in basal ganglia,thalamus and brainstem	11-95%	Myriad of presentations seen in wilson disease
Hepatic involvement	Hepatic copper accumulation	25-90%	Any form of acute/ chronic liver disease
Increased urinary copper excretion	Ineffective biliary copper excretion	~ 75%	levels > 100ug/day specific for wilson's
Reduced serum ceruloplasmin	Ineffective conversion of apoceruloplasmin to ceruloplasmin	~ 80%	PPV of 5%, can be falsely low or high
Increased hepatic copper	Improper liver copper efflux	~ 70%	Patchy deposition inchronic liver disease leading to uneven distribution and high false negatives
ATP 7B mutations	H1069Q mutations most common	> 95%	Vast variety in type of mutations

Table 1: Characteristic clinicolaboratorial manifestations of Wilsons disease with their incidences [9,11,14,21-23].

3. Chronic hepatitis (two patients)
4. Drug-induced liver disease (three patients)
5. Alcohol-induced liver disease (two patients)
6. Malabsorption (three patients)

Approximately 10 to 20% of asymptomatic heterozygous carriers have serum ceruloplasmin concentrations less than 20 mg/dL (200 mg/L) [26]. Other causes of low serum ceruloplasmin concentrations include

1. Disorders that cause marked renal or enteric protein loss, such as nephrotic syndrome or protein-losing gastroenteropathy.
2. End-stage liver disease of any cause with associated poor synthetic function for production of all hepatic proteins.
3. Rare diseases such as Menkes disease (an X-linked disorder of copper transport leading to decreased intestinal copper absorption) and aceruloplasminemia (a rare disorder leading to the absence of ceruloplasmin and problems in iron metabolism).
4. Copper deficiency (e.g., due to inadequate copper inclusion in parenteral nutrition, malabsorption following gastric bypass surgery, excessive zinc administration, or idiopathic deficiency) [27].

On the other hand, serum ceruloplasmin concentrations may be normal or elevated in patients with Wilson disease. One cause of normal serum ceruloplasmin in patients with Wilson disease is the presence of acute hepatitis, which can increase serum ceruloplasmin values to the normal range. Other causes include pregnancy, estrogen supplementation, and use of oral contraceptives since the mRNA for ceruloplasmin has an estrogen responsive upstream region for its transcription [25]. In addition, ceruloplasmin is an acute phase

reactant, so levels may be elevated in the setting of inflammation and tissue injury.

In addition, the method used for measuring ceruloplasmin may influence the results. Serum ceruloplasmin can be measured enzymatically, by antibody-dependent assays, by radial immunodiffusion, and by nephelometry. The results are generally similar, except for the antibody-dependent and the immunodiffusion assays, which may overestimate the ceruloplasmin levels. The over estimation may occur because the two testing methods do not discriminate between apoceruloplasmin and holoceruloplasmin [28]. Determination of ceruloplasmin activity using a method based on oxidation of 0-dianisidine dihydrochloride had sensitivity and specificity of 94 and 100 percent in one report, but more studies are needed [29].

Leipzig's score

European association for study of liver recommends Leipzig's score for diagnosis of Wilson's disease [26]. A score of 1 or 2 after all work up excludes the diagnosis of Wilson's disease. This scoring system couldn't be applied in this patient as we couldn't do a mutational analysis.

Ferenci in his mammoth research also concludes that there has been no single large randomised controlled trial that establishes a consensus on Wilson's disease diagnosis [12].

This case had normal serum ceruloplasmin levels which are compatible with the inflammatory rise in the state of acute hepatitis. Although the KF rings were absent, but considering the enormously enhanced urinary copper excretion and the clinicobiochemical response to zinc supplementation, the diagnosis of Wilson's disease is vivid. This case highlights the clinical mosaicism observed in Wilson's disease and represents that one example amongst the wide varieties of presentations ranging from a completely asymptomatic individual (detected only by genetic test-ing) to that of full blown hepatolenticular degenerative state.

Conclusion

Clinicians must always be skeptical about the clinical behavior of Wilson's disease. They must not get blinded by the biochemical picture rather should always rely upon the clinical acumen and a critical correlation and interdependence between the two.

References

- Gollan JL, Gollan TJ (1998) Wilson disease in 1998: genetic, diagnostic and therapeutic aspects. *J Hepatol* 1: 28-36.
- Machado A, Chien HF, Deguti MM, Cancado E, Azevedo RS, et al. (2006) Neurological manifestations in Wilson's disease: Report of 119 Cases. *Movement disorders. Official Journal of the Movement Disorder Society* 21: 2192-2196.
- Soltanzadeh A, Soltanzadeh P, Nafissi S, Ghorbani A, Sikaroodi H, et al. (2007) Wilson's Disease: A Great Masquerader. *European Neurology* 57: 80-85.
- Taly AB, Meenakshi-Sundaram S, Sinha S, Swamy HS, Arunodaya GR (2007) Wilson Disease: Description of 282 Patients Evaluated Over 3 Decades. *Medicine* 86: 112-121.
- Lorincz MT (2010) Neurologic Wilson's Disease. *Annals of the New York Academy of Sciences* 1184: 173-187.
- Lau JY, Lai CL, Wu PC, Pan HY, Lin HJ, et al. (1990) Wilson's Disease: 35 Years' Experience. *The Quarterly Journal of Medicine* 75: 597-605.
- Pfeiffer RF (2007) Wilson's Disease. *Seminars in neurology* 27: 123-132.
- Cater MA, La Fontaine S, Shield K, Deal Y, Mercer JF (2006) ATP7B mediates vesicular sequestration of copper: insight into biliary copper excretion. *Gastroenterology* 130: 493-506.
- McDonald JA, Snitch P, Painter D, Hensley W, Gallagher ND, et al. (1992) Striking variability of hepatic copper levels in fulminant hepatic failure. *Journal of gastroenterology and hepatology* 7: 396-398.
- Faa G, Nurchi V, Demelia L, Ambu R, Parodo G, et al. (1995) Uneven hepatic copper distribution in Wilson's disease. *Journal of hepatology* 22: 303-308.
- Steindl P, Ferenci P, Dienes HP, Grimm G, Pabinger I, et al. (1997) Wilson's disease in patients presenting with liver disease: a diagnostic challenge. *Gastroenterology* 113: 212-218.
- Ferenci P, Steindl-Munda P, Vogel W, Jessner W, Gschwantler M, et al. (2005) Diagnostic value of quantitative hepatic copper determination in patients with Wilson's Disease. *Clinical gastroenterology and hepatology: the official clinical practice journal of the American Gastroenterological Association* 3: 811-818.
- Cauza E, Maier-Dobersberger T, Polli C, Kaserer K, Kramer L, et al. (1997) Screening for Wilson's disease in patients with liver diseases by serum ceruloplasmin. *Journal of hepatology* 27: 358-362.
- Gow PJ, Smallwood RA, Angus PW, Smith AL, Wall AJ, et al. (2000) Diagnosis of Wilson's disease: an experience over three decades. *Gut* 46: 415-419.
- Figus A, Angius A, Loudianos G, Bertini C, Dessi V, et al. (1995) Molecular pathology and haplotype analysis of Wilson disease in Mediterranean populations. *American journal of human genetics* 57: 1318-1324.
- Thomas GR, Forbes JR, Roberts EA, Walshe JM, Cox DW (1995) The Wilson disease gene: spectrum of mutations and their consequences. *Nature genetics* 9: 210-217.
- Nanji MS, Nguyen VT, Kawasoe JH, Inui K, Endo F, et al. (1997) Haplotype and mutation analysis in Japanese patients with Wilson disease. *American journal of human genetics* 60: 1423-1429.
- Lutsenko S, Efremov RG, Tsvikovskii R, Walker JM (2002) Human copper-transporting ATPase ATP7B (the Wilson's disease protein): biochemical properties and regulation. *Journal of bioenergetics and biomembranes* 34: 351-362.
- La Fontaine S, Mercer JF (2007) Trafficking of the copper-ATPases, ATP7A and ATP7B: role in copper homeostasis. *Arch Biochem Biophys* 463: 149-167.
- Lutsenko S, LeShane ES, Shinde U (2007) Biochemical basis of regulation of human copper-transporting ATPases. *Archives of biochemistry and biophysics* 463: 134-148.
- LaRusso NF, Summerskill WH, McCall JT (1976) Abnormalities of chemical tests for copper metabolism in chronic active liver disease: differentiation from Wilson's disease. *Gastroenterology* 70: 653-655.
- Stremmel W, Meyerrose KW, Niederau C, Hefter H, Kreuzpaintner G, et al. (1991) Wilson disease: clinical presentation, treatment, and survival. *Annals of internal medicine* 115: 720-726.
- Giacchino R, Marazzi MG, Barabino A, Fasce L, Ciravegna B, et al. (1997) Syndromic variability of Wilson's disease in children. *Clinical study of 44 cases. Italian journal of gastroenterology and hepatology* 29: 155-161.
- Gibbs K, Walshe JM (1979) A study of the caeruloplasmin concentrations found in 75 patients with Wilson's disease, their kinships and various control groups. *The Quarterly journal of medicine* 48: 447-463.
- Brewer GJ, Yuzbasiyan-Gurkan V (1992) Wilson disease. *Medicine* 71: 139-164.
- Easl (2012) Clinical Practice Guidelines: Wilson's disease. *Journal of hepatology* 56: 671-685.
- Kumar N, Gross JB, Ahlskog JE (2004) Copper deficiency myelopathy produces a clinical picture like subacute combined degeneration. *Neurology* 63: 33-39.
- Dufour JF, Kaplan MM (1997) Muddying the water: Wilson's disease challenges will not soon disappear. *Gastroenterology* 113: 348-350.
- Merle U, Eisenbach C, Weiss KH, Tuma S, Stremmel W (2009) Serum ceruloplasmin oxidase activity is a sensitive and highly specific diagnostic marker for Wilson's disease. *Journal of hepatology* 51: 925-930.