

# Secondary Interventions Following Endovascular Repair of Aortic Dissections

Sophia Khan, Francis J Caputo, Jose Trani, Jeffrey P Carpenter and Joseph V Lombardi\*

Division of Vascular & Endovascular Surgery, Cooper University Hospital, Camden, NJ, USA

## Abstract

**Objectives:** Review the literature on secondary interventions performed for patients who underwent endovascular repair of their type B aortic dissection. Endovascular repair for TBAD has been proven to be both technically feasible and beneficial in some patients. However, the information regarding secondary interventions is not cohesive. To date, there is little data to help guide physicians on the indications and benefits of secondary interventions in the setting of previous endovascular repair for TBAD.

**Methods:** PubMed database was queried for publications using the following combination of keywords: “aortic dissection” “type B” “secondary intervention” “false lumen thrombosis” “stent graft” “aortic remodeling” and endovascular repair. Sixteen articles were selected and reviewed for secondary interventions, indications for procedure and effects on false lumen thrombosis. Data was collected and a composite database of patients was created.

**Results:** Literature review demonstrated 161 of 862 patients required secondary interventions for entry tears, retrograde type A dissection, false lumen degeneration with aortic expansion, graft malfunction and various access complications. The complete false lumen thrombosis rate was 33% and overall mortality was 18.2%.

**Conclusions:** Secondary interventions provide a useful adjunct to failing endovascular repair of aortic dissections. A variety of treatment options are available for aneurysmal degeneration post TEVAR. This review also shows that these secondary interventions, in combination with proper surveillance and optimal medical management, are feasible but carry high all-cause mortality.

**Keywords:** Aneurysm; Embolization; Lumen Thrombosis

## Introduction

Type B dissections treated with TEVAR, ultimately stabilize and remodel via progressive false lumen thrombosis, but in those that do not, there is an increased risk of aneurysmal dilatation and aortic rupture [1,2]. Very little attention has been brought to the natural progression of this disease state after TEVAR and intervention that could alter the progression of aneurysmal degeneration after TEVAR. Primary entry tear coverage is a paramount first step to successfully exclude the false lumen [3,4]. While stent grafts are a beneficial tool in the treatment of aortic dissections, it fails to achieve complete false lumen thrombosis in up to 50% of patients [5]. Several studies have utilized secondary interventions to promote false lumen thrombosis and positive aortic remodeling. These adjuncts include additional aortic endografts, coil embolization or conversion to open surgical repair as early as the initial procedure and as late as several years from in the index intervention [4,6-20]. However, to date there is no cohesive body of evidence that shows the benefit of secondary interventions for type B dissections. The purpose of this review is to summarize the available data to help determine the utility of secondary interventions on aortic remodeling and prevention of late aneurysm formation associated with type B aortic dissections initially managed with TEVAR.

## Methods

The PubMed database was searched for publications using the following combination of keywords: “aortic dissection” “type B” “secondary intervention” “false lumen thrombosis” “stent graft” “aortic remodeling” and “endovascular repair.” This search produced 584 candidate articles. Of these articles identified, those which did not pertain to the subject matter, were not translated into English, case reports and case series were eliminated, yielding 134 articles. An additional 14 articles were added after reviewing citations from the original 134 articles. Inclusion criteria included those papers which discussed types of secondary interventions, clearly identified aortic pathology as type B dissection, effect on aortic remodeling and were written between January 2000 and present. Manuscripts were excluded if they failed to discuss (1) secondary interventions (2) aortic false lumen thrombosis (3) indication for secondary intervention. Twenty-two articles were then reviewed by F.C. and S.K. If multiple articles were written by the same author(s), the most recent article and/or the article which more clearly fit our inclusion parameters were included. Using this search strategy (Table 1 and Figure 1) a total of 16 articles (Table 2) were identified which included 161 secondary interventions.

	Number in category remaining	Number
Initially retrieved	584	
<b>Excluded as not relevant by title or abstract</b>	450	134
Citations identified through references of reviewed manuscripts	14	148
<b>Excluded (after review of manuscript)</b>	132	16
<b>Included</b>		16
Aortic series with 161 secondary interventions		

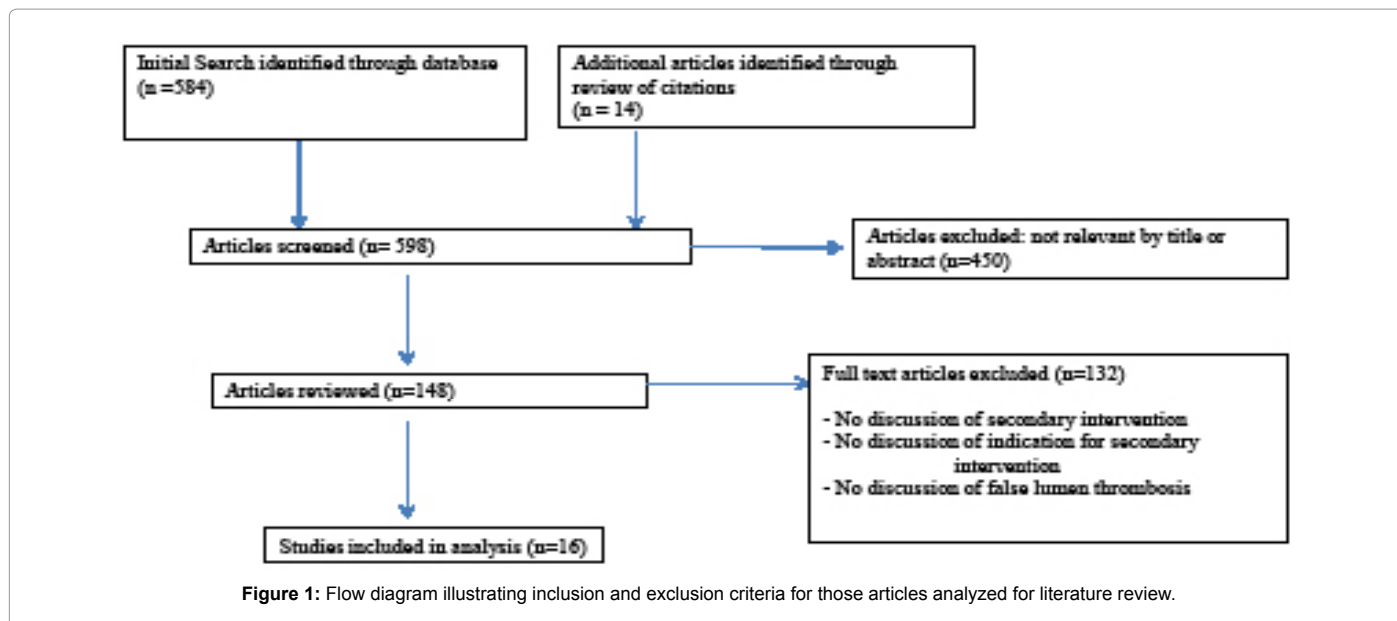
**Table 1:** Literature review selection process.

\*Corresponding author: Joseph V Lombardi, Division of Vascular & Endovascular Surgery, Cooper University Hospital, Camden, NJ, USA, Tel: 856-342-2151; E-mail: Lombardi-Joseph@cooperhealth.edu

Received July 24, 2014; Accepted September 23, 2014; Published September 25, 2014

**Citation:** Khan S, Caputo FJ, Trani J, Carpenter JP, Lombardi JV (2014) Secondary Interventions Following Endovascular Repair of Aortic Dissections. J Vasc Med Surg 2: 155. doi: 10.4172/2329-6925.1000155

**Copyright:** © 2014 Khan S, et al. This is an open-access article distributed under the terms of the Creative Commons Attribution License, which permits unrestricted use, distribution, and reproduction in any medium, provided the original author and source are credited.



Author	Endoleaks	SI	RAAD	SI	Persistent false lumen degeneration	SI	Graft malfunction	SI
Bockler 2006 <sup>6</sup>	1	Extension of proximal graft (n=1)	-----	-----	-----	-----	-----	-----
Chemelli 2010 <sup>7</sup>	2	Secondary TEVAR (n=2)	3	Open conversion (n=3)	-----	-----	-----	-----
Feezor 2009 <sup>8</sup>	-----	-----	-----	-----	3	Surgical replacement of descending thoracic aorta (n=3)	-----	-----
Flecher 2008 <sup>9</sup>	2	Endograft (n=1) Percutaneous occlusion of LSA (n=1)	-----	-----	1	Open surgical repair (n=1)	-----	-----
Kang 2011 <sup>10</sup>	3	Additional stent graft (n=1) Coil embolization of LSA (n=1) Frozen elephant trunk (n=1)	3	Aortic arch replacement (n=3)	9	Stent graft (n=4) Open repair (n=4) Frozen elephant (n=1)	3	Ballooning of stent graft (n=2) Additional stent graft (n=1)
Khonynezhad 2009 <sup>11</sup>	-----	-----	-----	-----	-----	-----	1	Palmaz stent placement (n=1)
Lambrechts 2003 <sup>12</sup>	-----	-----	-----	-----	3	Additional stent graft (n=2) Exclusion replacement of thoracoabdominal aorta with left assist device and reimplantation of celiac trunk, SMA, and renals	-----	-----
Lee 2013 <sup>13</sup>	9	Open repair (n=3) Balloon approximation of stent graft (n=1) Stent graft (n=1) Bare stent (n=2) Bare stent/stent graft (n=1) Stent graft with neck vessel bypass (n=1)	4	Open aortic arch repair (n=4)	13	Stent graft (n=5) Open repair (n=6) Stent graft/open repair (n=1) Embolization (n=1)	1	Open repair (n=1)
Nienaber 2009 <sup>4</sup>	-----	-----	1	Open aortic arch repair (n=1)	7	Open conversion (n=1) Additional stent graft (n=6)	-----	-----
Oberhuber 2011 <sup>14</sup>	-----	-----	1	Open aortic arch repair (n=1)	8	Additional endografting (n=7) Open surgical repair (n=1)	-----	-----
Parsa 2010 <sup>15</sup>	5	Coil embolization (n=2) Additional endovascular repair (n=3)	-----	-----	6	Open conversion (n=1) Endografting (n=5)	2	Palmaz bare metal stent placement (n=2)
Qin 2012 <sup>16</sup>	4	Proximal stenting (n=2) LSA embolization (n=2)	3	Open surgical repair (n=3)	7	Secondary TEVAR (n=7)	-----	-----

Rodriguez 2008 <sup>17</sup>	3	Stent graft (n=2) Stent graft + coil embolization of LSA (n=1)	-----	-----	-----	-----	-----	-----
Scali 2013 <sup>18</sup>	-----	-----	1	Open aortic arch repair (n=1)	21	Open conversion with TEVAR explant (n=5) Embolization (n=5) Visceral/iliac stent graft (n=3) Carotid-subclavian bypass (n=1) Extension of endograft (n=5)	-----	-----
Shu 2011 <sup>19</sup>	1	Extension of endograft (n=1)	-----	-----	-----	-----	-----	-----
Szeto 2008 <sup>20</sup>	1	Coil embolization of LSA (n=1)	1	Open repair (n=1)	1	Aortic root replacement (n=1)	-----	-----

Table 2: Articles Reviewed with Respective Secondary Interventions.

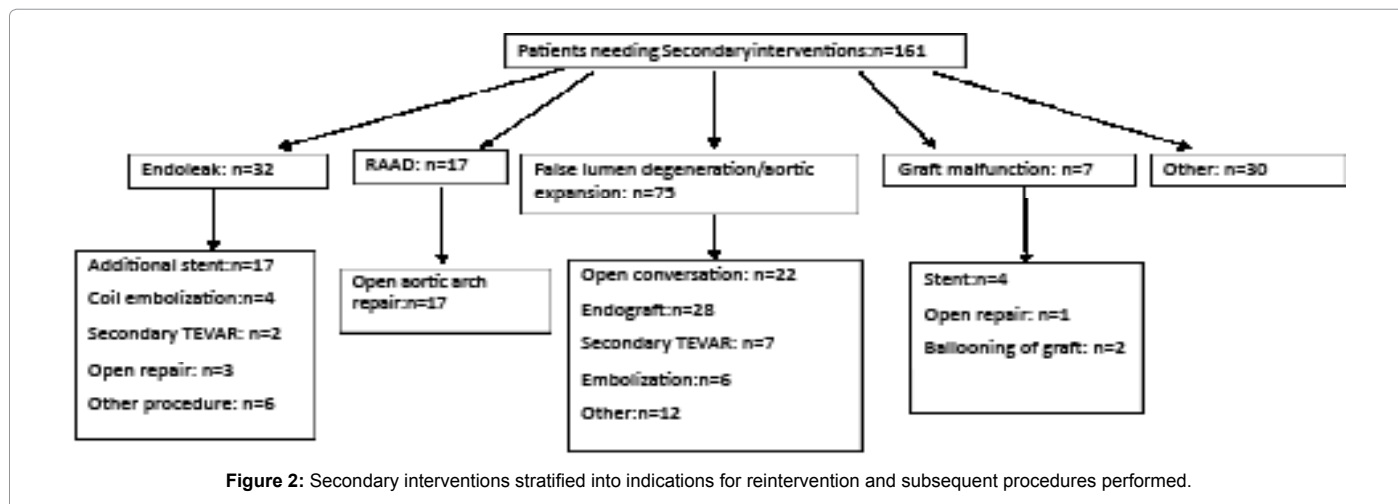


Figure 2: Secondary interventions stratified into indications for reintervention and subsequent procedures performed.

After identifying all of the secondary interventions from manuscripts that fulfilled our inclusion criteria, they were divided into four categories - entry flow, retrograde aortic dissection, aneurysmal degeneration, and graft malfunction. We then surveyed the articles for effects on aortic remodeling and false lumen thrombosis. Patients were subcategorized into those with complete or partial false lumen thrombosis. Primary endpoints of the study included false lumen thrombosis, 30-day mortality rates following the initial repair and overall mortality rates. The individual results from each paper were compiled to create a composite, which then became our data set for this study.

## Results

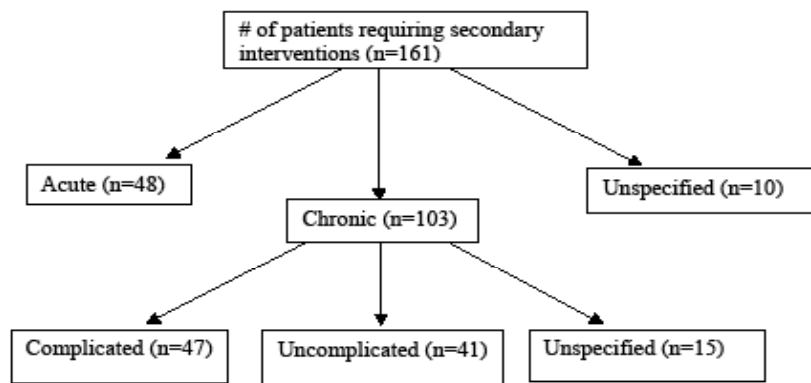
A total of 16 articles (Table 2) included 862 patients who underwent thoracic endovascular stent graft repair for type B aortic dissection. Fourteen of the 16 studies identified the TBAD included in their analysis as chronic or acute. A total of 396 (45.9%) were identified as acute and 446 (51.7%) as chronic TBAD. The mean age of the study population was 58.8 years and 77.2% of the study population was male. In this study population 161(18.7%) patients underwent secondary interventions for various indications including aortic expansion, retrograde type A aortic dissection, entry flow resulting in persistent false lumen flow or rapid increase in aortic diameter, degeneration of the false lumen or malfunction of the endograft device (Figure 2). Of the 161 patients requiring secondary interventions, 48 (29.8%) initially presented with acute TBAD and 103 (63.9%) with chronic TBAD (Figure 3). Secondary interventions included coil embolization, extension of the graft, secondary TEVAR, replacement of aortic arch, conversion to open

surgery, and arch vessel bypass procedures. The complete false lumen thrombosis rate in this population was 33.7% (284/842) and the partial false lumen thrombosis rate was 49.7% (310/624) at an average mean follow up of 36.8 months. Technical success with adequate placement of the endograft was achieved in 97.5% of the patient population. The 30-day mortality rate amongst the studies in this data set was approximately 6.2% and overall mortality was 18.2%.

Retrograde type A aortic dissection occurred in 16 patients of the study population. Although, there is evidence that this complication is related to landing the proximal graft into unhealthy aorta, no such documentation was available in these reports [21]. In all, but one patient with retrograde type A dissection, an open surgical intervention was taken with replacement of the aortic arch.

The most significant complication after endovascular grafting of the aorta was persistent flow through the false lumen leading to aneurysmal degeneration, aortic expansion and/or aortic rupture. Seventy-five patients encountered this post-operative complication. Twelve patients were listed specifically by the location of which there was false lumen expansion; 6 had enlargement of the thoracic aorta and 6 had enlargement of the abdominal aorta. Twenty-eight patients had additional endograft stenting procedures and 22 underwent open surgical repair. Seven patients had secondary TEVARs. One patient had a complete thoracoabdominal reconstruction.

Type I entry flow occurred with perfusion of false lumen flow either proximal or distal to the endograft. This was the most common type of entry flow in this cohort of patients with 27 instances identified. Type I entry flow were primarily repaired with additional stent graft



**Figure 3:** Secondary interventions stratified into those patients who initially presented with acute type B aortic dissection or chronic type B aortic dissection. Those patients who initially presented with chronic type B aortic dissection were then stratified into those with complicated and uncomplicated chronic dissections.

placement proximally or distally (n=13). Another frequent intervention noted was conversion to open surgical repair (n=8). Furthermore, 6 patients with type I entry flow were treated early and 6 were treated late after initial TEVAR.

Type II entry flow, defined as retrograde filling of the false lumen via collateral blood vessels, was commonly found in the lumbar arteries, intercostal arteries or the left subclavian artery. Ten patients in this cohort had a type II entry flow subsequent to their endovascular repair identified, of which only 5 patients underwent secondary intervention. Coil embolization of the left subclavian artery occurred in 3 patients for reentry tears within the left subclavian artery and coil embolization of other collateral vessels providing flow to the false lumen occurred in the remaining patients. Type III entry flow, which occur at overlap zones between two grafts, were the least common type of entry flow encountered (n=2) and were repaired with secondary TEVAR.

Various studies published data regarding failures of the thoracic endograft device itself. Six patients had technical complications with the graft; 5 had endograft collapse and 1 had kinking of the endograft. Two endografts collapsed at the proximal portion of the graft and 3 at the distal portion of the graft. Each of these patients had an endovascular repair of their endograft collapse with either a Palmaz stent placement, ballooning of the endograft or additional stent grafting. The patient with the endograft kinking underwent open surgical repair.

Many of the studies do not include data regarding outcomes after reintervention. From the studies that included this data, it appears that reintervention for aortic rupture and conversion to open repair carry the greatest mortality rates. In this series of patients, 6 patients died after either conversion of TEVAR to open surgical repair or after repair from aortic arch replacement. In some instances despite reintervention for retrograde type A dissection, patients still had aortic rupture, emphasizing both the importance of monitoring for this complication and its effects on mortality rates after TEVAR in patients with type B aortic dissection.

## Discussion

While studies have shown that endovascular repair is both a technically feasible option and appears favorable when compared to mortality rates in open surgical repair [22], it carries with it its own limitations, complications and risks that extend long term. Failure to prevent aneurysm formation or control persistent pain require further intervention which conceptually may lead to decreased rates

of rupture. Our review of the literature has provided an overview on the management of complications following TEVAR for type B aortic dissection but do not elaborate on success on remodeling. The all-cause mortality for failing TEVAR repair of TBAD is a notable 18.2%.

Despite the ability of the endograft to cover the proximal entry tear leading to aortic remodeling, continued re-entry flow into the false lumen is quite common. Review of the current literature suggests that the initial stent graft only achieves both thoracic and abdominal false lumen obliteration in only 50% of patients [5]. Since the focus of our literature review was secondary interventions, this low rate of thrombosis is not surprising as it is skewed toward patients failing initial therapy in our review. Patients underwent either additional endovascular repair, open surgical repair, or combined procedures. Whether type B aortic dissections are treated with only medical therapy or endovascular repair, the data presented here echoes that strict follow-up surveillance is necessary for this disease process.

Entry tears and reentry flow occurred frequently in this cohort of patients and those with type I entry tears after TEVAR should undergo additional stent graft repair with extension of the graft to prevent continued false lumen flow and aortic enlargement. A frequently missed observation of persistent flow via the subclavian artery can also be falsely interpreted as a type I entry flow and should always be kept in the differential. Patients with type II entry flow should be managed based on aortic diameter characteristics after TEVAR. Those patients with stable aortic diameters after TEVAR may be managed conservatively with routine surveillance. Those that have progressive aortic enlargement (>0.5 cm /6 months) may benefit from early false lumen exclusion or direct false lumen embolization therapy. Waiting until the aneurysm is of traditional size criteria is impractical as a larger false lumen size is conceptually more difficult to mitigate especially when there are branched vessels to consider. Finally, patients with type III entry flow are repaired effectively with secondary TEVAR/EVAR to cover the zones that continue to cause false lumen flow.

While retrograde aortic dissection was not as common in this subset of patients, it was proportionally, the complication that most frequently required secondary intervention. This complication is highly correlative to patients who have "involved" aorta at the proximal seal zone [5]. Intramural thrombus or gross dissection extending just proximal to the left subclavian artery is an example of anatomy predisposing to retrograde propagation in the setting of TEVAR. Patients with retrograde type A dissections necessitate prompt open aortic surgical repair.

Secondary interventions may provide a useful adjunct to endovascular repair of aortic dissections. The effect of secondary interventions on false lumen thrombosis has yet to be fully elucidated. However, survival analysis in one study showed a trend toward improved survival in patients who underwent secondary interventions [18]. The studies in this cohort all include false lumen thrombosis rates with regards to initial endovascular repair, but do not state what the false lumen thrombosis rate is after the secondary intervention. Furthermore, we are not provided other pertinent anatomical data such as entry flow locations and patterns of successful reintervention based on those locations. Primary entry tear coverage alone should be viewed as the first step of potentially many in TBAD management. From this review, we conclude that secondary interventions for failed TEVAR carry a substantial all-cause mortality but may be beneficial if combined with proper surveillance and medical management.

## References

1. Conrad M, Crawford R, Kwolek C, Brewster D, Brady T, et al (2009) Aortic remodeling after endovascular repair of acute complicated type B aortic dissection. *Journal of Vascular Surgery* 50: 510-517.
2. Nienaber C, Rousseau H, Eggebrecht H, Kische S, Fattori R, et al. (2009) Randomized comparison of strategies for type B aortic dissection: the INvestigation of STEnt Grafts in Aortic Dissection (INSTEAD) trial. *Circulation* 120: 2519-2528.
3. Dake M, Kato N, Mitchell R, Semba C, Razavi M, et al (1999) Endovascular stent-graft placement for the treatment of acute aortic dissection. *New England Journal of Medicine* 340: 1546-1552.
4. Nienaber C, Fattori R, Lund G, Dieckmann C, Wolf W, et al (1999) Nonsurgical reconstruction of thoracic aortic dissection by stent-graft placement. *New England Journal of Medicine*.
5. Lombardi J, Cambria R, Nienaber C, Chiesa R, Mossop P, et al. (2014) Aortic remodeling after endovascular treatment of complicated type B aortic dissection with the use of a composite device design: A Report from the Stable Trial. *Journal of Vascular Surgery* 59: 1544-1554.
6. Böckler D, Schumacher H, Ganten M, von Tengg-Kobligk H, Schwarzbach M, et al. (2006) Complications after endovascular repair of acute symptomatic and chronic expanding Stanford type B aortic dissections. *The Journal of Thoracic and Cardiovascular Surgery* 132: 361-368.
7. Chemelli-Steingruber I, Chemelli A, Strasak A, Hugi B, Hiemetzberger R, et al. (2010) Endovascular repair or medical treatment of acute type B aortic dissection? A comparison. *European Journal of Radiology* 73: 175-180
8. Feezor R, Martin T, Hess P, Beaver T, Klodell C, et al. (2009) Early outcomes after endovascular management of acute, complicated type B aortic dissection. *Journal of Vascular Surgery* 49: 561-567
9. Flecher E, Cluzel P, Bonnet N, Aubert S, Gaubert A, et al. (2008) Endovascular treatment of descending aortic dissection (type B): short- and medium-term results. *Archives of Cardiovascular Diseases* 101: 94-99.
10. Kang W, Greenberg R, Mastracci T, Eagleton M, Hernandez A, et al. (2011) Endovascular repair of complicated chronic distal aortic dissections: intermediate outcomes and complications. *The Journal of Thoracic and Cardiovascular Surgery* 142: 1074-1083.
11. Khoynzhad A, Donayre C, Omari B, Kopchok G, Walot I, et al. (2009) Midterm results of endovascular treatment of complicated acute type B aortic dissection. *The Journal of Thoracic and Cardiovascular Surgery* 138: 625-31.
12. Lambrechts D, Casselman F, Schroyers, De Geest R, D'Haenens P, et al. (2003) Endovascular Treatment of the Descending Thoracic Aorta. *European Journal of Vascular and Endovascular Surgery* 26: 437-444.
13. Lee M, Lee do Y, Kim M, Lee M, Won J, et al. (2013) Outcomes of endovascular management for complicated chronic type B aortic dissection: effect of the extent of stent graft coverage and anatomic properties of aortic dissection. *JVIR* 24: 1451-1460.
14. Oberhuber A, Winkle P, Schelzig H, Orend K, Muehling B, et al. (2011) Technical and clinical success after endovascular therapy for chronic type B aortic dissections. *Journal of Vascular Surgery* 54: 1303-1309.
15. Parsa C, Schroder J, Daneshmand M, McCann R, Hughes G, et al. (2010). Midterm results for endovascular repair of complicated acute and chronic type B aortic dissection. *The Annals of Thoracic Surgery* 89: 97-1042
16. Qin Y, Deng G, Li T, Jing R, Teng G, et al. (2012) Risk factors of incomplete thrombosis in the false lumen after endovascular treatment of extensive acute type B aortic dissection. *Journal of Vascular Surgery* 56: 1232-1238.
17. Rodriguez J, Olsen D, Lucas L, Wheatley G, Ramaiah V, et al. (2008) Aortic remodeling after endografting of thoracoabdominal aortic dissection. *Journal of Vascular Surgery* 47: 1188-1194.
18. Scali S, Feezor R, Chang C, Stone D, Hess P, et al. (2013) Efficacy of thoracic endovascular stent repair for chronic type B aortic dissection with aneurysmal degeneration. *Journal of Vascular Surgery* 58:10-17.
19. Shu C, He H, Li Q, Li M, Jiang, X, et al. (2011) Endovascular repair of complicated acute type-B aortic dissection with stentgraft: early and mid-term results. *European Journal of Vascular and Endovascular Surgery* 42: 448-453.
20. Szeto W, McGarvey M, Pochettino A, Moser G, Hoboken A, et al. (2008) Results of a new surgical paradigm: endovascular repair for acute complicated type B aortic dissection. *The Annals of Thoracic Surgery* 86: 87-94.
21. Lombardi J, Cambria R, Nienaber C, Chiesa R, Teebken O, et al. (2012) Prospective multicenter clinical trial (STABLE) on the endovascular treatment of complicated type B aortic dissection using a composite device design. *Journal of Vascular Surgery* 55: 629-640.
22. Eggebrecht H, Nienaber C, Neuhäuser M, Baumgart D, Kische S, et al. (2006) Endovascular stent-graft placement in aortic dissection: a meta-analysis. *European Heart Journal* 27: 489-498.