

Restoration of Primary Canines with Porcelain Laminate Veneers: A Clinical Report

Elaheh Beyabanaki, Marzieh Alikhasi

Dental Implant Research Center and Department of Prosthodontics, Tehran University of Medical Sciences, School of Dentistry, Tehran, Iran.

Abstract

This article describes treatment of a young adult patient with porcelain laminate veneers for restoring unaesthetic maxillary anterior teeth with two retained primary canines. The patient had experienced an approximately two-year orthodontic treatment and had received both fixed and removable retainers for the upper arch. The patient could not afford implant supported restorations for his missing premolar teeth and was not pleased by the appearance of his smile. Using porcelain laminate veneers is a proper treatment option that could be taken into consideration in these situations.

Key Words: Laminate veneer, Deciduous tooth, Bonding resin, Ceramic, Composite resin

Introduction

There are few options for conservative restoration of malformed, but intact anterior teeth. These options include composite resin and porcelain laminate veneers [1,2]. Direct composite resin restorations present some advantages including conservative tooth preparation, simplicity, being easily changeable and being cost-effective. Nevertheless, it may not be a proper choice for restoring teeth with extensive structure damage [3]. Furthermore, some problems may be encountered such as material discoloration, fracture, recurrent caries, marginal defects and loss of restoration [4-6].

Porcelain laminate veneers are indirect esthetic fixed prostheses that their popularity is mostly related to minimal tooth preparation and desirable characteristics. They offer superior properties over composite veneers in terms of strength, color stability, resistance to abrasion, surface smoothness, and low plaque retention [7-9]. Furthermore, compared to 2.9% annually failure rate of composite resin restorations [10], porcelain veneers show failure rates of 0% to 5% over 1 to 5 years [11].

Despite numerous articles on using porcelain laminate veneers for permanent teeth [12-16], there are few ones for primary teeth [17-23]. There are some adult patients with retained primary teeth who seek esthetic and functional dental treatments. According to Robinson and Chan [21], retention of primary teeth happens in approximately 16.6% of population. The reasons for retention of primary teeth during adult life are: local pathologic conditions, impaction, transmigration or congenitally absence of permanent teeth, and also microdontia of permanent dentition [24]. It has been shown that the prognosis of retained mandibular and maxillary primary canines, and second molars is better than the prognosis of incisors and first molars [25,26]. However, it should be mentioned that root resorption would eventually occur in primary teeth even in the absence of their successors [27]. Several reasons have been suggested for root resorption of primary and permanent teeth including trauma, infection, periodontal disease, root canal therapy and invasion of neoplasm [27,28]. In an animal study using mongrel dogs, it has been shown that protection

of primary teeth from occlusion forces as a form of trauma, would delay their root resorption process [27]. However, it has also been reported that adequate occlusion between a healthy retained primary tooth and its opposing tooth helps its survival for several years [29]. Unfortunately, there are no clinical predictors regarding the survival of retained primary teeth without successor [30].

Depending on primary tooth condition and treatment plan, some options have been suggested for treating retained primary teeth without their successors. The treatment options include retaining, retaining and modifying, extraction and space closure, or extraction and prosthetic replacement [21]. In this regard, some authors have suggested restoring primary teeth with resin-bonded porcelain restorations [17-23]. Primary and permanent teeth are different regarding their enamel composition and microstructure [31], which seems to affect the etching pattern and subsequently bond strength of adhesive systems used for bonded restorations. Studies have shown that retentive qualities of acid-etched primary tooth enamel are less than those of permanent tooth enamel which have been treated with the same etching procedure [32,33]. This different etching pattern is related to more pronounced aprismatic enamel layer covering the outer enamel surface in primary teeth compared to permanent teeth [32,34].

While some investigations have suggested poorer bond strengths of composite to primary enamel, it does not seem to be a problem in clinical situations [35]. Lenzi et al. have shown that the preliminary etching of enamel would enhance bonding quality of one-step self-etch adhesive bonding system in both primary and permanent teeth [36]. However, removing this prismless outer layer of enamel and also using prolonged etching times have been proven to help overcome bonding problem in primary teeth [32,33].

The purpose of this article is to present a case with retained primary canines treated with porcelain laminate veneers.

Clinical Report

An 18-year-old male with no remarkable medical history was referred for esthetic restoration of six maxillary anterior

teeth one week after finalization of active orthodontic treatment (*Figure 1*). The patient was willing to be treated with a fixed, yet economic prosthetic option. First and second maxillary premolars were missing bilaterally and patient had both primary and permanent canines (*Figures 2A and 2B*). The space between permanent canines and first molars was managed during orthodontic treatment (*Figure 3*), and was maintained by means of a removable retainer device. Based on clinical and radiographic examinations which indicated no periodontal problem and mobility of primary teeth, and also the patient demand, laminate veneer treatment was chosen as an alternative to their extraction.

Primary impressions of jaws were made using an irreversible hydrocolloid (Alginoplast®, Heraeus Kulzer GmbH & Co., Wehrheim, Germany) impression material. Using inter-occlusal base-plate wax (Pink Base Plate Wax, Henry Schein, NY) record and an arbitrary face bow record, diagnostic casts were mounted in a semi-adjustable articulator (Dentatus ARH, Stockholm, Sweden). After diagnostic wax-up of six maxillary anterior teeth, a transparent vacuum-formed matrix was made on a duplicated cast made of diagnostic wax-up. This matrix was used for trial mock-up with light-cured composite resin on the teeth intra-orally. This mock-up was useful for visualizing the final restoration status to both dentist and patient (*Figure 4A*). It also helped estimate

the amount of needed enamel preparation to reach to an approximate depth of 0.3 mm in cervical to 0.5 mm in incisal areas for optimal veneer thickness (*Figure 4B*) [15]. Also, in order to increase restoration resistant to incisal fractures, to distribute the occlusal loads over a wider surface area, and to achieve an aesthetic incisal part of the porcelain veneer, the chosen design for incisal preparation was incisal overlap design [15]. Also, in order to increase porcelain strength and incisal edge in the primary teeth, the preparation was extended to the lingual surface [20]. Polyvinyl siloxane impression material (Zhermack Elite HD + Regular Body, Kouigo, Italy) was used in a combination with the two-stage impression technique. After tooth preparation with a light chamfer finish line at the level of gingival margin using a round-end diamond bur in a high-speed hand-piece and retraction cord (#00, Ultradent), the final impression was made. At the end of the session, temporary veneers were made by using matrix and light-cured composite resin with no etchant or bonding agent.

The final laminate veneers were made of conventional sintered feldspathic porcelain (EX-3, Noritake Co., Tokyo, Japan) of Vita A2 shade according to Vita Lumin classic shade guide. After checking veneers fitness on the prepared teeth, veneers were tried on tooth by test paste of Choice II resin cement (BISCO, Canada Co.) to select the appropriate cement color. Tooth and porcelain veneers preparations were conducted according to the instruction provided by Choice II resin cement which is a total-etch, light-cured self-adhesive cement (*Figures 5A, 5B and 5C*). For preparing the enamel surface of the primary teeth, the same etching procedure, which is used for permanent teeth was performed twice (37% phosphoric acid gel for 60 seconds followed by 30 second rinsing). Finally occlusal adjustments were done in order to distribute light occlusal contacts on enamel portion of palatal surfaces of two central incisors in maximum inter-cuspal position and centric relation. Also, adjustments were made to limit protrusive contacts to two maxillary central incisors and laterosive contacts to central and lateral incisors (*Figure 6*). The panoramic radiograph was taken after finalization of

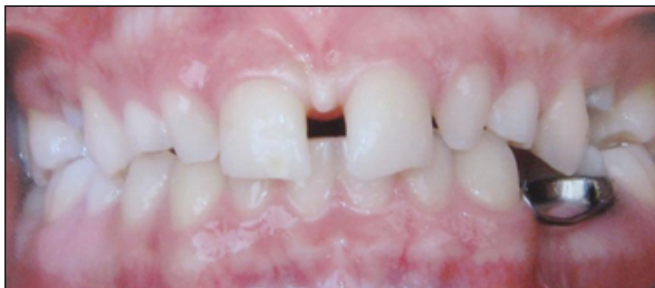

Figure 1. Frontal view of teeth before orthodontic treatment.

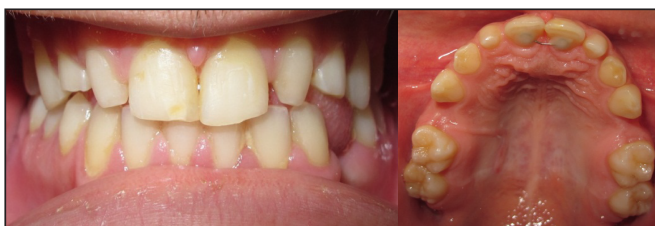

Figure 2. Frontal (A), and occlusal (B) maxillary arch intra-oral view.

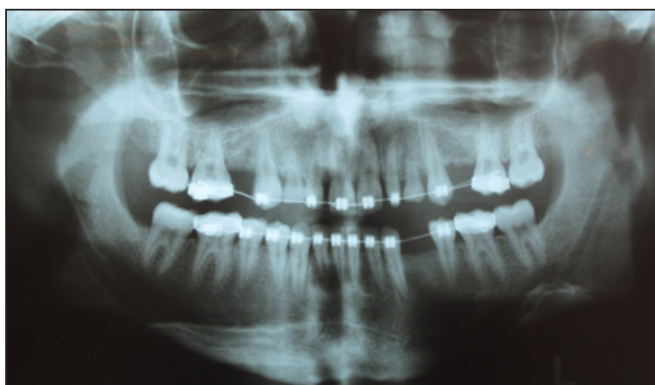


Figure 3. Radiographic view of teeth two months before laminate treatment.

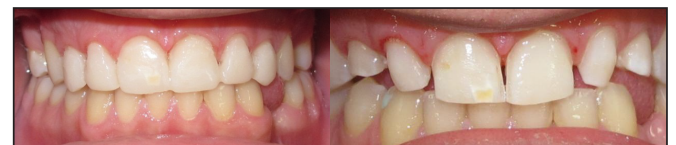

Figure 4. Intra-oral composite resin mock-up (A), and frontal view of teeth after preparation (B).

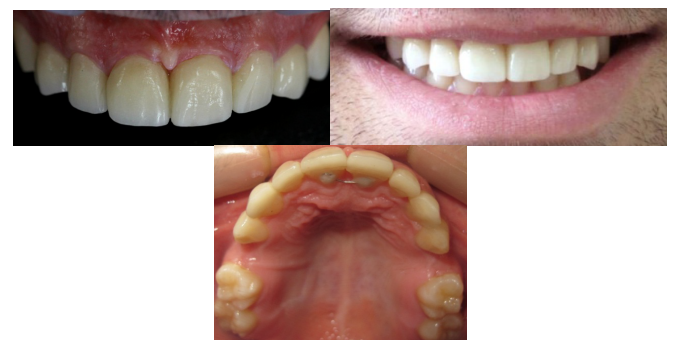

Figure 5. Final porcelain laminate veneers cemented with light-cured resin cement, frontal view (A), smile view (B), and occlusal view after laminate treatment (C).

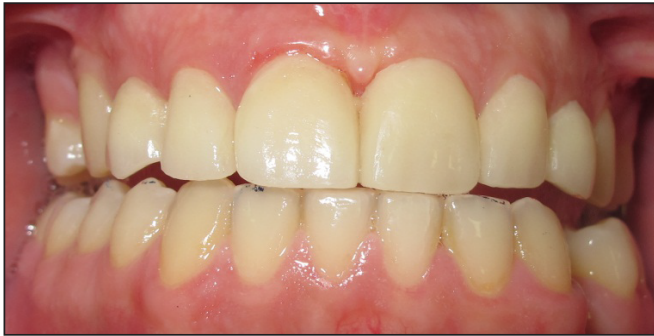

Figure 6. Protrusive contacts on two maxillary central incisors.

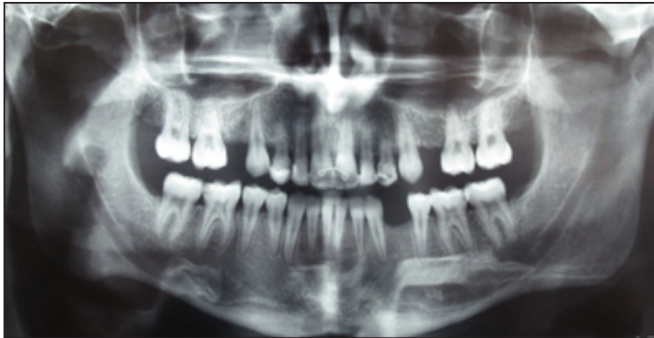


Figure 7. Panoramic view of teeth after finalization of laminate treatment.

the laminate treatment as the baseline radiographic view for detecting possible progression of root resorption of primary canines in the future follow-ups (Figure 7). One year and half later, patient did not show any failure signs and symptoms including porcelain chipping or tooth mobility due to root resorption of primary teeth at the follow-up (Figure 8A). The patient kept using his removable retainer during this time to maintain the space managed during orthodontic treatment, until he could afford implant-supported prostheses for these areas (Figure 8B).

Discussion

The purpose of reporting this case is to emphasize the possibility of involving retained primary teeth in a routine prosthetic treatment, provided they show acceptable radiographic and clinical prerequisites [16,17,20]. Achieving satisfactory long-term esthetic and functional results with laminate veneer restorations is guaranteed by an accurate treatment plan [1,2,15]. Diagnostic wax-up and mock-up procedures help visualize the approximate final results and also it helps to easily modify the final result before fabricating definitive restorations [16]. There is no evidence in the literature about survival and success rate of restored retained primary teeth.

References

1. De Araujo Júnior EM, Baratieri LN, Monteiro Júnior S, Vieira LC, De Andrada MA. Direct adhesive restoration of anterior teeth: Part 3. Procedural considerations. *Practical Procedures & Aesthetic Dentistry*. 2003; **15**: 433–437.
2. Baratieri LN, Araujo EM Jr, Monteiro S Jr. Composite restorations in anterior teeth: Fundamentals and possibilities. Chicago: *Quintessence International*; 2005; pp. 3–82.
3. Heymann HO, Hershey HG. Use of composite resin for

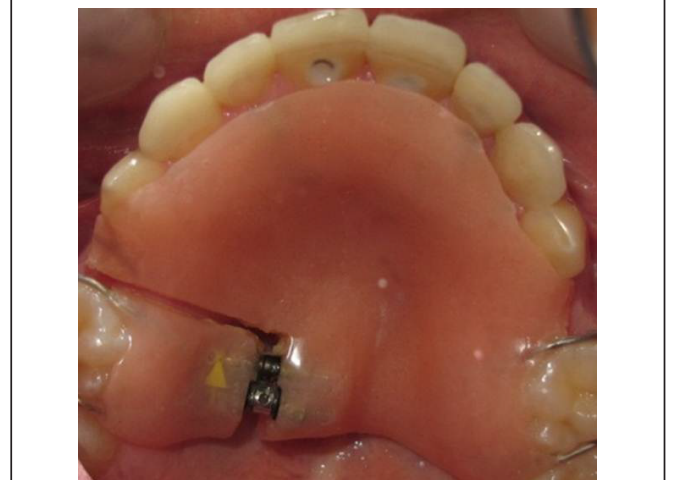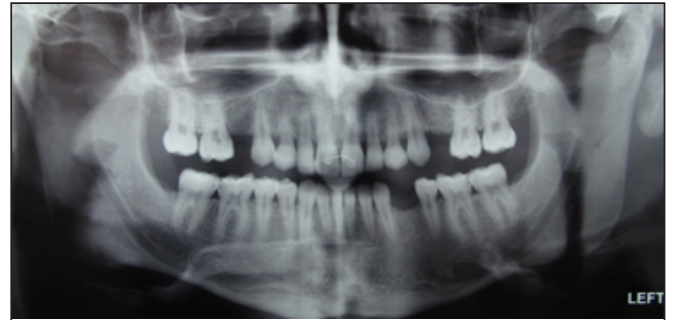


Figure 8. Panoramic view of teeth after 18 months (A), and removable retainer used by patient since after the termination of active orthodontic therapy (B).

However, several articles have shown that it is an acceptable treatment decision to use resin-bonded restorations for them [17-23], at least until patient can afford more expensive and complex treatments such as their extraction and implant replacement. Using resin-bonded porcelain restorations for primary teeth necessitates small modification in the tooth surface treatment procedure, which means grinding prismless outer enamel layer away and also applying longer etching time on the enamel [32,33].

Although not proven yet, patients should be informed of the odds of beginning of root resorption after engaging a reasonably acceptable and healthy primary tooth in a dental treatment. Therefore, laminate restoration for retained primary teeth might be better to be considered as a transitional treatment option.

Summary

This paper presented restoring anterior esthetic and function in a patient with two retained primary canines using porcelain laminate veneers. It is found that meticulous treatment planning, diagnostic and clinical procedures would guarantee an acceptable final result.

restorative and orthodontic correction of anterior interdental spacing. *Journal of Prosthetic Dentistry*. 1985; **53**: 766–771.

4. Tuncer D, Yazici A, Ozgünlaltay G, Dayangac B. Clinical evaluation of different adhesives used in the restoration of non-carious cervical lesions: 24-month results. *Australian Dental Journal*. 2013; **58**: 94–100.

5. Kopperud SE, Tveit AB, Gaarden T, Sandvik L, Espelid I. Longevity of posterior dental restorations and reasons for failure. *European Journal of Oral Sciences*. 2012; **120**: 539–548.

6. Garoushi S, Lassila L, Hatem M, Shembesh M, Baady L, et al. Influence of staining solutions and whitening procedures on discoloration of hybrid composite resins. *Acta Odontologica Scandinavica*. 2013; **71**: 144–150.
7. Walter RD, Raigrodski AJ. Critical appraisal: Clinical considerations for restoring mandibular incisors with porcelain laminate veneers. *Journal of Esthetic and Restorative Dentistry*. 2008; **20**: 276–281.
8. Guess PC, Stappert CF, Strub JR. Preliminary clinical results of a prospective study of IPS e.max Press- and Cerec ProCAD-partial coverage crowns. *Schweiz Monatsschr Zahnmed*. 2006; **116**: 493–500.
9. Seghi RR, Sorensen JA. Relative flexural strength of six new ceramic materials. *International Journal of Prosthodontics*. 1995; **8**: 239–246.
10. Signore A, Kaitsas V, Tonoli A, Angiero F, Silvestrini-Biavati A, et al. Sectional porcelain veneers for a maxillary midline diastema closure: A case report. *Quintessence International*. 1995; **44**: 201–206.
11. Peumans M, Van Meerbeek B, Lambrechts P, Vanherle G. Porcelain veneers: A review of the literature. *Journal of Dentistry*. 2007; **28**: 163–177.
12. Strassler HE. Minimally invasive porcelain veneers: indications for a conservative esthetic dentistry treatment modality. *General Dentistry*. 2007; **55**: 686–694.
13. Öztürk E, Bolay Ş, Hickel R, Ilie N. Shear bond strength of porcelain laminate veneers to enamel, dentine and enamel-dentine complex bonded with different adhesive luting systems. *Journal of Dentistry*. 2013; **41**: 97–105.
14. Matsumura H, Aida Y, Ishikawa Y, Tanoue N. Porcelain laminate veneer restorations bonded with a three-liquid silane bonding agent and a dual-activated luting composite. *Journal of Oral Sciences*. 2006; **48**: 261–266.
15. Beier US, Dhima M, Koka S, Salinas TJ, Dumfahrt H. Comparison of two different veneer preparation designs in vital teeth. *Quintessence International*. 2012; **43**: 835–839.
16. Magne P, Magne M. Use of additive wax up and direct intraoral mock-up for enamel preservation with porcelain laminate veneers. *European Journal of Esthetic Dentistry*. 2006; **1**: 10–19.
17. McConnell RJ, Boksman L, Jones G. Esthetic restoration of a primary canine in the adult dentition by means of an etched porcelain veneer. Report of a case. *Quintessence International*. 1987; **18**: 121–124.
18. Aron VO. Porcelain veneers for primary incisors: A case report. *Quintessence International*. 1995; **26**: 455–457.
19. Cavanaugh RR, Croll TP. Resin-bonded ceramic onlays for retained primary molars with infra occlusion. *Quintessence International*. 1994; **25**: 459–463.
20. Aristidis GA. Etched porcelain veneer restoration of a primary tooth: a clinical report. *Journal of Prosthetic Dentistry*. 2000; **83**: 504–507.
21. Robinson S, Chan MF. New teeth from old: Treatment options for retained primary teeth. *British Dental Journal*. 2009; **207**: 315–320.
22. Caine DR. The aesthetic restoration of ankylosed deciduous teeth utilizing porcelain laminates. Report of a case study. *New York State Dental Association*. 1987; **53**: 21–23.
23. Gulati AK, Welbury RR. The use of resin-bonded porcelain crowns for primary molars in infra-occlusion. *British Dental Journal*. 1998; **184**: 588–591.
24. Aktan AM, Kara I, Sener I, Bereket C, Celik S, et al. An evaluation of factors associated with persistent primary teeth. *European Journal of Orthodontics*. 2012; **34**: 208–212.
25. Haselden K, Hobkirk J A, Goodman J R, Jones S P, Hemmings KW. Root resorption in retained deciduous canine and molar teeth without permanent successors in patients with severe hypodontia. *International Journal of Paediatric Dentistry*. 2001; **11**: 171–178.
26. Stanley HR, Collett WK, Hazard JA. Retention of a maxillary primary canine: Fifty years above and beyond the call of duty. *ASDC Journal of Dentistry for Children*. 1996; **63**: 123–130.
27. Obersztyn A. Experimental investigation of factors causing resorption of deciduous teeth. *Journal of Dental Research*. 1963; **42**: 660–674.
28. Bakland LK. Root resorption. *Dental Clinics of North America*. 1992; **36**: 491–507.
29. Sletten DW, Smith BM, Southard KA, Casco JS, Southard TE. Retained deciduous mandibular molars in adults: A radiographic study of long-term changes. *American Journal of Orthodontics Dentofacial Orthopedics*. 2003; **124**: 625–630.
30. Ith-Hansen K, Kjaer I. Persistence of deciduous molars in subjects with agenesis of the second premolars. *European Journal of Orthodontics*. 2000; **22**: 239–243.
31. Hirayama A. Experimental analytical electron microscopic studies on the quantitative analysis of elemental concentrations in biological thin specimens and its application to dental science. *Shikwa Gakuho*. 1990; **90**: 1019–1036.
32. Sheykholeslam Z, Buonocore MG. Bonding of resins to phosphoric acid-etched enamel surfaces of permanent and deciduous teeth. *Journal of Dental Research*. 1972; **51**: 1572–1576.
33. Eidelman E. The structure of the enamel in primary teeth: practical applications in restorative techniques. *ASDC Journal of Dentistry for Children*. 1976; **43**: 172–176.
34. Gwinnett AJ. Human prismless enamel and its influence on sealant penetration. *Archives of Oral Biology*. 1973; **18**: 441–444.
35. Endo T, Yoshino S, Shinkai K, Ozoe R, Shimada M, et al. Shear bond strength differences of types of maxillary deciduous and permanent teeth used as anchor teeth. *Angle Orthodontics*. 2007; **77**: 537–541.
36. Lenzi TL, Guglielmi Cde A, Umakoshi CB, Raggio DP. One-step self-etch adhesive bonding to pre-etched primary and permanent enamel. *Journal of Dentistry for Children*. 2013; **80**: 57–61.