

Recurrences of Ameloblastoma in Bone Grafts: Report of Two Cases and Literature Review

Xin-chun Jian^{1, 2}, De-yu Liu¹, Rong Zhu¹, Chao Zhou², Xiao-shan Wu², Pu Xu¹, Ning Li², Li-meng Wu², Qun-hao Zhuo²

¹Department of Oral and Maxillofacial Surgery, Stomatological Center, Haikou Hospital, Central South University, Haikou 570208, Hainan, P.R. China. ²Department of Oral and Maxillofacial Surgery, Xiangya Hospital, Central South University, Changsha 410008, Hunan, P.R. China

Abstract

Two cases of recurrence of an ameloblastoma in autogenous iliac or rib bone graft about 16 years and 14 years after the initial operation for a mandibular ameloblastoma with evidence of soft or hard tissue invasion are presented. A review of the literature disclosed only 14 cases of recurrence of ameloblastoma in bone grafts. In the 2 cases presented, the initial operation was a hemimandibulectomy followed by autogenous iliac or rib bone graft. Sixteen years or fourteen years after the surgery, there was clinical and radiographic signs of recurrence. It was concluded that extensive resection including bone as well as adjacent soft tissues is critical because the recurrences seem to stem from the soft tissues, especially from the adjacent periosteum or bone.

Key Words: Ameloblastoma, Dentogenic tumor, Bone grafts, Recurrence

Introduction

Ameloblastomas are considered locally invasive odontogenic tumors with a strong tendency to recur [1]. Recurrence of ameloblastomas is related to inadequate surgical treatment. A wide resection is the treatment of choice assuring recovery without recurrence in most of the cases [2,3]. However, recurrences have been reported in patients treated with radical excision. Recurrences of ameloblastomas involving bone grafts are rare. To our knowledge, fourteen cases have been reported [4-14]. Two cases of mandibular ameloblastoma recurring 16 years and 14 years following resection and reconstruction by autogenous iliac and autogenous rib are presented in this report.

Case Report

Case no 1

The patient 1, a 33-year-old male came to the Department of Oral and Maxillofacial Surgery of Xiangya Hospital of Central South University for treating his swelling and pain of right facial region because of swelling of the right facial region for 2 weeks. In his medical history, sixteen years previously the patient had an ameloblastoma resected from his right mandible and resected right mandible was reconstructed with autogenous iliac graft under general anesthesia by an extraoral approach (*Figure 1 and 2*). His postoperative course was without complications, and he was discharged on the postoperative twelfth day. Histopathology (haematoxylin and eosin (HE) stain 200) revealed extensive squamous metaplasia associated with keratin formation in the central portions of the epithelial islands of a follicular ameloblastoma (*Figure 3*).

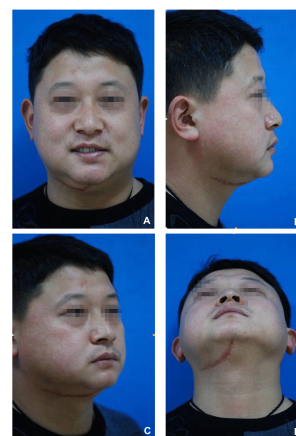

Figure 1. Clinical findings of the case 1, 16 years after initial surgery. Frontal view; B. Lateral view; C.3/4 view; D. Mental view.

The patient was not seen until April 2014. The patient felt swelling of the right facial region for 2 weeks before he sawed dentist at this time. Clinical examination revealed that his face was asymptomatic, the right face was larger than the left face. Patient was not wearing a dental prosthesis and her occlusion was normal. Patient's mouth opening was 4.5 cm, with a slight deflection to the right side. The intraoral examination revealed that swelling extended from the right buccal mucosa of the cheek to the anterior region of mandibular ramus of the same side. The mass was partially covered by an intact mucosa, which had ulcerated due to the bite of the mucosa. The examination of panoramic radiograph showed a newly right mandibular tumor recurrence, a multilocular radiolucent area was seen at the distal edge of the graft, near the original mandibular stump (*Figure 2*). Cone beam computed tomography (CBCT) radiograph showed recurrence of the lesion destroying the ramus, angle and body of the right mandible (*Figure 2*). Under the general anesthesia, an involved segmental mandibulectomy and immediate free

fibula osseous myocutaneous flap reconstruction were performed through a cervical incision and followed by a careful dissection from the adjacent structures (*Figure 3*). The histopathological examination of the surgical specimen (HE stain 100) shows a combination of follicular and plexiform microscopic patterns with cystic degeneration at both the central portion of the follicle pattern and the stroma of the plexiform pattern ameloblastoma in bone graft (*Figure 3F*). The patient returned in February 2015 presenting a good facial balance and occlusion, his mouth opening was 4cm.

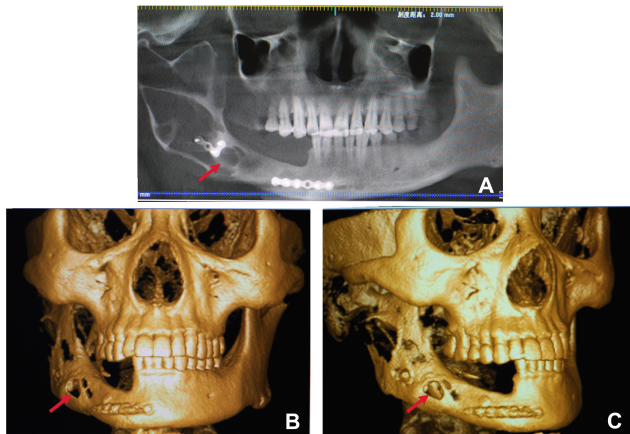


Figure 2. CBCT radiograph showing recurrence of the lesion destroying the ramus angle and body of the right mandible (arrows).

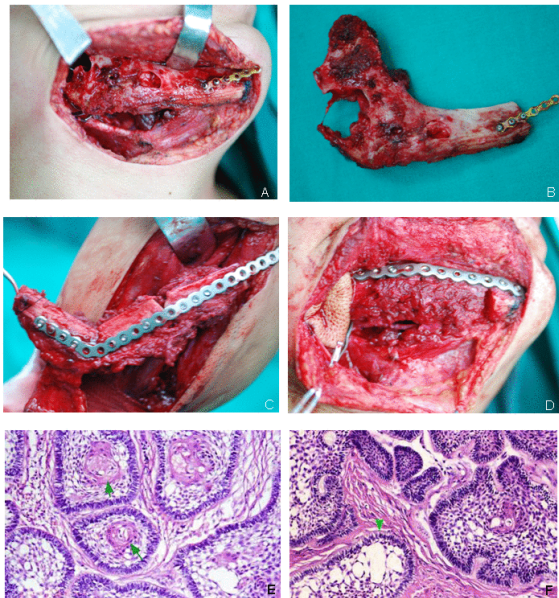


Figure 3. Intraoperative views, specimen of recurrences time and histopathological features of initial and recurrences time of case 1.

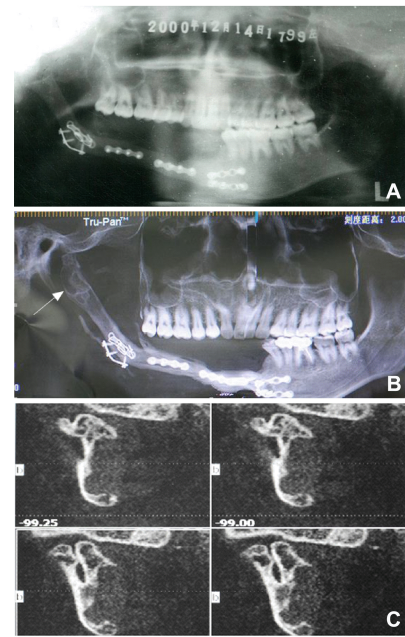


Figure 4. CBCT radiograph showing recurrence of the lesion destroying the ramus of the right mandible (arrows).

Case no 2

The patient 2, a 15-year-old male operated on in May 2000 for an extended multilocular lesion of the right mandibular ramus, angle and body following a biopsy that revealed ameloblastoma. The segmental mandibulectomy was performed and was replaced with an autogenous rib graft. The patient was followed-up for 10 years with no evidence of recurrence, but he was lost to follow-up 2 year ago. The patient came to the Department of Oral and Maxillofacial Surgery of Xiangya Hospital of Central South University, Changsha, Hunan Province for examining his operated the right face by CBCT examination, which revealed a multilocular radiolucency at the top site of the graft (*Figure 4*). The patient refused further treatment and was continuously follow-up.

Discussion

Ameloblastomas are considered locally invasive odontogenic tumors with a strong tendency to recur [1], this recurrence is related to inadequate surgical treatment such as curettage, enucleation and incomplete removal of the intraosseous ameloblastomas. So, wide resection is the treatment of choice assuring recovery without recurrence in the cases, however, recurrences have been reported [2,3] in patients treated with radical surgery [12]. But, cases of recurrence of ameloblastomas involving autogenous bone grafts are rare. According to data in the literature, fourteen cases have been reported (*Table 1*). The shortest time of the recurrence of the ameloblastoma involving autogenous bone grafts is 3 years, the longest time of the recurrence of the ameloblastoma involving autogenous bone grafts is 36 years, an average time is 15.5 years, why recurrent period is so long? We consider when the ameloblastoma of the jaw was resected, it is probable that a few tumor cells were left in the stump of

resected jaw, after the bone graft was performed, the tumor cells which were left in the stump of resected jaw extended slowly into the transplanted new bone and led to the recurrence of the ameloblastoma of the patient 1. In our case 2, the condyle, ramus, and part of the mandibular body were removed in the first operation, recurrence from the proximal stump was unlikely. It is another probable that recurrence was

due to a seeding of tumor cells into the adjacent periosteum and mucosa, after the ameloblastoma was resected, when the new bone (such as rib bone or iliac bone) was transplanted, these adjacent periosteum and mucosa had not been removed, which grew slowly over many years and destroyed the cortical plate of transplanted new bone and caused the recurrence of ameloblastoma.

Table 1. Contribution of patients with ameloblastomas invading bone grafts reported in the literature.

Author (s)	Sex	Age (y)	Location	Recurrent time in bone graft	Secondary surgery
Grafft et al. [4]	F	15	Mandibular left molar region	13 yrs after iliac graft	new graft
Carvalho et al. [5]	F	52	Left mandible	20 yrs after iliac graft	Mandibulectomy
Dolan et al. [6]	M	63	Anterior mandible	13 yrs after rib graft	New iliac graft
Marinelli et al. [7]	M	no	Mandibular let molar region	12 yrs after iliac graft	Curettage
Stea [8]	F	39	Mandibular left body	7 yrs after iliac graft	Curettage
Zacharides [9]	M	25	Mandibular body and anterior region	36 yrs after rib graft	Missed follow-up
	M	62	Mandibular left ramus	3 yrs after rib graft	Missed follow-up
	M	48	Left mandible	4 yrs after iliac graft	Curettage
	F	22	Right mandibular body and ramus	7 years after autogenous graft	Resection
Vasan [10]	M	42	Right mandibular body	28 yrs after iliac graft	Eunucleation
Bianchi et al. [11]	F	19	Right mandibular body	27 yrs after iliac graft	Eunucleation
Martins et al. [12]	M	17	Right mandibular body	16 yrs after iliac graft	Iliac graft
Su et al. [13]	M	55	Left mandibular body	16 yrs after iliac graft	Free fibula graft
Choi et al. [14]	M	52	Right mandibular body	20 yrs after iliac graft	Resection

Radical and aggressive surgery is the preferred option for recurrent ameloblastoma management [15-17] This method supports that the mandibular resection should be at least 1-2 cm beyond the radiological limit to ensure that all microlesions are removed [16]

Mandibular reconstruction is necessary following tumor resection resulting in severe defects of mandibular arch continuity and sacrifice of teeth. The reconstruction of resected bone includes the use of non-vascularized bone grafts or use of a fibula free flap together with restoration of lost teeth by means of dental implants and implant-supported prostheses [18-20].

Conclusion

Two recurrent cases in transplanted iliac bone and rib bone were reported, the recurrence of the patient 1 of two cases came from the proximal stump of the mandible, the recurrence of the patient 2 came from the overlying soft tissues of the resected ameloblastoma. Our case report reinforces the need for a long-term follow-up. When the tumor is recurrent, according to the location and extent of recurrence of the tumor, either marginal or segmental mandibulectomy may be performed. Immediate reconstruction of the bone defect with free bone grafts, placement of dental implants and rehabilitation with implant-supported prostheses in a second

stage can improve jaw function and facial harmony of the patient.

Role of Funding Source

No funding was needed.

Conflict of Interest Statement

The authors declare no conflict of interest. A written photo release permission form has been signed by the patient.

Acknowledgements

This work was supported by the National Natural Sciences Foundation of China (Grant No.81260166, 81041052)

References

1. Kramer IRH, Pindborg JJ, Shear M. Histological typing of odontogenic tumors. Berlin: Springer; 1992; p.11-3.
2. Daramola JO, Ajagbe HA, Oluwasanmi JO. Recurrent ameloblastoma of the jaws. A review of 22 cases. *Plastic and Reconstructive Surgery*. 1980; **65**: 577-9.
3. Hatada K, Noma H, Katakura A, et al. Clinicostatistical study of ameloblastoma treatment. *The Bulletin of Tokyo Dental College*. 2001; **42**: 87-95.
4. Grafft ML, Sazima HJ, Parker FP, Rappaport I. Ameloblastoma recurring in previously placed iliac crest autograft: report of case. *Journal of Oral Surgery*. 1970; **28**: 285-291.

5. Carvalho FS, Valadad GA, Cespedes CE. Ameloblastoma (recurrence after 21 months)(J). *Revista da Associação Médica Minas Gerais*. 1976; **27**: 28-30.
6. Dolan EA, Angelillo JC, Georgiade NG. Recurrent ameloblastoma in autogenous rib graft. Report of case (J). *Oral Surgery, Oral Medicine, Oral Pathology, Oral Radiology and Endodontics*. 1981; **51**: 357-360.
7. Marinelli M, Badia D, Vallogini P, et al. Ameloblastoma recidivo in trapianto autogeno di cresta iliaca. In: Giardino G, editor. *Maxillofacial surgery*. Bologna: Monduzzi(M); 1982: p.94-96.
8. Marinelli M, Recurrence of an ameloblastoma in an autogenous iliac bone graft (J). *Journal of Oral and Maxillofacial Surgery*. 1985; **43**: 374-377.
9. Zacharides N. Recurrences of ameloblastoma in bone grafts (J). *International Journal of Oral and Maxillofacial Surgery*. 1988; **17**: 316-318.
10. Vasan NT: Recurrent ameloblastoma in an autogenous bone Graft after 28 years: a case report (J). *The New Zealand Dental Journal*. 1995; **91**: 12-13.
11. Bianchi SD, Tarello F, Polastri F, Valente G. Ameloblastoma of the mandible involving an autogenous bone graft. *Journal of Oral and Maxillofacial Surgery*. 1998; **56**: 1187-1191.
12. Martins W, Favaro DM. Recurrence of an ameloblastoma in an autogenous iliac bone graft. *Oral Surgery, Oral Medicine, Oral Pathology, Oral Radiology, and Endodontology*. 2004; **98**: 657-659.
13. Su T, Liu B, Chen XM, et al. Recurrence of ameloblastoma involving iliac bone graft after 16 years (Case report) (J). *Oral Oncology EXTRA*. 2006; **42**: 150-152.
14. Choi YS, Asaumi J, Yanagi Y, et al. A case of recurrent ameloblastoma developing in an autogenous iliac bone graft 20 years after the initial treatment. *Dentomaxillofacial Radiology*. 2006; **35**: 43-46.
15. Fregnani ER, da Cruz Perez DE, de Almeida OP, et al. Clinicopathological study and treatment outcomes of 121 cases of ameloblastomas. *International Journal of Oral and Maxillofacial Surgery*. 2010; **39**: 145-149.
16. Becelli R, Morello R, Renzi G, Matarazzo G, Dominici C. Treatment of recurrent mandibular ameloblastoma with segmental resection and revascularized fibula free flap. *The Journal of Craniofacial Surgery*. 2011; **22**: 1163-1165.
17. Hertog D, Schulten EA, Leemans CR, Winters HA, Van der Waal I. Management of recurrent ameloblastoma of the jaws; a 40-year single institution experience. *Oral Oncology*. 2011; **47**: 145-146.
18. Javier Mareque Bueno, Santiago Mareque Bueno, Jorge Pamiás Romero, M Socorro Bescos Atín, Pedro Huguet Redecilla, Guillermo Raspall Martín. Mandibular ameloblastoma. Reconstruction with iliac crest graft and implants. *Medicina Oral, Patología Oral y Cirugía Bucal*. 2007; **12**: E73-E75.
19. Nakamura N, Higuchi Y, Mitsuyasu T, Sandra F, Ohishi M. Comparison of long-term results between different approaches to ameloblastoma. *Oral Surgery, Oral Medicine, Oral Pathology, Oral Radiology, and Endodontics*. 2002; **93**: 13-20.
20. Chiapasco M, Colletti G, Romeo E, Zaniboni M, Brusati R. Long-term results of mandibular reconstruction with autogenous bone grafts and oral implants after tumor resection. *Clinical Oral Implants Research*. 2008; **19**: 1074-1080.