

Rate of Success of Amalgam in Retrograde Apicectomy: Toxicity and Health Issue

Liqa Shallal Farhan

Maxillofacial Surgery, College Of Dentistry, University of Anbar, Iraq

Abstract

Aim: The high incidence of periapical pathosis among population and consequently health and economic complications making apicectomy to remain the best choice to restore these teeth. The advent of a variety of material to seal peri-apically involved teeth with varying chemical properties making the apicectomy a successful surgical procedure to restore the teeth. **Objectives:** To estimate the success rate of amalgam in retrograde apicectomy by comparing it with success rate of other retrograde filling materials. **Materials and method:** Prospective study involved (665) patients, male (320) and female (345). Age (10-45) years. The study was done in department of maxillofacial surgery, Dentistry College/University Of Anbar between (Sept 2000-2018). These patients come for treatment of peri-apically involved teeth and failed endodontic treatment. Full medical and dental histories were taken from these patients before surgery and informed consent. The patients received retrograde apicectomy using the following materials: Amalgam, Gutta percha and MTA (Mineral Trioxide Aggregate). The patients were followed clinically and radiographically 1, 6 and 12 month after surgery. Clinical examination of treated area for evidence of persistence pain, tenderness, postoperative swelling, pus discharge and mobility of teeth. Radiographically persistency of enlarged peri-apical radiolucency. The success rate of each material is determined and compared. **Results:** The statistical analysis indicate that the higher success rate was in MTA (94.76%) in comparison with success rate of Gutta percha (92.79%) and the lower success rate was in Amalgam was (88.58%). The mean difference is significant at 0.06 level ($P < 0.06$). **Conclusion:** Retrograde apicectomy using different type of retrograde filling materials is highly successful surgical procedure for treatment of teeth with peri-apical lesions and failed conventional endodontic treatment.

Key Words: Amalgam, Retrograde apicectomy, Retrograde filling materials, Gutta percha, MTA, Health toxicity

Introduction

Retrograde apicectomy remain a standardized surgical treatment to save hopeless teeth with failed conventional root canal filling. In these teeth sealing of root apex is a primary goal [1]. Most of failure in endodontic treatment results from escape of irritants from pathological canals. When this treatment became unsuccessful surgical endodontic treatment is indicated to seal the apex [2]. The complex anatomy of root canals make adequate canal cleaning impossible or due to existing physical impediments which indicate surgical endodontic treatment in these cases [3]. This procedure involves cutting of apical area of peri-apically involved tooth and removing of chronically inflamed tissue, then preparation and filling of a cavity on the cut root apex [4]. Because the cut root end opens up numerous canals between the root canal and peri-apical tissue which permit intracanal infection to cause persistent inflammation. Numerous root end filling materials has been introduced recently with varying chemical property [5]. The ideal root end filling must manipulated easily, radiopaque, stable, nonresorbable, not carcinogenic, dimensionally stable and not influenced by moisture. It should adequately seal the root canal, non-toxic and well tolerated by the periapical tissues and then allow good healing. Despite of that no ideal root end material exist [6]. Gutta percha, amalgam, MTA, SEBA, and others like ZnO cement, glassionomer and gold foil pellets are among these retrograde filling materials used to seal apex in apicectomy. Studies are still undergoing to find an ideal root end filling material [7]. Considering of toxicity and tissue reaction to these materials are important. Dental amalgam is most commonly used material because of good operability and ability to seal the cut root apex in apicectomy. It is an excellent root end filling

despite of microleakage and expansion on setting. It is little expanded after setting improves its sealing ability [8]. The biocompatibility of Amalgam as a retrograde filling is still a challenge to dentist. Toxicity and corrosion remain among disadvantages of ordinary dental amalgam [9]. Nowadays the introductions of Zinc free –high copper spherical amalgam overcome the limitations in use of conventional amalgam in apicectomy [10]. Among other materials used as retrograde filling in apicectomy are: zinc oxide eugenol, gutta percha, SEBA, composite resin and gold foil. Super EBA is reinforced zinc oxide cement (32% eugenol liquid and 68% ethoxy benzoic acid). Studies on using zinc oxide eugenol as root end filling material has been failed but reinforced cement made up from eugenol and EBA make it suitable [11]. And the introduction of new root end filling material like MTA. It has been studied by Torabinejad et al. [12] using animals and laboratory studies. It is a hydrophilic powder composed from tricalcium phosphate, tricalcium silicate, tricalcium aluminate and silicate oxide to which bismuth is added to give radiopacity. After mixing MTA powder form colloid that set then hardens. This material has good sealability and cementum and osseous sign of repair and regeneration seeing in material surface that seal cut root end and open dentinal tubules. MTA has anti-bacterial properties against *E.faecalis*, *S.aureus* and *P.aeruginosa* as proved by many experimental studies [13]. Gutta percha is a widely used core material. It is trans-isomer existing in alpha and beta polycrystalline structure. It is composed from 20% gutta percha as matrix, 60% zinc oxide as filler for radiopacity, 11% metal has been added, 3% wax as plasticizer. The poor sealability of gutta percha is improved when sealer is used during obturation of the canal [14]. Amalgam is the most extensively historically used material. It is readily available, easily manipulated,

Corresponding author: Liqa Shallal Farhan, Maxillofacial Surgery, College Of Dentistry, University of Anbar, Iraq, Tel: 07817600025; E-mail: liqa.shallal@gmail.com

bacteriostatic, strong and durable, not soluble in the biological fluid with good marginal and sealing ability when placed in the prepared cavity. The formations of corrosion by products minimize micro leakage which may be responsible to its failure as ideal retro filling material [15]. It may induce moderate to severe inflammatory response and amalgam tattooing when spilled amalgam particles corroded during root end filling. High copper zinc free amalgam is the most preferable material over conventional amalgam (0.5% zinc) which is toxic due to the presence of unreacted mercury [16]. Amalgam is an alloy composed from copper, silver, zinc, tin with Mercury. The unreacted silver-tin particles called gamma phase which attached to mercury and results in matrix of gamma 1 (Ag_2Hg_3) and gamma 2 phases (Sn 7-8Hg). The last is responsible for easy fracture and failure of amalgam filling [17]. Tin added to amalgam composition to replace the tin-mercury (gamma 2 phase) to form copper-tin ($Cu_5 Sn_5$) which added strength to amalgam restoration and less corrosion possibility than the former phase. Amalgam nowadays are produced with 45% by weight (premixed) mercury to be safe, not contaminate and not fallen before mixed [18]. It is used when esthetic is not in concern i.e.; poor oral hygiene, cast metal and metal ceramic crown and in area with high strength. But concern about its toxicity should be considered [19]. Human is exposed to environment mercury and present in blood and urine. When amalgam restoration is used the concentration increased if reaction is not complete and become out of healthy standard [20]. Studies proved that in spite of amalgam release mercury when placed in mouth, but there is no proved evidence of any health risk [21].

Materials and Methods

Materials

M-110 high strength amalgam (Non gamma alloy, regular 45%Ag, 25%Cu, No Zinc, No Gamma 2 phase) Brazil, Gutta percha points (Gutta Percha, Zinc oxide, Barium Sulphate, Coloring agent) Germany, Mineral Trioxide Aggregate (MTA +) Material for rebuilding and filling of root canals, Poland.

Sample

Prospective study involved (665) patients, male (320) and female (345). Age (10-45) years. The study was done in department of maxillofacial surgery, Dentistry College/ University of Anbar between (Sep 2000-2018). These patients seeking treatment of their teeth involved by peri-apical lesion and failed endodontic treatment with apicectomy. Full medical and dental histories were taken from these patients before surgery i.e. cardiovascular diseases, diabetes etc. and full laboratory investigation related to HBsAg, HCV, HIV, Fasting Blood sugar (FBS) and blood clotting time. The patients were under go full radiographical examination before surgery using (OPG) Orthopantomograph and peri-apical X-ray to measure the size of peri-apical lesion and number of involved teeth and location of adjacent vital structures; Maxillary sinus, nasal cavity and inferior dental canal.

Method

236 patients from the sample with peri-apically involved teeth (size of lesions > 6.5mm) were treated with apicectomy. Local

anesthesia was used (2% Xylocaine with 80,000 adrenalin) to anesthetized the teeth. Three sided full thickness flap was made using scalpel. The surgical flap was elevated using Haworth periosteal elevator. The bone overlying the peri-apical lesion was removed using straight surgical hand piece and large size surgical burs with copious irrigation by normal saline. The peri-apical lesion is removed completely using surgical curette. The area was irrigated with normal saline and examined for any remnant of granulation tissue. The apical third of the apically involved teeth (4 mm) were cut using fissure surgical bur. Access opening were made, thorough instrumentation were made for the canals using endodontic reamers/or files. The canals were cleaned and irrigated with normal saline and dried using paper points. The root canal sealer was applied and the canals were obturated using suitable size gutta perch point using orthograde apicectomy technique. The apex of gutta percha point must be extended through the cut apex. Using hot ash the extended gutta perch point from the access opening was cut and condensed. Then extended gutta percha point through the cut apex was cut and the apex sealed. The bony cavity and root end was smoothed using large size surgical burs. Then the cavity is irrigated and inspected for any remnant of granulation tissue and filling material. The surgical flap was replaced and sutured using 3/0 black silk suture. The other 219 patients were treated with retrograde amalgam filling. Local anesthesia was used (2% Xylocaine with 80,000 adrenalin) to anesthetized the teeth. Three sided full thickness flap was made using scalpel. The surgical flap was elevated using Haworth periosteal elevator. The bone overlying the peri-apical lesion was removed using straight surgical hand piece and large size surgical burs with copious irrigation by normal saline. The peri-apical lesion was removed completely using surgical curette. The area was irrigated with normal saline and examined for any remnant of granulation tissue. The apical third of the peri-apically involved teeth were cut using fissure surgical bur using sharp bevel, facing facially to facilitate visualization of the cut apical area. Class I cavity of 3 mm depth is prepared using small size round bur with angle hand piece or ultrasonic instruments. The bony cavity was packed with gauze or cotton pellets. The prepared cavity must be inspected to ensure that it is dry and clean then the cavity was filled using M-110 high strength amalgam by the use of small size amalgam carrier and condenser. The bony cavity irrigated with normal saline and inspected to remove remaining amalgam particles. The surgical flap was replaced and suturing using 3/0 black silk suture. Other 210 patients from the sample with failed root canal treatment received retrograde sealing of apex with MTA (Mineral trioxide Aggregate). The surgery is similar to the above procedure except that after resection of the apex we use MTA + to seal the cut apical area of canal. Class I cavity of 3 mm depth was prepared using contra-angle hand piece and small size round bur or ultrasonic tips. The material was mixed and inserted in to the prepared cavity using amalgam carrier and wait until setting. Analgesics and antibiotics were prescribed in post-surgical period by paracetamol and Ampicillin (500 mg × 4 per day/1 week). The patients were instructed to come after one week for suture removal. The surgical areas were examined clinically for evidence of postoperative swelling and pain. The patients were evaluated periodically clinically and radiographically 1,6 and 12 month

postoperatively regarding radiographical healing of bone apically and clinically for pain, tenderness and swelling. The success rate of each material is determined and compared.

Statistical analysis

The statistical analysis was performed using the IBM SPSS statistics, Version 21 software shown in *Table 1*.

The statistical results in *Table 2* and *Figure 1* indicate that the higher success rate in MTA was (94.76%), the success rate for Gutta percha was (92.79%), while the lower success rate was for amalgam was (88.58%). *Table 2* Retrofilling* Treat cross tabulation analysis and *Table 3* Chi-square test analysis indicate that mean difference is significant at 0.06 level (P<0.06).

Table 1. No. of cases for each retro filling materials.

Treat	N
Amalgam	219
Gutta Percha	236
MTA	210
Total	665

Table 2. Show retro filling*treat cross-tabulation analysis.

Retrofilling	Result		Total	Percent
	Failed	Successful		
Amalgam	25	194	219	88.58
Gutta Percha	17	219	236	92.79
MTA	11	199	210	94.76
Total	53	612	665	

Table 3. Chi-Square Tests Analysis shows statistical significance in mean of success rate of different retro filling materials.

	Value	df	Asymp. Sig. (2-sided)
Pearson Chi-Square	5.871 ^a	2	0.053
Likelihood Ratio	5.763	2	0.056
N of Valid Cases	665		

a. 0 cells (0. 0%) have expected count less than 5. The minimum expected count is 16.74.

The statistical results in *Table 4* shows Sex*treat cross-tabulation analysis and *Table 5* Chi-square test analysis indicate that there is no effect of sex in success rate of different retro filling materials(P>0.06).

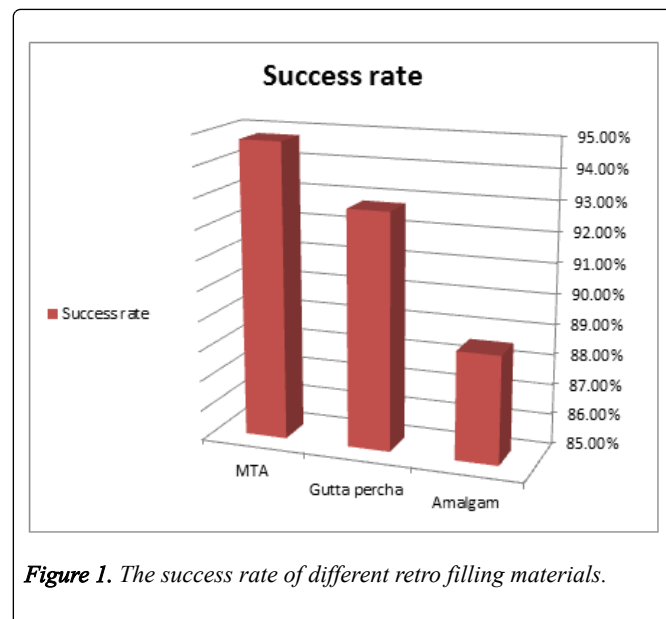


Figure 1. The success rate of different retro filling materials.

Table 4. Show sex *treat cross-tabulation analysis.

		Treat			Total
		1	2	3	
sex	female	91	103	96	290
	male	128	133	114	375
Total		219	236	210	665

Table 5. Chi-Square tests analysis shows statistical significance in mean of sex of different retro filling materials.

	Value	df	Asymp. Sig. (2-sided)
Pearson Chi-Square	0.755a	2	0.685
Likelihood Ratio	0.755	2	0.685
N of Valid Cases	665		

a. 0 cells (0. 0%) have expected count less than 5. The minimum expected count is 91.58.

The statistical results in *Table 6* showing Age*treat cross-tabulation Analysis and *Table 7*, Chi-Square Test Analysis indicate that there is no effect of age in success rate of different retro filling materials (P>0.06).

Table 6. Show Age*treat cross-tabulation analysis.

		Treat			Total
		Amalgam	Gutta percha	MTA	
Age	10	1	3	4	8
	13	5	12	13	30
	14	0	7	2	9
	15	0	1	2	3
	16	6	6	9	21
	18	3	2	1	6

19	5	4	2	11
20	40	41	37	118
21	0	0	1	1
22	41	34	22	97
23	8	14	14	36
24	28	30	20	78
25	19	27	32	78
26	33	32	32	97
27	2	1	2	5
28	3	3	3	9
30	0	0	1	1
31	0	0	1	1
32	0	2	0	2
34	7	5	5	17
35	6	5	2	13
36	6	3	2	11
37	6	3	2	11
38	0	1	1	2
Total	219	236	210	665

Table 7. Chi-square tests analysis of the effect of age category in success rate of different retro filling materials.

	Value	df	Asymp. Sig. (2-sided)
Pearson Chi-Square	50.411a	46	0.303
Likelihood Ratio	55.237	46	0.165
Linear-by-Linear Association	5.701	1	0.017
N of Valid Cases	665		

a. 45 cells (62.5%) have expected count less than 5. The minimum expected count is .32.

Discussion

Retrograde apicectomy of teeth with retrograde filling of root canals is high successful surgical procedure for restoration of teeth when filling of root canals by conventional approach has been failed. Its aims at sealing of cut root apex with retrograde filling materials, inspite of wide varieties of material available to seal the apex but the ideal one is still not available. The ideal properties of root end filling material are biocompatibility, bacteriostatic, dimensionally stable (not affected by fluid and moisture), nontoxic, not corrosive to irritate the tissue, high radiopacity and healing capacity to induced regeneration of bone, cementum and surrounding periodontal tissues [22,23]. The present study was done to determine the success rate of amalgam as retrograde filling in apicectomy and to compare it with success rate of other retrograde filling materials like gutta percha and mineral trioxide aggregate (MTA). The results is consistent with results of other studies conducted by Saxena et al. [24] and Bansode et al. [25] who indicate that in spite of the fact that

amalgam in the past is the material of choice because it is easily to handle and manipulate, radiopaque to be easily seen in x-ray and inexpensive but concern about peri-apical tissue reaction, corrosivity, sensitivity to fluid and moisture, poor sealability, leakage and toxicity make some healthy issue about its use today. Statistical analysis of present study in *Table 2* and *Figure 1* indicate that the higher success rate was in MTA was (94.76%), the success rate of gutta percha filling material was (92.79%), while the lower success rate was for amalgam was (88.58%). The mean difference is significant at 0.06 level ($P < 0.06$) [25]. The low rate of success for amalgam filling is due to toxicity from the released zinc elements, corrosion and poor marginal seal due to contraction of material after setting, poor healing of tissue peri-apically and irritant to the surrounding tissue due to corrosion by product when material in contact with moisture and tissue fluid by Singh et al. [26]. The results of present study indicate lower success rate of gutta percha (92.79%) in comparison with MTA (94.76%) because it was indicated that Gutta percha filling is porous material allows absorption of fluid from surrounding tissue, the material then expanded at first then undergo contraction [27]. Histological studies by Seema et al. [28] about bone healing when using gutta percha filling show feature of absence of bone healing and extensive inflammation. Resorbition and poor sealability of material when used as core material alone allow continuous entrance of tissue fluid in to the canal that indicates using of sealer to improve the sealability of Gutta percha [29]. Among these causes which contribute also to failure of conventional root filling with gutta percha is inability of operators adequately cleaned the canals, failure of adequately obturate the root canal to achieve hermetic seal, or some time presence of physical impediment and failure to seal all the communicated canals between the dental pulp and periradicular area [30]. This results in leakage of bacteria to surrounding peri-apical tissue [31]. Obtain a hermetic seal of root filling material apically is necessary to prevent the passage of bacterial products to peri-apical tissue [32]. While the higher success rate of MTA (94.76%) because it is a new material of choice and ideal biocompatible materials to use in apicectomy [29]. It is unlike other filling material that affected by moist environment, MTA is hydrophilic need moisture for setting, good marginal sealing ability and radiopacity [33]. The results of cytotoxic studies by Vrella et al. [34] of retrograde filling materials indicate that MTA is better than other materials i.e., amalgam, super EBA, gutta percha, glass ionomer cement and IRM and diaket. Studies indicate that MTA promote hard tissue formation by cementogenesis and osteogenesis [35]. It has high antibacterial properties in comparison with other filling materials. The high healing capacity with minimal inflammatory reaction indicated in cell culture studies. It has no cellular toxicity and induction of growth of cell and excessive release of calcium [36]. But studies about the disadvantages of the MTA include material toxicity, discoloration and the material is not easy to manipulate, slow setting, removal of material is difficult after setting, stable dimensionally, cannot be dissolved and expensive [37]. The bevel of the resected root apex in apicectomy is also important. Studies by Thom C 2004 indicate that as the bevel increases the leakage increase due to semi permeable dentinal tubules [38]. To increase the success of retrograde apicectomy

the resection should be perpendicular to the long axis of root and at least 3-4 mm of root apex should be removed [39]. The root end filling material is placed in to Class 1 cavity of depth adequately prepared (3 mm) using bur or it is better to use ultrasonic instrument to achieve hermetic seal and more successful outcome [40]. Selection the best material that seals the canal apically and prevents the bacterial leakage to per-apical tissue is important. Technological advancement make dentist able to check the best root end filling material [41]. Although an ideal root end material still not existing but the best material should be non-toxic, not carcinogenic, easily manipulated, radiopaque to identified easily, tissue biocompatible, and not affect by moisture and fluid and good sealability to prevent microbial leakage [42]. The wide range in success rate of retro filling materials by many studies which range from 52-97% are due to the lack of standard surgery and absence of exclusion and inclusion criteria's of the studies [43-45].

Conclusion

Retrograde apicectomy using different types of filling material is a highly successful surgical procedures to save hopeless teeth with fail conventional root canal treatment. The results clinical and radiographical examination of present study proved that MTA is a highly successful retrograde filling in comparison with Gutta percha and Amalgam. Determination and comparison of the success rate of these materials help dentist to select the best material to fulfill its objectives. Radiopacity, non-toxicity, non-irritating and healthy to promote hard and soft tissue regeneration peri-apically, bacteriostatic and dimensionally stable on contact to fluid and moisture are ideal properties to put in our consideration when we select the best retro filling material.

Acknowledgement

Special thanks to my family and my senior supervisor in college of dentistry, department of maxillofacial surgery who encourages me and help me to finish my study.

Recommendations

Selection of best retro filling material is important to prevent consequent health problem when using toxic material.

References

1. Saleem M, Ansari SR, Reham K. Success of dental amalgam as retrograde filling material. *Pakistan Dental & Oral Journal*. 2010; **12**: 21-43.
2. Vasudev SK, Geol BR, Taygi S. Review of root end filling materials. *Journal of Endodontics*. 2000; **3**: 13-18.
3. Porter ML, Bert O, Primus CM, Watanabe I. Physical and chemical properties of new root end fillings. *Journal of Endodontics*. 2010; **60**: 700-718.
4. Hussain WS, Khalaif HM. The success rate of retrograde filling materials. *Al-Rafidain Dental Journal*. 2012; **9**: 55-76.
5. Gupta SK, Saxena P, Newaskar V. Biocompatibility of root-end filling materials. *Restorative Dentistry & Endodontics*. 2013; **40**: 100-115.
6. Gatewood RS. Endodontic materials. *Dental Clinics of North America*. 2007; **65**: 306-315.
7. Aqrabawi J. Sealability of amalgam, EBA and MTA as retrograde filling in apicectomy. *British Dental Journal*. 2011; **2**: 200-314.
8. Dahl JE, Gutmann JL, Witherspoon DE. Toxicity of endodontic filling materials. *Endodontic Topics*. 2005; **15**: 45-67.
9. Pittford TR. Endodontic in clinical practice. *Journal of Endodontics*. 2004; **6**: 300-315.
10. Baek SH, Plenk H, Kim S. Periapical tissue responses and cementum regeneration with amalgam, Super EBA, and MTA retrograde fillings. *Journal of Endodontics*. 2005; **40**: 500-505.
11. Torbinejad M, Walton RE. Principles and practice of endodontics. *Journal of Endodontics*. 2002; **2**: 200-315.
12. Poggio C, Lombardini M, Alessandro C, Simonetta R. Root end fillings solubility. *Journal of Endodontics*. 2007; **70**: 2056-2078.
13. Lai CC, Huang M, Chan Y, Yang HW. Antibacterial effect of retrograde filling materials. *Journal of Endodontics*. 2003; **40**: 400-427.
14. Anusavice KJ. Science of dental material. *Dental Materials*. 2003; **11**: 202-211.
15. Neiderman R. Review of retro filling material. *Journal of Endodontics*. 2004; **14**: 56-77.
16. Gossman E. Practice of endodontic filling Endo. *Journal of Endodontics*. 2010; **12**: 508-578.
17. Asgary S. Comparison in sealability of endodontic cement as retro filling material. *Journal of Biomedical Materials Research*. 2008; **77**: 50-85.
18. Walivaara DA, Abrahamsson P, Isaksson S, Salata LA, Sennerby L, et al. Periapical tissue response after use of root end filling materials. *Journal of Oral and Maxillofacial Surgery*. 2012; **80**: 3000-3005.
19. Marshal SJ, Marshal JR, Grayson W, Anusavice KJ. Science of dental material. *International Dental Journal*. 2006; **14**: 67-78.
20. Swift EJ, Roberson JM, Heymann HO. Art and science of dentist. *International Dental Journal*. 2007; **17**: 700-708.
21. Vandana A. Toxicity of dental amalgam. *Toxicology International*. 2014; **17**: 90-97.
22. Berent S, Brukner JV. Adverse health effects of amalgam. *Journal of Toxicology*. 2004; **25**: 5-16.
23. Priyanka. SR. Review of literature of root end fillings. *Journal of Dental and Medical Sciences*. 2013; **20**: 46-67.
24. Saxena P, Gupta G, Newsakar V. Root end filling biocompatibility. *Restorative Dentistry & Endodontics*. 2013; **60**: 90-117.
25. Bansode PV, Pathak SD, Sakharkar R. Root end fillings material. *Journal Dental and medical studies*. 2016; **20**: 97-130.
26. Singh A. The toxicity of dental amalgam. *Toxicology International*. 2012; **40**: 108-119.
27. Gershwin EM. Dental amalgam adverse effects. *Journal of Toxicology*. 2005; **30**: 16-26.
28. Seema D, Wavdhane MB, Sakharkar R, Khedgikar SB. Retrograde root end filling materials. *Journal of Dental and Medical Sciences*. 2017; **15**: 189-200.
29. Chong BS, Ford TR. Root end filling materials. *Endodontics Topics*. 2005; **12**: 200-207.
30. Thomson TR, Berry JE, Somerman MJ. Maintenance of cementoblast expression of osteoclastin in presence of MTA. *Journal of Endodontics*. 2003; **40**: 600-617.
31. Souza NJ, Justo GZ, Haun M, Bincoletto C. Cytotoxicity of material used for repair of perforation. *International Endodontic Journal*. 2006; **55**: 78-99.
32. Thom C, Mathew G. Leakage of amalgam, composite, Super EBA compared with novel retrograde filling material. *Journal of Endodontics*. 2004; **13**: 600-687.
33. Zhu Q. Adhesion of osteoblast on root end filling materials. *Journal of Endodontics*. 2000; **35**: 407-518.
34. Vrella C, Dileggi R. Evaluation of root end resection with laser with or without placement of root end filling material. *International Journal of Dentistry*. 2011; **10**: 720-728.

35. Pereira C, Fernando F. Comparison of sealability of MTA, amalgam and Super EBA root end filling material. *Brazilian Oral Research.* , 2003; **18**: 186-200.
36. Pittford TR. Endodontic in clinical practice. *Journal of Endodontics.* 2004; **10**: 44-55.
37. Plenk H, SH, Kim S. Response of peri-apical tissue to amalgam, SEBA and MTA as retrograde filling. *Journal of Endodontics.* 2005; **50**: 77-90.
38. Haglund R, He J, Jarvis J, Safavi KE, Zhu Q. Effects of retrograde filling materials on fibroblasts and macrophages *in vitro*. *The Journal of Oral Surgery.* 2003; **103**: 475-510.
39. Zhou HM, Shen Y, Wang ZJ, Haapasalo M. Evaluation of cytotoxicity of root end filling materials. *Journal of Endodontics.* 2013; **50**: 500-517.
40. Yadav S, Wadhvani KK, Loomba K. Comparative sealability of different retrofilling material. *Journal of Endodontics.* 2016; **3**: 100-106.
41. Naito H. Alternatives to amalgam as retrograde filling in apicectomy. *Evidenced-Based Dentistry.* 2004; **11**: 500-587.
42. Yap AU, Chaung HK, Koh ET. Properties of root end filling material. *Journal of Endodontics.* 2005; **40**: 45-700.
43. Xavier CB, Pozza DH, Oliveira MG. Marginal sealability of root end fillings materials. *Journal of Endodontics.* 2005; **40**: 65-704.
44. Torabaginegad M, James D. Evaluation of micro leakage of root end filling materials. *Endodontics.* 2002; **46**: 20-56.
45. Amini S, Kheirieh S. Properties of new endodontic material. *Journal of Endodontics.* 2008; **50**: 5-1005.