

## Pulmonary Hemorrhage in an Infant with Coronavirus Infection

Prashant Agarwal<sup>1\*</sup>, Harbir Arora<sup>2</sup>, Ibrahim Abdulhamid<sup>3</sup>, Basim Asmar<sup>2</sup>, Girija Natarajan<sup>1</sup> and Sanjay Chawla<sup>1</sup>

<sup>1</sup>Departments of Pediatrics, Division of Neonatal-Perinatal medicine, Wayne State University, Carman and Ann Adams, USA

<sup>2</sup>Departments of Pediatrics, Division of Infectious Diseases, Wayne State University, Carman and Ann Adams, USA

<sup>3</sup>Departments of Pediatrics, Division of Pulmonary Diseases, Wayne State University, Carman and Ann Adams, USA

\*Corresponding author: Prashant Agarwal, Neonatology Fellow, 5240 Heather Dr, Apt M205, Detroit, MI 48201, USA, Tel: 0013135156712; E-mail: [pagarwal@dmc.org](mailto:pagarwal@dmc.org)

Received date: Apr 01, 2015; Accepted date: Apr 21, 2015; Published date: Apr 28, 2015

Copyright: © 2015 Prashant A, et al., This is an open-access article distributed under the terms of the Creative Commons Attribution License, which permits unrestricted use, distribution, and reproduction in any medium, provided the original author and source are credited.

### Abstract

Coronavirus is a common cause of upper respiratory tract infection in children and has also been occasionally associated with lower respiratory tract infections. Use of reverse transcriptase polymerase chain reaction has aided in the rapid and reliable detection of these viruses, and thus has led to identification of these viruses as etiology of respiratory disease in more cases. We here present a case of pulmonary hemorrhage in an infant associated with coronavirus OC43 respiratory infection.

**Keywords:** Pulmonary hemorrhage; Coronavirus

### Introduction

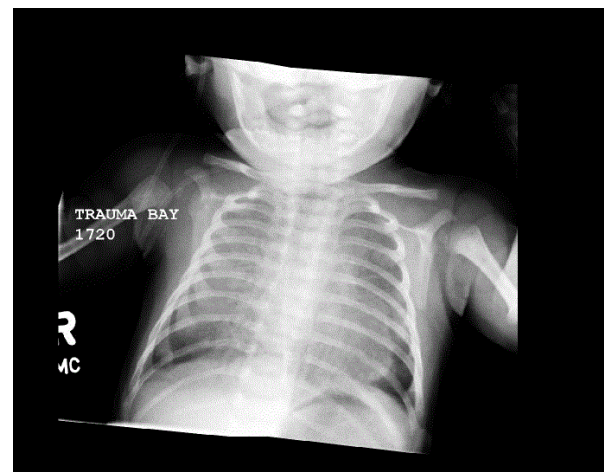
Pulmonary hemorrhage in children is associated with high mortality. Several medical conditions have been associated with pulmonary hemorrhage, including infection, trauma, vascular and bleeding disorders, lung malformations, heart defects, and idiopathic pulmonary hemosiderosis. Early identification of the etiology may help in its timely treatment.

### Presentation of the case

A 6 week old, full term male infant presented to Children's hospital of Michigan Emergency Department in January 2013 with cough and bloody secretions from mouth. He had history of nasal congestion and cough for 3-4 days and fast breathing for last 1-2 hours. There was no history of trauma, fever or bleeding from any other site. His father had upper respiratory tract infection with associated cough for previous 4-5 days. Patient's past history was significant for hypoxic ischemic encephalopathy after birth secondary to umbilical cord prolapse, for which he received therapeutic hypothermia and was hospitalized for 2 weeks. Patient had been doing well since discharge until the onset of the current symptoms.

In the Emergency Department he was noted to have cough, hemoptysis and was in respiratory distress (Include RR, HR and oxygen saturation in room air here). He had no bleeding from any other site. He had repeated episodes of oxygen desaturations and bradycardia. On physical examination, he was awake, pale, tachypneic and had hemorrhagic secretions from the mouth. On auscultation, he had crackles bilaterally with and normal heart sounds. His abdomen was soft and nontender, with no organomegaly. There was no bruising, petechiae or purpura noted. He was intubated in the Emergency Department. Fresh blood was aspirated from the endotracheal tube after intubation. Chest radiograph showed diffuse bilateral haziness consistent with pulmonary hemorrhage (Figure 1). Complete blood count showed a WBC of 12,500/mm<sup>3</sup> with 80% neutrophils and 14% lymphocytes, hemoglobin 9gm/dl, hematocrit

25.8% and platelets 318,000/mm<sup>3</sup>. Patient received fresh frozen plasma and packed red blood cells transfusion. Intravenous broad spectrum intravenous antibiotics were initiated for suspected pneumonia after blood culture was obtained. Tracheal aspirate samples were sent for bacterial and viral cultures as well as viral PCR studies. Eye examination and computed tomography scan of the head were normal.

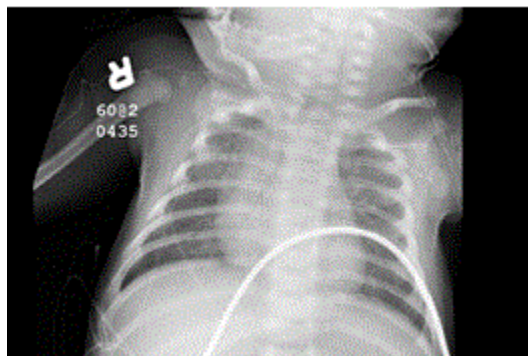


**Figure 1:** Chest radiograph on presentation showing bilateral haziness consistent with pulmonary hemorrhage.

Patient continued to have fresh blood aspirated from his endotracheal tube after hospitalization which slowly improved over 3 days. His ventilatory support was weaned and he was successfully extubated on the fourth day. His chest radiograph showed significant clearance of the initial bilateral haziness (Figure 2). Respiratory virus PCR panel from tracheal secretions obtained on day of admission was positive for coronavirus OC43. Bacterial cultures from respiratory secretions and blood showed no growth. He clinically improved and was discharged home on no supplemental oxygen. Additional work-up

for bleeding disorders and milk protein allergy were negative. Echocardiogram was also normal.

He has had no further episodes of pulmonary bleeding up to 14 months after discharge.



**Figure 2:** Chest radiograph before discharge showing clearance of pulmonary haziness.

## Discussion

To the best of our knowledge this is the first reported case of pulmonary hemorrhage in an infant in association with coronavirus infection. Pulmonary hemorrhage in children has been mainly associated with bacterial infections in relation to cystic fibrosis, bronchiectasis, necrotizing pneumonia and tuberculosis. There are few reports of pulmonary hemorrhage in adults with H1N1 and Flu A infection [1]. We hypothesize that like influenza, coronavirus can also lead to severe tracheobronchitis, alveolitis and diffuse alveolar hemorrhage.

At present, there are 6 coronaviruses recognized as human pathogens (HCoV): HCoV-OC43, HCoV-229E, HCoV-HKU1,

HCoV-NL63, SARS CoV and the newly identified Middle East respiratory syndrome coronavirus (MERS-CoV). Coronavirus is a common cause of upper respiratory tract infection in children. The incidence peaks in late winter and early spring. Transmission occurs primarily via a combination of droplet and contact spread. It is also occasionally associated with lower respiratory tract infections such as bronchiolitis and pneumonia, although most of these do not result in severe respiratory disease [2]. However, coronavirus OC43 has been associated with severe lower respiratory tract diseases in patients with high risk medical conditions such as asthma and immunosuppression [3,4].

Use of reverse transcriptase polymerase chain reaction (RT-PCR) has aided in the rapid and reliable detection of these viruses, and thus has led to identification of these viruses as etiology of respiratory disease in more cases [5]. Hence, it is important to consider it as a possible pathogen in susceptible patient population, presenting with significant respiratory symptoms including pulmonary hemorrhage.

## References

1. Gilbert CR, Vipul K, Baram M (2010) Novel H1N1 influenza A viral infection complicated by alveolar hemorrhage. *Respir Care* 55: 623-625.
2. Poutanen SM (2012) Human coronaviruses. *Principles and Practice of Pediatric Infectious Diseases*. (4th edn), Elsevier Churchill Livingstone, New York, USA.
3. Simon A, Volz S, Fleischhack G, Tillman R, Muller A, et al. (2007) Human coronavirus OC43 pneumonia in a pediatric cancer patient with down syndrome and acute lymphoblastic leukemia. *Journal of pediatric hematology/oncology* 29: 432-434.
4. Johnston SL, Pattemore PK, Sanderson G, Smith S, Lampe F, et al. (1995) Community study of role of viral infections in exacerbations of asthma in 9-11 year old children. *BMJ* 310: 1225-1229.
5. Van Elden LJ, van Loon AM, van Alphen F, Hendriksen KA, Hoepelman AI, et al. (2004) Frequent detection of human coronaviruses in clinical specimens from patients with respiratory tract infection by use of a novel real-time reverse-transcriptase polymerase chain reaction. *The Journal of infectious diseases* 189: 652-657.