

Primary Hepatic Neuroendocrine Tumour and its Metastasis to Breast: A Case Report of an Unusual Malignancy

M Amjad Zafar¹, Rabia Iqbal^{2*}, Amina Jafar², Ahmad Taimoor Bajwa², Sobia Yaqub¹, Ali Akbar¹

¹Department of Oncology, Mayo hospital, Lahore, Pakistan; ²King Edward Medical University, Lahore, Pakistan

ABSTRACT

Neuroendocrine Tumors (NETs) are rare tumors with varied clinical presentations. Entero-pancreatic and respiratory systems are usually involved but it can also affect unusual sites like the liver. We are presenting a case of a 45 years female who developed progressive and disabling symptoms of mass effect and carcinoid but remained undiagnosed for many years due to very low suspicion of such a tumor in liver. Diagnosis was made after extensive radiological, histopathological and biochemical investigations. By that time, disease had spread to Breast which is also not a typical feature of NETs. Diagnosis of rare tumors at an unusual site is challenging and requires high clinical suspicion and appropriate workup.

Keywords: Neuroendocrine tumors; Respiratory; Biochemical investigations

INTRODUCTION

Neuroendocrine tumors are rare tumors of the human body. World Health Organization (WHO) has classified neuroendocrine neoplasia according to their histological differentiation into low: Grade 1, G1; Intermediate: Grade 2, G2; High-grade: Grade 3; G3 and poorly differentiated Neuroendocrine Tumors (NET), later having a very elevated Ki 67 proliferative Index [1]. Most frequent location of NETs is the gastro-entero-pancreatic system followed by trachea-broncho-pulmonary system [2]. Mostly patients present with flushing, diarrhoea, abdominal pain, sweating and mass effects but unusual presentation is also seen. Diagnosis is made on the basis of various radiological (CT scan, MRI, Octreotide scan) and histopathological findings (synaptophysin and chromogranin positive on immunohistochemical staining). Primary hepatic NET was initially reported by Edmondson in 1958 [3] but still it is a rare entity with only a few cases available in literature. Most malignancy found in the liver is secondary to primary lesion found somewhere else in the body [4]. So diagnosis of primary liver NET requires thorough investigations including histological confirmation after liver resection and radiological evidence of no other primary site. Here we present a case of a 45 years old female who presented with symptomatic primary NET of liver with metastasis to Breast.

CASE PRESENTATION

In August 2013, A 45 year old female, with no known comorbid illnesses, first presented to the Emergency room with a complaint of abdominal pain. She was managed symptomatically and

workup was done to rule out cause. Abdominal ultrasound was unremarkable but CT scan of the abdomen showed two hypodense areas in the right lobe of the liver, an impression of haemangioma was made. So she was put on follow up. After 2 years, the patient reported symptoms of diarrhoea, flushing and increased sweating. The patient was referred to a gastroenterologist who treated the condition as Irritable Bowel Syndrome (IBS) but her symptoms got worse with passage of time. She remained undiagnosed till 2021, when a gastroenterologist advised her triphasic CT of liver which showed multiple hepatic focal lesions of variable sizes showing arterial phase enhancement and washout through the venous and delayed phase, consistent with multilobar HCC. The largest lesion was seen at the junction of segment V1 and V11, measuring 11.5 cm in the largest dimensions. The lesion caused mild mass effect on hepatic venous and portal venous branches without any obvious angioinvasion. On the CECT Chest, a small moderately enhanced nodule was also found in the inner half of the left breast measuring 9 mm in limited dimensions.

A preliminary diagnosis of HCC was made and AFP level was ordered which was found to be within normal range, with a value of 3.3 ng/dl. Serology for hepatitis B and C was also negative. Based on symptoms, a less probable diagnosis of NET was also considered, so further workup started. Urinary 5 HIAA was found to be elevated with a value of 10.3 mg/24 hours. In order to confirm diagnosis, Tru cut biopsy was done. On microscopic examination, tumour showed infiltrative glands and sheets of cells having pleomorphic, high N/C ratio and mitosis (Figure 1 and Figure 2).

Correspondence to: Iqbal Rabia, King Edward Medical University, Lahore, Pakistan; E-mail: rabiaiqbal999@icloud.com

Received: July 20, 2021; **Accepted:** July 28, 2021; **Published:** August 05, 2021

Citation: Zaffar AM, Iqbal R, Jafar A, Bajwa AT, Yaqub S, Akbar A (2021) Primary Hepatic Neuroendocrine Tumour and its Metastasis to Breast: A Case Report of an Unusual Malignancy. J Tum Res Reports, 6:145.

Copyright: © 2021 Iqbal R, et al. This is an open-access article distributed under the terms of the Creative Commons Attribution License, which permits unrestricted use, distribution, and reproduction in any medium, provided the original author and source are credited.

In Immunohistochemistry, tumor cells stained positive for synaptophysin, CDX7 and CDX2. Ki67 proliferation index of 3%-4%. Hence, a diagnosis of Neuroendocrine Tumor WHO grade 2 was made.

The patient underwent a dotatate PET scan to look for an undiagnosed primary. It showed massively enlarged liver and multiple, diffusely scattered, variable sized hepatic lesions that

showed intense tracer avidity. A small hypodense nodule in the left breast was seen but the rest of the scan was normal (Figure 3 and Figure 4).

Breast ultrasound and mammography was done which confirmed finding of lesion in left Breast measuring 10 mm ×6mm at 12° clock position. True cut biopsy of the lesion showed metastatic Neuroendocrine Tumour, WHO grade 1, with Ki67 proliferative index of 1%.

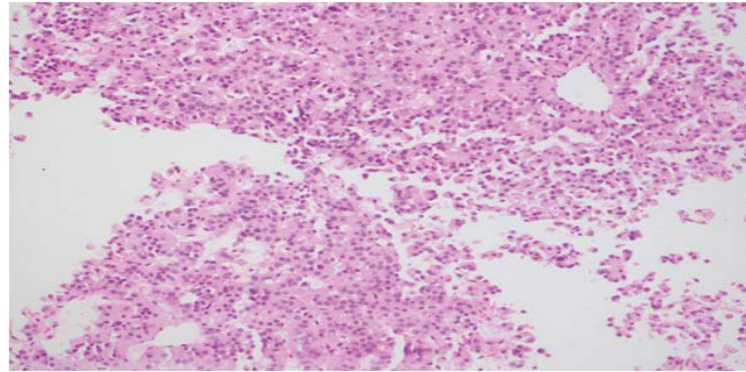


Figure 1: On microscopy, infiltrative glands and sheets of cells having pleomorphic, high N/C ratio and mitosis are seen.

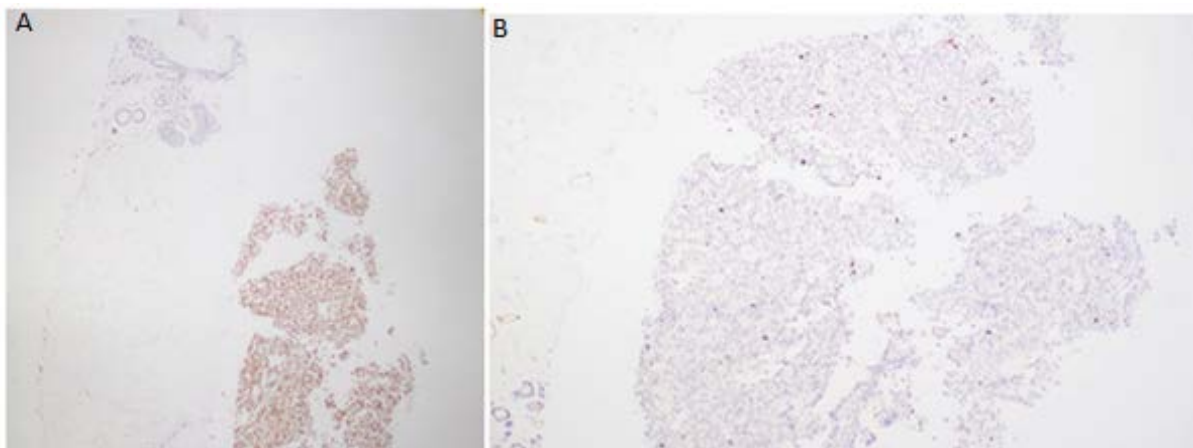


Figure 2: (A): IHC, showing positive staining for synaptophysin; (B): IHC showing positive ki67 of 3%-4%.

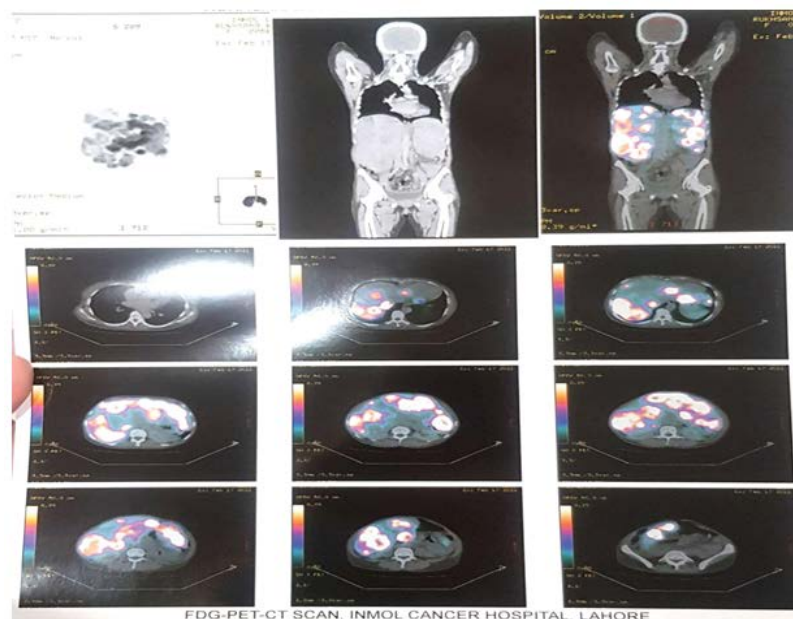


Figure 3: Dotatate PET scan showing enlarged liver with multiple, diffusely scattered, variable sized hepatic lesions showing intense tracer avidity.

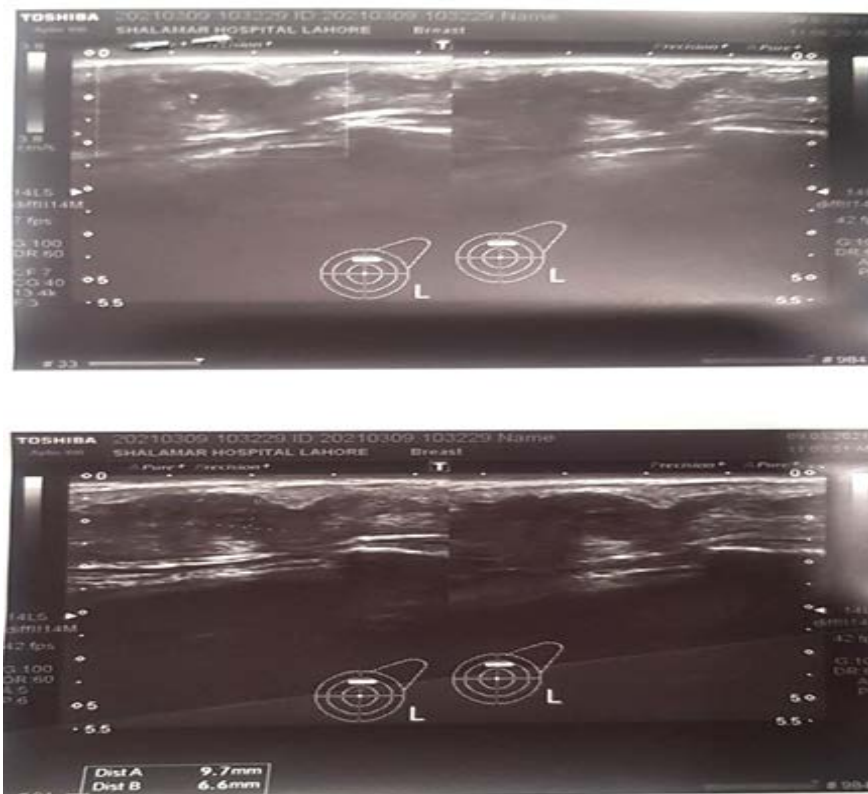


Figure 4: Breast ultrasound showing 10 cm × 6 cm lesion in left breast at 12° clock position.

The patient was told about the nature and extent of disease. The lesions in the liver were multifocal and bilobar, the largest lesion being 11.5 cm. The surgery was not an option at this stage of the disease. The patient was started on octreotide acetate monthly and was counseled about regular follow up to check the progression of disease [5].

DISCUSSION

Primary liver NETs are very rare as. We have various theories for explaining its pathogenesis. On one side it's said that primary neuroendocrine tumour of liver arise from adrenal or pancreatic tissue that is ectopically found in liver [6], while on other side it's thought that long standing inflammatory processes in biliary tract can cause Metaplastic changes in its epithelium results in NETs [7].

Mostly NET presents with flushing, diarrhoea, sweating etc. (carcinoid syndrome), but just in case of a liver primary NET, the presentation is either due to a mass effect like all other primary liver tumour, e.g. HCC or cholangiocarcinoma, or an incidental finding (silent hepatic mass) [8]. Patient may complain of right hypochondriac pain, jaundice, abdominal distension or palpable mass that's seen related to carcinoid syndrome in 6.8% cases [9]. In our case, the patient initially presented with mass effect while symptoms of carcinoid developed later on over years. The diagnosis typically requires various radiological and histopathological studies. Computed topography and resonance Imaging are initial investigational tools for any liver tumor [10], which provides a hyper vascular image but this is a common feature of major malignant hepatic lesions. For confirmation, histological evidence of typical NET cells containing trabecular and nested growth cellular patterns is required [11]. Other investigations like normal serum AFP levels, presence of chromogranin, 5-Hydroxyindoleacetic acid and neuron specific enolase provide further strengthen the

diagnosis [12]. Treatment options for primary liver NET basically involves liver resection with adequate cancer free boundaries if the tumor is resectable and has not undergone metastasis but as in our case, breast metastasis is found so chemotherapy, radiotherapy and long acting octreotide are often considered an option in such cases depending upon the danger benefit ratio. For those tumors that aren't ready to be removed completely are often treated with Transarterial Chemoembolization (TACE) to regress the tumor size by inhibiting its blood supply or liver Transplantation to urge better prognostic effects [13]. A prolonged follow up plan for primary liver NETs after surgery is required for a few important reasons, that is, to urge the right diagnosis and to ascertain the recurrence of the disease by multiple investigations in each visit. 18% patients show recurrent disease. In our case follow up, the patient had symptomatic disease that left undiagnosed for many years and was found to have metastasized to breast on diagnosis. In literature, we don't find any such case of metastatic NET of the liver, so we are unaware about disease course and prognosis in this case.

The diagnosis of a primary hepatic NET may be a challenge because they're mostly silent tumors. They don't show any sexual preference but females are more frequently affected. They are rare Tumors and it's a challenge to differentiate them from other liver tumors. They will easily be confused with HCC or cholangiocarcinoma and further studies are required to know about disease biology and behaviours that will help in better management of such cases [14].

CONCLUSION

NETs can arise at various unusual sites with different clinical presentations, diagnosis of which requires various radiological and histopathological parameters to be used in conjunction with clinical signs and symptoms.

REFERENCES

1. Sirohi B, Barreto SG, Shrikhande SV, Bhandare M, Bal M, Chacko RT et al. Indian Council of Medical Research consensus document for the management of gastroenteropancreatic neuroendocrine neoplasms. *Indian J Med Paediatr Oncol.* 2020;41(2):166-172.
2. Modlin IM, Sandor A. An analysis of 8305 cases of carcinoid tumors. *Cancer.* 1997;79(4):813-829.
3. Edmondson HA. Tumors of the liver and intrahepatic bile ducts. *Atlas of tumor pathol.* 1958.
4. Modlin IM, Sandor A. An analysis of 8305 cases of carcinoid tumors. *Cancer.* 1997;79(4):813-829.
5. Geramizadeh B, Kashkoe A, Malekhosseini SA. Liver metastasis of gastrointestinal neuroendocrine tumors: a single center experience. *Hepat Mon.* 2016;16(5).
6. Hsueh C, Tan XD, Gonzalez Crussi F. Primary hepatic neuroendocrine carcinoma in a child morphologic, immunocytochemical, and molecular biologic studies. *Cancer.* 1993;71(8):2660-2665.
7. Baek SH, Yoon JH, Kim KW. Primary hepatic neuroendocrine tumor: Gadoteric acid (Gd-EOB-DTPA)-enhanced magnetic resonance imaging. *Acta Radiol Open.* 2013;2(2):1-5.
8. Quartey B. Primary hepatic neuroendocrine tumor: what do we know now? *World J Oncol.* 2011;2(5):209.
9. Chen Z, Xiao HE, Ramchandra P, Huang HJ. Imaging and pathological features of primary hepatic neuroendocrine carcinoma: An analysis of nine cases and review of the literature. *Oncol Lett.* 2014;7(4):956-962.
10. Bajetta E, Ferrari L, Martinetti A, Celio L, Procopio G, Artale S et al. Chromogranin A, neuron specific enolase, carcinoembryonic antigen, and hydroxyindole acetic acid evaluation in patients with neuroendocrine tumors. *Pediatr Blood Cancer.* 1999;86(5):858-865.
11. Jia C, Zhang Y, Xu J, Sun K. Experience in primary hepatic neuroendocrine tumor. *Turk J Gastroenterol.* 2012;23(5):546-51.
12. Mills SE, Carter D, Greenson JK, Reuter VE, Stoler MH. *Sternberg's diagnostic surgical pathology.* Lippincott Williams & Wilkins. 2012.
13. Yang K, Cheng YS, Yang JJ, Jiang X, Guo JX. Primary hepatic neuroendocrine tumor with multiple liver metastases: a case report with review of the literature. *WJG.* 2015;21(10):3132.
14. Song JE, Kim BS, Lee CH. Primary hepatic neuroendocrine tumor: a case report and literature review. *J clin cases.* 2016;4(8):243.