

Clinical Image

Open Access

# Portal Cavernoma as a Complication of Liver Hydatid Cyst

Behnam Sanei\*

Department of Hepatobiliary and Pancreas Surgery, University of Esfahan, Esfahan, Iran

**Keywords:** Hydatid cyst; Portal cavernoma

## Case Presentation

A 46-year-old male was presented with new unexplained thrombocytopenia. During the clinical investigation a liver hydatid cyst was found. Also, the liver color-doppler showed portal hypertension, portal vein thrombosis, and portal cavernoma. The patient went under hydatid cyst cavity evacuation and simple cyst drainage (Figures 1-2).

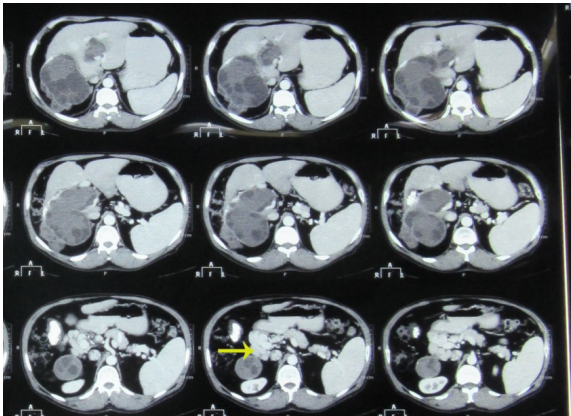


Figure 1: New unexplained thrombocytopenia.

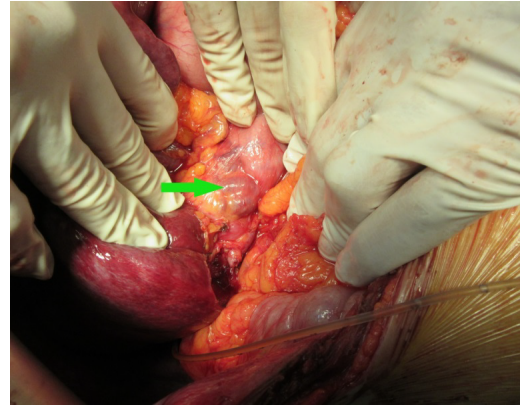


Figure 2: Liver color-doppler showed portal hypertension, portal vein thrombosis, and portal cavernoma.

**\*Corresponding author:** Behnam Sanei, Department of Hepatobiliary and Pancreas Surgery, University of Esfahan, Esfahan, Iran, Tel: 989131152604; E-mail: [b\\_sanei@med.mui.ac.ir](mailto:b_sanei@med.mui.ac.ir)

Received May 20, 2016; Accepted May 25, 2016; Published June 02, 2016

**Citation:** Sanei B (2016) Portal Cavernoma as a Complication of Liver Hydatid Cyst. J Liver 5: i101. doi:10.4172/2167-0889.1000i101

**Copyright:** © 2016 Sanei B. This is an open-access article distributed under the terms of the Creative Commons Attribution License, which permits unrestricted use, distribution, and reproduction in any medium, provided the original author and source are credited.