

## Performance of a new laser fluorescence diagnostic device in early carious lesion detection

Roxana Ranga<sup>1</sup>, Cristian Comes<sup>2</sup>, Marian Cuculescu<sup>3</sup>, Mihaela Dumitrache<sup>4</sup>, Oana Slușanschi<sup>5</sup>, Cristian Funieru<sup>6</sup>, Adrian Pandăre<sup>7</sup>

Bucharest, Romania

### Objective:

The latest method of detection for the early decay lesion-DIAGNOdent pen- based on red laser light induced fluorescence was introduced for the detection of approximal and occlusal caries. The aim of this study was to show the efficiency of this device versus clinical examination and fiber optic transillumination (FOTI).

**Material and method:** There have been examined in vivo 430 permanent teeth that is 2150 surfaces and 90 deciduous surfaces, cleaned by personal toothbrushing.

**Results:** DIAGNOdent pen reveals 10 times more occlusal early lesions than clinical exam and FOTI; for approximal surfaces it is better to use FOTI.

**Conclusions:** In this study the new laser fluorescence device performed on occlusal surfaces as well as the available device. Regarding the smooth and approximal surfaces, because of the standard values that we must take in consideration, we can decide a preventive or invasive approach according to the preventive goals of the 21st century.

**Keywords:** early carious lesion; occlusal caries; laser fluorescence; DIAGNOdent pen; FOTI.

Early diagnosis is a key factor in the prevention and management of dental caries. When dealing with early lesions, the doctor should be more concerned about the first symptoms and the cause of the carious disease, thus concentrating on the dental plaque. In the USA, Western Europe and Scandinavia, methods for the early detection of dental caries are already routine, a fact

that is in agreement with the aim of the 21<sup>st</sup> century dentistry – to implement preventive, non-invasive treatment beginning with dental plaque control.

Conventional diagnostic methods (clinical examination and x-ray) are no longer sufficient for the more modern approach to the clinical management of dental caries. Therefore, new complementary, objective

<sup>1</sup> DMD, PhD student, Lecturer, Department of Preventive Dentistry, Faculty of Dental Medicine, "Carol Davila" University of Medicine and Pharmacy, Bucharest

<sup>2</sup> DMD, PhD student, Lecturer, Department of Orofacial Diagnosis, Ergonomics and Research Methodology, Faculty of Dental Medicine, "Carol Davila" University of Medicine and Pharmacy, Bucharest

<sup>3</sup> DMD, PhD, Assoc. Prof., Department of Preventive Dentistry, Faculty of Dental Medicine, "Carol Davila" University of Medicine and Pharmacy, Bucharest

<sup>4</sup> DMD, PhD student, Lecturer, Department of Oral Health and Behavioral Sciences, Faculty of Dental Medicine, "Carol Davila" University of Medicine and Pharmacy, Bucharest

<sup>5</sup> DMD, Teaching assistant, Department of Preventive Dentistry, Faculty of Dental Medicine, "Carol Davila" University of Medicine and Pharmacy, Bucharest

<sup>6</sup> DMD, PhD student, Assistant, Department of Preventive Dentistry, Faculty of Dental Medicine, "Carol Davila" University of Medicine and Pharmacy, Bucharest

<sup>7</sup> DMD, Assistant, Department of Preventive Dentistry, Faculty of Dental Medicine, "Carol Davila" University of Medicine and Pharmacy, Bucharest

and quantitative methods for diagnosis and progress monitoring of dental caries are necessary.

The most recent method used in the diagnosis of early lesions - the **DIAGNOdent pen** – uses the emission of fluorescent radiation of a specific light wavelength to detect incipient lesions on both the occlusal and approximal surfaces of a tooth. Together with another device made by KaVo, the DIAGNOdent, the **DIAGNOdent pen** helps obtain valuable information in addition to the data gathered during the clinical examination or from the bite-wings x-rays. By using it, the doctor or the dental hygienist can also quantify and monitor the development of the carious lesion.

Fluorescence is a well known phenomenon in science and technology. In short, light of a certain wavelength is absorbed by a media and emitted as a longer wavelength. The auto fluorescence of the dental tissue has been observed by Benedict since 1928; red light and infrared fluorescence radiation are less absorbed and scattered by enamel than light of shorter wavelengths, thus penetrating the tooth more deeply [7].

Hibst and Gall [6] demonstrated that, when exposed to red light, altered tooth substance emits higher levels of fluorescent radiation than healthy enamel does. Also, research studies using spectroscopic analysis of fluorescent radiation [7], found that, when

exposing tooth tissue to red light with a wavelength of 655nm, the values of the emitted radiation was very different when comparing altered tooth substance with healthy enamel.

In 1998, taking into consideration the above mentioned data, the KaVo company (Biberach, Germany), introduced the DIAGNOdent classic, a device used for the detection and quantification of the carious lesion, especially for the occlusal area [8, 10]. In 2006, the same company released another device, the **DIAGNOdent pen**. Both devices operate on the same principle: when the altered tooth surface is exposed to a light wavelength of 655 nm it emits fluorescent radiation of values in direct relation to the amount of alteration. Sound tooth structure emits 0 or very low quantities of fluorescent radiation. The values of radiation are converted by the device in standard measurement units and printed on the display. The value range is between 0 and 99. Higher values correspond to more serious tissue damage. A beep is sounded by the device to indicate the existence of a cavity. The **DIAGNOdent pen** is 21 cm in length and has 2 sapphire light probes. The shorter probe with a cylindrical (tapered) shape and a diameter of 0.7 mm is used in pit and fissure areas, mostly on the occlusal surfaces. The longer probe has a wedged tip, with a diameter of 0.4 mm and a length of 1,1 mm



“Fig 1a DIAGNOdent”



“Fig 1b DIAGNOdent pen”



“Fig. 2a The probe for occlusal surfaces”



Fig. 2b Calibrating the probe on the ceramic disk

and is used for smooth surfaces and approximal surfaces. The instrument is cordless and can be held in ones hand like a pencil. It has interchangeable grip sleeves that can be also sterilized, integrated loudspeaker with adjustable volume, a steribox probe container, and a ceramic disk for the calibration of the probe.

In order to detect the correct depth of the carious lesion, it is recommended to keep the probe in a perpendicular position while scanning the tooth surface. In this way, the maximum quantity of fluorescent radiation emitted by the tooth can be captured by the probe.

There are certain rules to consider when using **DIAGNOdent pen** (3):

- the measurements will be done at room temperature [1];
- the tooth surface has to be free of dental plaque, tartar, colorations of any kind; otherwise false-positive results may be recorded [13];

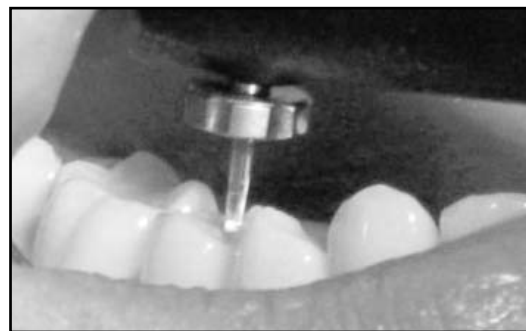
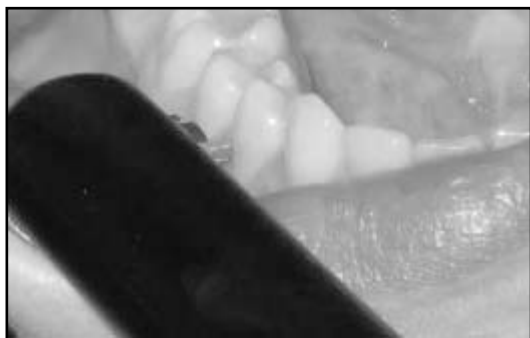
Fig nr 3. Using the measuring probes on tooth surfaces: a. approximal, b. occlusal

● probe calibration on the ceramic disk is very important for the accuracy of the measurement made over a longer period of time [9]; if not used for 90 seconds, the instrument will automatically turn off and calibration has to be made again.

The advantages of using **DIAGNOdent pen**, as pointed out by the manufacturer, are as follows:

- it is easy to handle, portable, and can be used in collectivities;
- it is safe both for the doctor and for the patient because it emits only low energy, non-ionized radiation;
- clinical examination using **DIAGNOdent pen** is painless and non-invasive;
- it offers over 90% accuracy in detecting carious lesions that cannot be detected by clinical examination or bite-wing x-rays;
- it can be used to monitor the progress of a carious lesion;
- it can determine, with accuracy,

whether the lesion is incipient or advanced, thus indicating the correct treatment procedure;

- it detects secondary caries and can assess the degree of tooth surface demineralization after the removal of fixed orthodontic appliances;

- it can be used as an interactive diagnosis method, that involves the patients, the doctor, the students, etc.

#### **How to use DIAGNOdent pen:**

- remove any dental plaque, tartar or colorings from the tooth surface;

- dry tooth surface;

- scan the tooth holding the probe as close to the perpendicular position as possible;

- recording the standard measurement units and putting the diagnosis;

establishing a treatment plan and monitoring the results over a period of time.

According to Lussi [10, 11] and the manufacturer, the interpretation of the resulting values is as follows:

- values between 0-13 indicate a sound tooth; regular toothbrushing is enough;

- values between 14-20 point to an existing incipient lesion; professional teeth cleaning and fluoridation are required;

- values between 21-29 indicate the existence of deep enamel caries; intensive professional teeth cleaning, fluoride treatment, diet control or/and even minimally invasive restorations are needed;

- values over 30 are an indication of dentine caries; treatment should include mini-

mally invasive restoration and intensive professional teeth cleaning.

Conservative treatment results are very good when using **DIAGNOdent pen** as a diagnostic device together with information regarding the caries risk factor for a particular patient. The patient, made aware of the caries risk involved, also contributes actively to the preventive treatment by coming, every 6 months, for check-ups.

This study has attempted to emphasize the efficiency of laser-fluorescence (LF) and fiber optic trans-illumination (FOTI) as complementary methods in diagnosing the early carious lesion.

It has also demonstrated the interactive and didactic role of the **DIAGNOdent pen**, as the students in our university have helped with the examination and evaluation of the patients.

#### **Material and method**

A number of 430 permanent teeth (2150 tooth surfaces) and 18 temporary teeth (90 tooth surfaces) were clinically and by use of FOTI and **DIAGNOdent pen** examined. Before examination, the patients thoroughly, brushed their teeth.

**Clinical examination:** the halogen bulb of the dental unit provided the direct light source, while the indirect light was given by use of the dental mirror; the tooth surfaces were dried for 5 seconds [4] by use of the air syringe and the visible white spots from buccal, oral, proximal and occlusal surfaces



**Fig. 4** Using DIAGNOdent pen



Fig. 5 FOTI

were recorded.

**Fiber optic trans-illumination (FOTI) examination:**

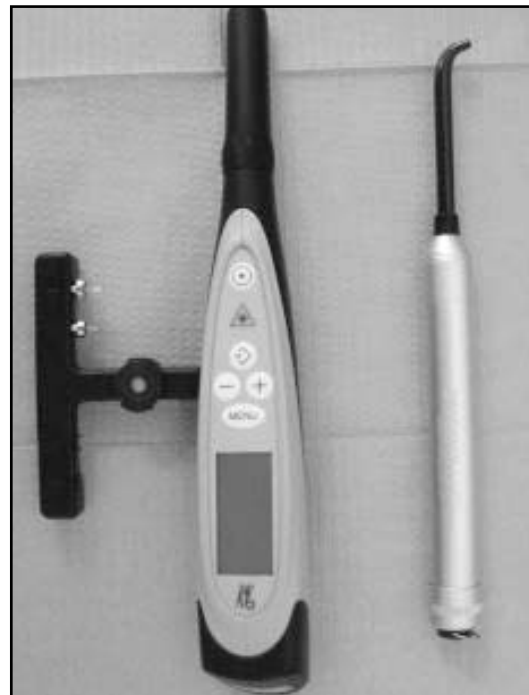We used **Microlux Transilluminator** (AdDent Inc) in this study. The probe was placed on the tooth from the direction of the occlusal area in order to detect the incipient lesions on the occlusal surface and perpendicular to the smooth surface of the tooth, beneath the contact point for the examination of the approximal area.

The probe was disinfected with Zeta 3 (Zermack).

**Laser-fluorescence examination:**

The shorter probe of the **DIAGNOdent pen** was used to examine the occlusal surfaces. During the scanning of the tooth the probe was kept as perpendicular to the examined surface as possible. The longer probe was used on approximal surfaces.

The recorded data was made in standard units of measurement: 0-13 sound tooth; 14-20 incipient lesion, preventive treatment



“Fig. 6 DIAGNOdent vs. FOTI”

needed; 21-29 deep enamel caries needing preventive or curative treatment depending on the patients' caries risk factor; over 30 dentine caries which require curative treatment [10,12].

The probes were disinfected with Zeta 3 (Zermack).

The examination was made by the same person.

**Results:**

**DIAGNOdent pen** indicates 10 times more incipient lesions than the clinical examination does and 15 times more than the FOTI

	Clinical Ex. Smooth	Clinical Ex. Approx	Clinical Ex. Occ. Surf.	FOTI Smooth surf.	FOTI Approx surf.	FOTI Occ. Surf.	LF Smooth surf.	LF Approx surf.	LF Occ. surf.
18 temporary teeth=90 surfaces	7	3	-	10	6	2	5	4	4
430 permanent teeth= 2150 surfaces	83	44	5	138	79	3	70	54	50

**Table 1:** Distribution of the incipient lesion on dental surfaces in relation to the diagnostic methods

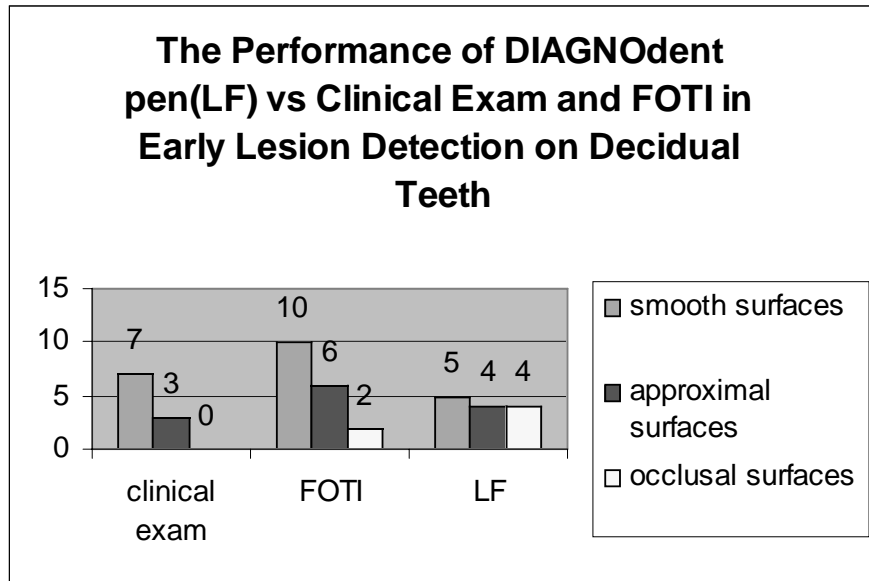


Diagrama 1

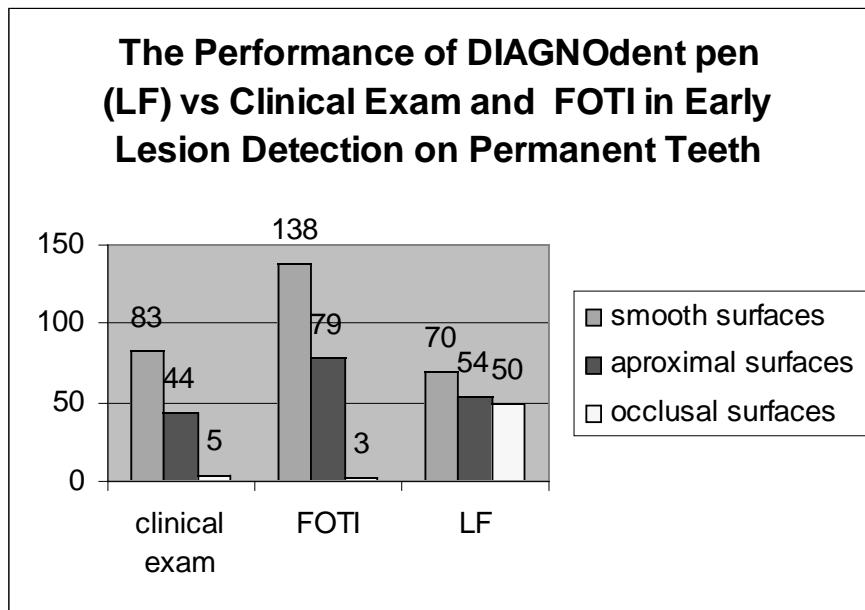


Diagrama 2

examination does on the occlusal surfaces of permanent teeth.

When examining the approximal area or smooth surfaces FOTI proved to indicate more lesions than both **DIAGNOdent pen** or clinical examination did.

Clinical examination of smooth surfaces revealed more lesions than **DIAGNOdent pen** did.

For the temporary teeth, the results showed that the incipient lesions on the occlusal surfaces are best indicated by laser-fluorescence, while the ones on smooth surfaces are best detected with FOTI.

Although, at first glance, it seems that the clinical examination detects more incipient lesions than laser-fluorescence does, one should keep in mind that **DIAGNOdent** indicates, also, the lesion's depth, thus differentiating between the enamel caries, which need conservative treatment, and the dentine caries, for which invasive treatment is required.

**The following facts can be drawn from Diagram 3:**

- incipient lesions are more frequent on smooth surfaces than on approximal and

occlusal areas;

- FOTI seems to be the most appropriate tool for diagnosing incipient lesions on smooth and approximal surfaces;

- for the occlusal area, **DIAGNOdent pen** is, by far, the tool that gathers the most information

- **DIAGNOdent pen** is also efficient in detecting incipient lesions on approximal surfaces; when used on smooth surfaces it seems to detect even less lesions than the clinical examination does.

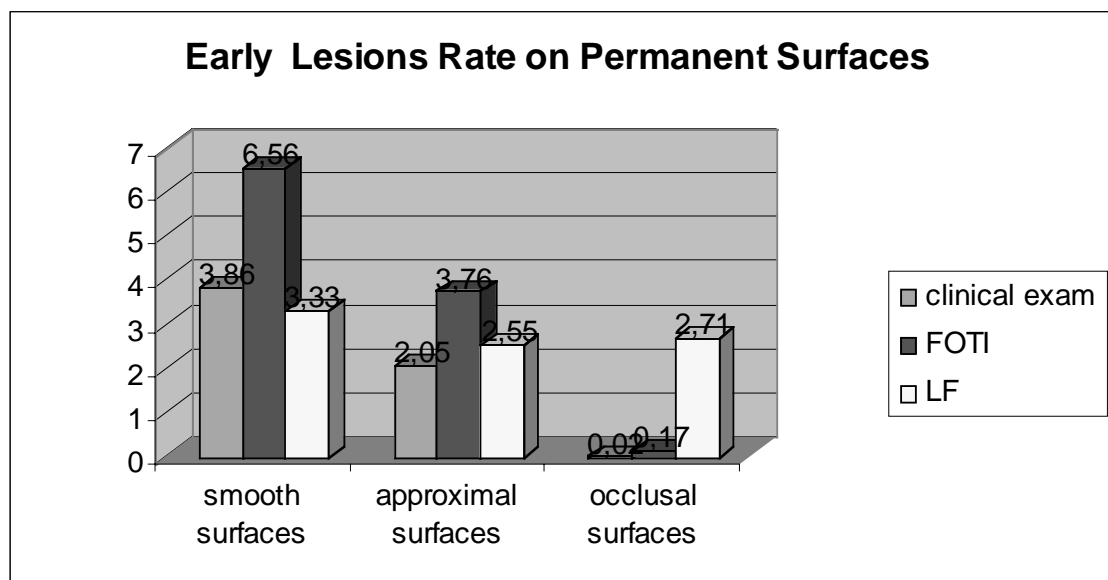
#### Observations:

- **DIAGNOdent pen** is a fragile instrument that can easily be damaged when not handled carefully;

- students should use it, as a didactical tool, only under strict supervision;

- if the tooth surface is not thoroughly dried, the measurement result can turn out false-positive, or the unit could lose its calibration;

- because it is an expensive device, it should be bought only for use in communities, for the purpose of drawing up and implementing prevention programs.



**Diagrama 3**

	Cl. Exam. Smooth surf.	Cl. Exam. Approx	Cl. Exam. Occ.	FOTI Smooth surf.	FOTI Approx surf.	FOTI Occ. surf.	LF Smooth surf.	LF Approx surf.	LF Occ. Surf.
Incipient lesion distributi on frequency	3,86%	2,05%	0,02%	6,5%	3,76%	0,17%	3,33%	2,55%	2,7 %

**Tabel 2.** Distribution of incipient lesions on dental surfaces.

### Conclusions:

The present study is in agreement with other published studies; more correlations will be done in the near future.

- DIAGNOdent can be used both by the doctor and by the dental assistant or by students, as a modern diagnostic device, complementary to the clinical examination [8, 12], in detecting the carious lesions (in this case, the early lesions) on the occlusal surfaces [7,13];

- **DIAGNOdent pen** can be used to monitor the evolution of the carious lesion on the approximal surfaces[12];

- on smooth surfaces, the device can be used to monitor the evolution of the early lesion in time, especially after the removal of fixed orthodontic appliances [1, 2, 5];

- the laser fluorescence device, the DIAGNOdent, helps with caries prediction for the permanent dentition, it estimates the existence and depth of the early lesion for the temporary dentition and is more efficient on smooth surfaces [9, 14];

- ADA Council of Scientific Affairs gave its agreement for only 2 diagnostic devices, DIAGNOdent 2095(LF) and QLF Inspektor Pro, which are to be used only as complementary tools, for bringing additional information to the one brought by clinical and x-ray examinations.

This way, all doubts are eliminated, no ionized radiation is used and the dental probe doesn't have to be used in scanning the tooth, which eliminates the risk of transforming an inactive carious lesion into an active one.

The carious lesion is present in 97% of the population. Early detection of the early lesion enables the doctor to apply non or minimal invasive treatment procedures, which help prolongue the life of a tooth [3]. Also, modern diagnostic methods should be able to detect the incipient lesion as early as possible, enabling the doctor to categorize his patients according to their carious risk factors, thus, applying the best course of treatment.

### References:

1. Aljehani A, Bamzahim M, Yousif MA, Shi XQ - "In vivo reliability of an infrared fluorescence method for quantification of carious lesions in orthodontic patients.", *Oral Health Prev Dent*. 2006;4(2):145-50.
2. Aljehani A, YangL, Shi X-Q. - *In Vitro* Quantification of Smooth Surface Caries with DIAGNOdent and the DIAGNOdent pen. *Acta Odontologica Scandinavica* 2007;65(1):60-63.
3. Berg HJ. - Dental Caries Detection and Caries

Management by Risk Assessment. *Journal of Esthetic and Restorative Dentistry* 2007;19(1):49.

4. Ekstrand, K.R.; Bruun, G.; Bruun, M. - Plaque and Gingival Status as Indicators for Caries Progression on Approximal Surfaces, *Caries Res* 1998;32:41-45.

5. Heinrich-Weltzien R, Kuhnisch J, Ifland S, Tranaeus S, Angmar-Mansson B si colab. - Detection of Initial Caries Lesions on Smooth Surfaces by Quantitative Light-Induced Fluorescence and Visual Examination:an *in vivo* comparison. *Eur J Oral Sci* 2005;113:494-499.



6. Hibst, R., Gall, R.: "Development of a Diode Laser-Based Fluorescence Detector" *Caries Res* 32, 294, 1998.

7. Hibst R, Paulus R, Lussi A. - Detection of occlusal caries by laser fluorescence. Basic and clinical investigations. *Med Laser Appl*. 2001;16:205-13.

8. Kuhnisch J, Bucher K., Hickel R- "The intra/inter-examiner reproducibility of the new DIAGNOdent Pen on occlusal sites", *Journal of Dentistry*, 2007, v. 35, n. 6 pg 509-512

9. Karlsson L, Tranaeus S, Angmar-Månsson B - "In vivo correlation between laser fluorescence and QLF for quantification of incipient smooth surface lesions". *Caries Res*. 2003;37: p. 288-289.

10. Lussi, A. et al.: "Clinical performance of a laser fluorescence device for detection of occlusal

caries lesions", *Eur J Oral Sci* 2001; 109, p. 14-19.

11. Lussi A, Hack A, Hug I, Heckenberger H, Megert B si colab. – Detection of approximal caries with a new laser fluorescence device. *Caries Res* 2006;40(2):97-103.

12. Lussi A, Hellwig E. – Performance of a New Laser Device for the Detection of Occlusal Caries *in vitro*. *Journal of Dentistry* 2006;34(7):467-471.

13. Lussi A.; Longbottom C.; Gyax M; Braig F. - Influence of Professional Cleaning and Drying of Occlusal Surfaces on Laser Fluorescence in vivo, *Caries Res* 2005;39:284-286.

14. Mendes FM, Siqueira WL, Fernandes Mazzitelli J, Pinheiro SL, Bengtson AL – Performance of DIAGNOdent for Detection and Quantification of Smooth-Surfaces Caries in Primary Teeth. *Journal of Dentistry* 2006;34(1):62-66.