

Percutaneous Coronary Intervention in Patients with Heparin Induced Thrombocytopenia: Case Report and Review of Literature

Narasimha D, Jutzy K and Hilliard A*

Cardiac Catheterization Laboratory, Loma Linda University, USA

Abstract

Heparin Induced Thrombocytopenia (HIT) is a rare disorder, which manifests as acute onset thrombocytopenia within five to fifteen days after exposure to heparin. The milder version of the disease may manifest as asymptomatic thrombocytopenia, which resolves with cessation of heparin. The more severe form presents with arterial and venous thrombi, profound thrombocytopenia and is associated with devastating consequences such as myocardial infarction, stroke, limb ischemia etc. The management of patients with HIT undergoing revascularization in the form of Percutaneous Coronary Intervention (PCI) and/or Coronary Artery Bypass Grafting (CABG) can be challenging and complicated by acute stent thrombosis and early graft closure. Management strategy consists of immediate discontinuation of all heparin products, alternative anticoagulation, and lifelong avoidance of heparin products. Here we describe the various challenges specifically associated with coronary re-vascularization in these patients, and the current treatment options available.

Keywords: HIT; Direct thrombin inhibitors; PCI; Bivalirudin; Heparin Induced Thrombocytopenia (HIT)

Introduction

Heparin Induced Thrombocytopenia (HIT) is defined as a decrease in platelet count $<150,000$ or over 50% of baseline occurring 5-15 days after the use of Unfractionated Heparin (UFH), or low-molecular weight heparin (LMWH) caused by an immune response [1]. HIT when associated with thrombosis (HITT) can have devastating consequences due to the formation of arterial and venous thrombi. In cardiac patients requiring Percutaneous Coronary Intervention (PCI) and/or Coronary Artery Bypass Grafting (CABG) management of HIT can be, challenging given that anticoagulation is imperative for these procedures. In addition, there is a high risk for stent thrombosis and graft occlusion following re-vascularization. We present a case report highlighting the clinical and therapeutic challenges faced in a patient with HIT undergoing both PCI and a CABG, and review the current literature in regards to management of these patients.

Pathophysiology and clinical presentation

HIT occurs in around 5-10% of patients treated with heparin [1]. It usually occurs 5-15 days after heparin administration. Thrombocytopenia occurring more than two weeks after exposure to heparin is usually not due to HIT but can be considered in the differential if other causes are ruled out. HIT can occur from the intravenous or subcutaneous administration of heparin, and also with the use of heparin coated catheters and heparin flushes [2,3]. In HIT patients who have received heparin before, re-administration of heparin has been associated with a higher risk for significant thrombocytopenia and thrombosis [4]. UFH is also more likely to cause HIT compared with LMWH. Heparin and platelet factor four (PF 4) form a complex that triggers the production of immunoglobulin G (IgG) against this complex [3]. Platelets express the Fc receptor on their surface, which binds to this IgG resulting in enhanced platelet aggregation and thrombocytopenia. In addition, this complex causes the release of pro-coagulant factors such as Thromboxane A₂ from the platelets, which stimulates thrombosis. This manifests as arterial and venous thrombosis and can present as deep venous thrombosis, stroke, limb ischemia, or myocardial infarction. Clinically HIT can also be asymptomatic without thrombotic features and only mild decrease

in platelet count. Thrombosis occurs in about 20-50% of patients. The diagnosis of HIT includes a history of heparin exposure over the past few days to months, clinical signs and symptoms of thrombosis, and laboratory data. The 4T scoring system can be used as an aid to diagnosis (Table 1) [5].

Laboratory diagnosis and management

Various laboratory tests are available for the diagnosis of HIT with varying sensitivities and specificities. These include Enzyme Immunoassay (EIA) for polyclonal antibodies (IgG, IgA, and IgM) which have a low specificity as it is not specific for IgG, but this test can be used as a screening test [1]. Other tests include platelet activation tests such as Serotonin Release Assay (SRA) or heparin-induced platelet activation testing (HIPA testing). These have high specificities but are performed only in certain laboratories, and usually take several days to report. Once HIT is suspected all heparin products should be stopped, including heparin coated catheters, heparinized flushes, etc. Alternative anticoagulants such as Direct Thrombin Inhibitors (DTI) should be started (Table 2) [5]. Warfarin should generally not be started until the thrombocytopenia resolves, as there is a high risk for skin and limb gangrene. Platelet transfusions are contraindicated, as this can lead to further thrombosis, unless the patient has major bleeding [1].

Case Report

A 73-year-old male with Coronary Artery Disease (CAD) was admitted on 12/23/2011 with a Non-ST Segment Elevation Myocardial Infarction (NSTEMI). He was found to have a low platelet count on

***Corresponding author:** Anthony Hilliard, Associate Chair of Cardiology, Director of Cardiac Catheterization Laboratory, Associate Professor of Medicine, 11234 Anderson Street, Suite 2426, Loma Linda University, Loma Linda, CA 92354, USA, Tel: +1 909 558 4498; E-mail: AAHilliard@llu.edu

Received November 24, 2016; **Accepted** December 05, 2016; **Published** December 12, 2016

Citation: Narasimha D, Jutzy K, Hilliard A (2016) Percutaneous Coronary Intervention in Patients with Heparin Induced Thrombocytopenia: Case Report and Review of Literature. Cardiovasc Pharm Open Access 5: 202. doi: [10.4172/2329-6607.1000202](https://doi.org/10.4172/2329-6607.1000202)

Copyright: © 2016 Narasimha D, et al. This is an open-access article distributed under the terms of the Creative Commons Attribution License, which permits unrestricted use, distribution, and reproduction in any medium, provided the original author and source are credited.

Criteria	Score		
	2	1	0
Degree of thrombocytopenia*	Decreased platelet count by >50% and min. platelet count $\geq 20 \text{ g L}^{-1}$	Decreased platelet count by 30-50% or min. platelet count $10-19 \text{ g L}^{-1}$	Decreased platelet count by <30% or min. platelet count $<10 \text{ g L}^{-1}$
Timing from heparin inclusion to a drop in platelet count	5-10 days or ≤ 1 day (if the patient was exposed to heparin within 30 last days)	Probably 5-10 days (e.g., lack of laboratory results), >10 days or ≤ 1 day when unexposed to heparin within previous 30-100 days	≤ 4 days when recently not exposed to heparin
Thrombosis or other symptoms of HIT	Confirmed thrombosis at new location, skin necrosis, acute systemic reaction following intravenous bolus of unfractionated heparin	Aggravation or recurrent thrombosis, skin lesions without necrosis (erythematous) suspicion of thrombosis	Absent
Other causes of thrombocytopenia	Absent	Possible	Present

Table 1: 4T Criteria for heparin induced thrombocytopenia.

Drug and its short characteristics	Dosage form	Dosage	Monitoring	Combined with thrombin
Lepirudin A synthetic analogue of hirudin (detected in secretion of medical leeches) Half-life 60-80 min, increasing in an unpredictable way in patients with renal dysfunction	Powder for preparing intravenous solution: Vials 20 mg Vials 50 mg	Saturating dose (bolus): 0.4 mg kg^{-1} (not obligatory). followed by continuous infusion $0.15 \text{ mg kg}^{-1} \text{ h}^{-1}$	APTT (1.5-2.5-fold prolongation)	Irreversible complexes
Bivalirudin A synthetic molecule consisting of two fragments of hirudin Half-life 25 min. It is decomposed by proteolytic degradation in plasma	Powder for preparing venous solution: Vials 250 mg	Without a saturating dose continuous infusion $0.15-0.20 \text{ mg l}^{-1} \text{ h}^{-1}$ (during PCI bolus 0.75 mg kg^{-1} , followed by continuous infusion 1.75 mg kg^{-1})	APTT (1.5-2.5-fold prolongation)	Irreversible complexes
Argatroban A synthetic derivative of 1-arginine Half-life 40-50 min; almost completely metabolised by the liver	Intravenous form: Ampoules 250 mg	Without a saturating dose, continuous infusion 2 pg min^{-1} (in critically ill patients, those after cardiac surgical procedures or with hepatic failure, an infusion $\text{pg kg}^{-1} \text{ min}^{-1}$ is recommended)	APTT (1.5-3-folds prolongation)	Irreversible complexes
Dabigatran Pro-drug. Its structure is similar to that of benzamidine thrombin inhibitor (serine protease) Therapeutic concentration 2-4 h after administration Terminal half-life in healthy volunteers-approximately 8 h whereas in elderly individuals with renal failure-12 h	Oral form: Capsules 75 mg Capsules 110 mg Capsules 150 mg	$220-300 \text{ g day}^{-1}$ (decreased doses suggested in the elderly and patients with renal failure)	Not necessary	Irreversible complexes

Table 2: Direct thrombin inhibitors [5].

further work-up and a HIT panel was ordered on suspicion of HIT. He underwent coronary angiography on argatroban, and underwent successful stenting of a 90% first diagonal lesion with a Drug Eluting Stent (DES) and was started on aspirin, and clopidogrel, and bridged to coumadin. Six days after the procedure, he suffered a STEMI and was taken to the cath lab emergently where he was found to have acute thrombosis of the diagonal stent. Multiple attempts at aspirating the thrombus and performing PCI were unsuccessful, and as the patient continued to have significant chest pain, he was taken to the operating room for an emergent CABG. He received venous grafts to the first obtuse marginal (OM), first diagonal branch, and the Left Anterior Descending artery (LAD). He did well for two months after the CABG, but returned to hospital March 2012 with unstable angina, and on angiography all three grafts were found to be occluded at the Ostia. He underwent stenting of the OM and the previously stented diagonal branch, and dual anti-platelet therapy along with Coumadin was continued. His Right Coronary Artery (RCA) had mild-moderate non-obstructive CAD. He presented with chest pain in June 2015 and was found to have 95% disease of his mid RCA and 80% distal RCA disease (on his previous angiogram done 6 months prior patient had a 40% lesion in the mid RCA). He received DES to both his RCA

lesions. He presented with unstable angina 9 months later, in March 2016, and on angiography was found to have 90% in-stent re-stenosis of the previously stented first OM, which was balloon, dilated. On his angiogram 9 months before, his first OM did not have angiographic ally significant re-stenosis. He returned two months later with angina and on angiography had severe in-stent re-stenosis of his OM stent. Another stent was placed successfully in the proximal OM at the site of the in-stent re-stenosis. He has been on aspirin, clopidogrel, and warfarin for the last five years and reports good medication compliance. His initial PCIs in 2011 and 2012 were performed on argatroban, with subsequent PCIs being performed on bivalirudin. He did not experience significant thrombocytopenia or acute arterial/venous thrombi during any of these procedures.

Stent thrombosis in HIT patients

Our case highlights the difficulties faced in achieving and maintaining adequate re-vascularization in patients with HIT. Our patient was managed on dual anti-platelet (DAPT) and Coumadin throughout, but continued to suffer multiple stent closures and graft closures after CABG. There have been multiple case reports of acute and sub-acute coronary stent thrombosis in patients with HIT. Hussain

et al. [6], describe the case of a 39-year-old patient who underwent bare metal stenting of his LAD, receiving UFH at the time of the PCI. The patient presented in cardiogenic shock, required placement of an intra-aortic balloon pump, and received abciximab for a high thrombus burden in his LAD. Nine days after the PCI, he suffered a STEMI and on angiography substantial amounts of thrombus was seen, which was aspirated. Heparin was stopped, and patient was placed on bivalirudin and abciximab. Bivalirudin was subsequently transitioned to danaparoid. Shin et al. [7], describe the case of a sixty-two year old woman who presented with an inferior STEMI, and underwent stenting of her RCA, but coronary flow was not achieved due to recurrent thrombus formation despite repeated thrombus aspiration. The authors administered intracoronary, followed by intravenous, abciximab. Following this all heparin, products were stopped and patient was started on argatroban infusion for five days, after which the argatroban was stopped and aspirin and clopidogrel were started. Subsequently the patient received thrombus aspiration and balloon angioplasty of the RCA on argatroban with restoration of flow. She was discharged on aspirin, clopidogrel, and warfarin. Cruz et al. [8], describe the case of a sub-acute stent thrombosis around one month after implantation of a heparin coated stent in a patient with RCA stenosis. A case of spontaneous thrombus formation in the left main and RCA ostia has been described in the setting of HIT following aortic valve replacement in a patient on UFH [9]. Other similar cases of acute and sub-acute stent thrombosis have been described in patients with HIT [10]. There have been smaller studies testing patients presenting with acute coronary syndrome (ACS) for the presence of HIT antibodies. Matsuo et al. [11] tested forty ACS patients for the presence of HIT antibodies, compared this to fifty-one non-ACS patients, and found that there was a higher incidence of HIT antibodies in patients presenting with ACS, and patients with these antibodies experienced significantly higher episodes of per-PCI thrombotic complications.

PCI in the setting of HIT

PCI requires aggressive anticoagulation to prevent stent and catheter thrombosis. Anticoagulation during PCI is usually achieved with either UFH or bivalirudin. In patients with HIT, DTI are the recommended drugs of choice. These drugs inhibit thrombin directly and bind to both the free and the bound form of thrombin. DTIs

include argatroban, bivalirudin, lepirudin, and hirudin [3]. If DTIs are not available, alternatives include Factor Xa inhibitors such as fondaparinux and danaparoid. Danaparoid is not available in the US, and fondaparinux in rare cases can potentially cross react with HIT antibodies causing thrombosis and hence is not recommended as the first choice drug for these patients and is contraindicated in patients treated with an invasive strategy of coronary angiography [12]. Various alternative anticoagulants are described in detail below.

Use of bivalirudin in HIT

Chemistry: DTIs are classified into univalent and bivalent based on whether the drug interacts at the active catalytic site of thrombin alone (univalent) or whether the exosite I i.e., the fibrinogen binding site is also recognized by the DTI (bivalent) [13]. Univalent DTIs include argatroban, and melagatran. Lepirudin, and bivalirudin are examples of bivalent DTIs. While bivalirudin has a much lower affinity to thrombin than other hirudin derivatives, it has a greater affinity than univalent DTIs. This is demonstrated in the relationship between APTT and PT for these agents as demonstrated in Figures 1 and 2. DTIs with greater affinity for thrombin in general prolong the APTT at lower concentrations. Bivalirudin is a synthetic 20-amino acid peptide ($C_{98}H_{138}N_{24}O_{33}$). It has a molecular weight of 2180.19 Daltons, and is administered intravenously. The lyophilized powder is reconstituted with water, can be used for up to 24 h, and should be stored at 2-8° C [14]. Bivalirudin has three main parts—namely the NH_2 terminal sequence which binds to the thrombin active site, the anion binding $COOH$ -terminal sequence, and the tetraglycyl spacer that links both these terminal sequences [14].

During PCI: In a multicenter, open-label, prospective study [15] the use of bivalirudin at the time of PCI in patients with HIT with or without thrombosis was evaluated. Fifty-two patients were enrolled and divided into two groups based on the dosing of bivalirudin. The high dose group received a 1 mg/kg bolus followed by 2.5 mg/kg/h infusion for 4 h. The low dose group received a 0.75 mg/kg bolus followed by 1.75 mg/kg/h infusion. The procedural success rate defined as TIMI 3 flow through the stented vessel, and <50% residual stenosis was 98%, and the clinical success rate defined as the absence of death, emergent CABG, and absence of Q wave infarction was 96%. One

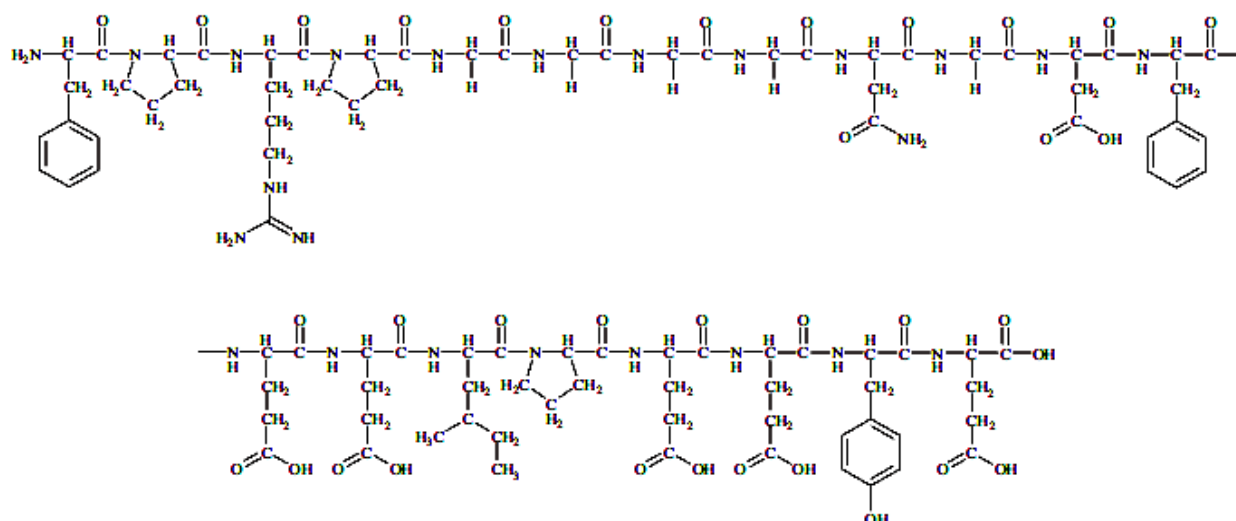


Figure 1: Chemical structure of bivalirudin [14].

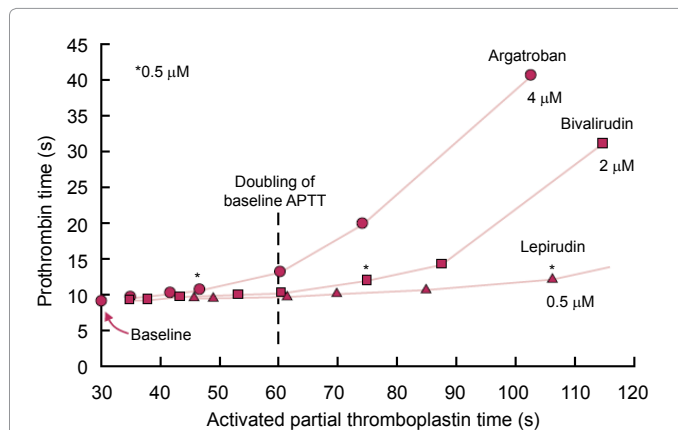


Figure 2: Prothrombin time (PT)-activated partial thromboplastin time (APTT) relationship for three direct thrombin inhibitors (DTIs). Prothrombin time (PT)-activated partial thromboplastin time (APTT) relationship for three direct thrombin inhibitors (DTIs). Data points shown are for serial two-fold dilutions of DTI. The increase in PT (for a given APTT) depends upon the DTI, and is greatest for argatroban, intermediate for bivalirudin, and least for lepirudin. The asterisk (*) indicates 0.5 mM concentration (final) of the DTI. [The international normalized ratio (INR) corresponding to the highest plotted PT-APTT data point for each DTI is: Argatroban, INR $\frac{1}{4}$ 4.40; bivalirudin, INR $\frac{1}{4}$ 3.38; lepirudin, INR $\frac{1}{4}$ 1.32]. The data were obtained using: (a) A recombinant human tissue factor [Innovin, Dade Behring, Mississauga, ON, USA; instrument-specific international sensitivity index (ISI) $\frac{1}{4}$ 1.0]; (b) Hemoliance Thrombosil IL (Instrumentation Laboratories, Lexington, MA, USA); (c) An STACompact (Diagnostica Stago, Asnieres, France); and (d) Pooled normal human plasma [13].

patient in the low dose group suffered a cardiac arrest and died after an uncomplicated PCI. One patient in the high dose group experienced major bleeding, and 7 others experienced minor bleeding.

During CABG: The management of anticoagulation of HIT patients requiring CABG can be extremely challenging. Prior to the widespread use of bivalirudin, alternative anticoagulant strategies were devised with no formal guidelines endorsing the same [16-18]. Some of the strategies include administration of DTI such as lepirudin and avoidance of heparin altogether. The problem with lepirudin is the high risk for anaphylaxis, difficulty with monitoring, as no rapid tests are available to monitor its effect, lack of an antidote and extensive renal elimination, which contraindicates its use in renal insufficiency. Another strategy entails the use of heparin with a potent Glycoprotein IIa/IIIb (GPIIa/IIIb) inhibitor, which is complicated by a higher risk for bleeding. There have been studies looking at the use of prostaglandins such as ileoprost with heparin in this setting to prevent the formation of heparin-associated antibodies; however, the risk for hypotension with the use of prostaglandins is quite high. Given all of the above, prospective studies looking the feasibility and safety of bivalirudin in CABG were performed [19,20]. In one study, forty-six of the forty-nine patients who underwent CABG had procedural success (94%), and forty-one patients received blood product transfusion prior to discharge with a mean of $5.6 + 3.8$ units of red blood cells, which was within normal limits for the institutions standard. In patients, undergoing off pump CABG the efficacy and safety of bivalirudin was established with a high procedural success rates and within normal ranges of acceptable bleeding [20].

Dosing, pharmacokinetics, and safety of Bivalirudin: Bivalirudin has shorter half-life (25 min) compared to other DTIs, and is predominantly eliminated renally. The dosage should be adjusted to achieve a target activated partial thromboplastin time (aPTT) of 1.5-2.5 times the baseline. The recommended dose for patients with HIT

undergoing PCI is a bolus of 0.75 mg/kg, followed by an infusion of 1.75 mg/kg/h for the duration of the procedure [21]. Bivalirudin plasma clearance is reduced 20% in patients with renal insufficiency, which necessitates a dose reduction in these patients. While the bolus dose remains the same in patients with renal disease, the infusion dose should be decreased based on the creatinine clearance (CrCl). Patients with moderate renal insufficiency (CrCl 30-59 ml/min) should receive an infusion of 1.75 mg/kg/h, in patients with CrCl <30 ml/min, the rate should be reduced to 1 mg/kg/h. Patients on hemodialysis should receive an infusion rate of 0.25 mg/kg/h [21].

Use of Argatroban in HIT

Chemistry: Argatroban is a univalent DTI, with a short half-life of 39-51 min [22]. It is synthetically derived from L-arginine. The molecular formula for argatroban is $C_{23}H_{36}N_6O_5S \cdot H_2O$ and it has a molecular weight of 526.66 [23]. Argatroban inhibits thrombin from cleaving fibrinogen, and factor XIII. It binds tightly to thrombin in an area close to, but distinct from its active site. Argatroban can inhibit thrombin bound to fibrin, and can inhibit aggregation of platelets. This drug is administered intravenously, and steady state is achieved within 1-3 h [23]. It is metabolized predominantly in the liver making it an attractive alternative in HIT patients with renal insufficiency. The dose should be decreased to 0.5 mcg/kg/min in patients with hepatic impairment with frequent aPTT monitoring. Lewis et al. [24], studied pooled data from three prospective trials assessing outcomes with the use of argatroban in HIT patients undergoing PCI. Ninety-one patients undergoing 112 PCIs were included in the study. The activated clotting time (ACT) was maintained between 300-450 seconds and the use of GP IIa/IIIb inhibitors was minimized. The procedural success rate was 95%, adequate intraprocedural anticoagulation was achieved in around 98% of patients, 98% of patients were free from death, myocardial infarction, and emergent CABG (secondary end-points). There was a very low rate of major bleeding (1.1%).

Lepirudin in patients with HIT

Lepirudin is a potent DTI, which does not demonstrate cross reactivity with HIT antibodies. It is a recombinant form of naturally occurring hirudin. Lepirudin has a relatively larger size (approximately 7000 Daltons) and anti-recombinant hirudin antibodies can form against lepirudin as it is made up of non-human protein. It is predominantly excreted renally, and the half-life can be prolonged for up to two days with renal dysfunction. Lepirudin can induce the production of IgG antibodies (anti-hirudin IgG), which can further enhance the anticoagulatory effect [23]. Laubenthal et al. [25], describe a case of HIT in a 71-year-old male following CABG, resulting in early occlusion of all his saphenous venous grafts (SVG). He subsequently received stents to his RCA, with acute stent thrombosis four days after PCI. The patient was successfully treated with a combination of lepirudin and abciximab. In a case series of nine patients treated with a combination of lepirudin and a GPIIb/IIIa inhibitor, all except one patient were free of thrombotic complications. Of note, the one patient who did have thrombosis also had positive anticardiolipin antibodies. Pinto et al. [26] studied twenty-five patients with HIT undergoing PCI treated with lepirudin, with a majority of the patients also on GPIIa/IIIb inhibitors. Overall mortality in this cohort was around 4% (cardiac and non-cardiac mortality). There were three deaths in the cohort, one due to hemorrhagic shock from retroperitoneal hemorrhage, the others due to sepsis and disseminated intravascular coagulation. All of these patients were on the combination of lepirudin and GPIIa/IIIb inhibitor. There were no thrombotic complications reported in this series. Given that we do not have larger prospective trials evaluating

the safety and efficacy of lepirudin, optimal dosing regimens have not been established.

Newer Anticoagulants (NOAC) in patients with HIT

Dabigatran is an oral direct thrombin inhibitor, and rivaroxaban, apixaban, and edoxaban are Factor Xa inhibitors. Based on their structure and mechanism of action, they do not cross react with PF4 and can potentially be used in HIT patients [27]. There have been case reports [28,29] describing the use of dabigatran in patients with HIT with and without thrombosis. Fieland and Taylor [30] reported a case of a 70-year-old male who underwent CABG, and had post-operative atrial fibrillation requiring anticoagulation. He developed HIT in the post-operative period and was started on dabigatran. The patient had an uneventful post op period, with recovery of his platelet count and no thrombotic events. Case reports describing the use of rivaroxaban in patients with HIT with and without venous thrombosis have been described with good platelet count recovery, no increase in major bleeding and no increase in the incidence of thrombosis [31-33]. Results in these case reports suggest that these NOACs may be used safely for outpatient therapy in patients with HIT, but randomized prospective controlled studies are currently lacking.

Outcomes with anti-platelet therapy and dual anti-platelet therapy in HIT

HIT antibodies stimulate the release of Adenosine Diphosphate (ADP), which is a platelet activator. Theoretically, ADP receptor blockers such as clopidogrel and ticlopidine should inhibit platelet activation, and this has been observed with ticlopidine [34]. However, case reports describing the occurrence of HIT following CABG in one case, and PCI in another while both patients were on aspirin and clopidogrel have been described³⁴. The reasons for this were thought to include incomplete (30-40% of maximum) ADP inhibition by clopidogrel. Additionally, the authors note that concomitant treatment with atorvastatin can decrease clopidogrel mediated ADP receptor blockade, as has been reported in a separate study [35]. This data suggests that HIT patients who undergo stenting may not receive the same protection from dual antiplatelet therapy in preventing stent thrombosis. It is understood that patients with HIT are at an increased risk for stent thrombosis. Whether the newer and more potent antiplatelet drugs such as ticagrelor or prasugrel should be preferred agents for use instead of clopidogrel is not yet clear. Statins, widely prescribed for CAD patients, may reduce the active form of clopidogrel by competitive inhibition of cytochrome P450³⁵. This interaction might not be significant in normal individuals, but in patients with HIT, increased ADP activation and subsequent platelet activation can play a detrimental role. Walenga et al. [36], describe the use of a GPIIb/IIIa inhibitor in combination with a direct thrombin inhibitor (reduced dosage) in three patients with HIT. The authors used r-hirudin plus tirofiban or argatroban plus abciximab and found no increase in major bleeding or thrombotic complications. This was a case series involving only three patients and larger prospective studies are needed to prove the safety and efficacy of this regimen. Koster et al. [37], studied the use

of tirofiban (GP IIb/IIIa inhibitor) in patients with HIT undergoing CABG. Tirofiban was infused 10 min prior to administration of UFH, and the authors found no thrombotic complications during heparinization during or after the surgery. Platelet transfusion was required in three patients with severe pre-operative thrombocytopenia. Blood transfusion requirements were within institutional standards in this study. There was no post-operative hemorrhage requiring re-exploration. There have been cases of thrombocytopenia reported with the use of GPIIa/IIIB inhibitors [38], and although a majority of these cases is asymptomatic, profound thrombocytopenia and major bleeding have been reported. In the setting of significant thrombocytopenia during treatment with heparin and a GPIIa/IIIB inhibitor, both drugs should be discontinued and supportive therapy initiated along with diagnostic testing for HIT antibodies.

CABG and HIT

Liu et al. [39], studied bypass graft patency in 18 patients who underwent CABG and were diagnosed with HIT in the first two weeks after surgery. Graft patency rates in these patients were compared to post-operative CABG patients without HIT. The authors angiographically studied 47 saphenous venous grafts (SVG) and 14 internal mammary artery (IMA) grafts and found that 62% of the SVGs (29/47) were occluded and only one IMA graft was occluded. They also found that 14 of the 18 patients (80%) with HIT had more than one SVG occluded. Ten patients developed non-cardiac arterial and venous thrombi in addition. In post CABG patients without HIT, 35 SVGs and 17 IMA grafts were studied, and of these 7/35 SVGs (20%) and 2/17 IMA grafts were found to be occluded in the first 6 months after bypass. The incidence of thrombotic SVG occlusion after CABG is high, and a low threshold for performing angiography in HIT patients post CABG who present with chest pain/ACS is warranted to evaluate for graft occlusion. There have been studies [40,41] looking at the incidence of HIT following CABG and vascular surgery procedures. Bauer et al. [40], studied plasma from 111 patients before and after CABG for HIT antibodies and found that 51% of the patients tested positive for these antibodies with EIA. None of these patients had thrombotic events or thrombocytopenia. On the other hand, Jackson et al. [41], tested patients undergoing vascular surgery before and after the procedure for HIT antibodies and noted that only one patient converted from a negative HIT antibody status to a positive one.

Strategies during PCI

Without large prospective studies and clear-cut guidelines recommendations for anticoagulation, anti-platelet therapy is based on expert consensus and smaller studies. Discontinuation of heparin products followed by alternative anticoagulation such as bivalirudin or argatroban during PCI is recommended based on the small prospective trials mentioned above. In addition, there has been a major shift to transradial approach in coronary angiography in the last few years. Radial Artery Occlusion (RAO) is one of the complications of the transradial approach the incidence of which ranges from 2-18% [42-44]. Some of the factors contributing to RAO

Strategies during percutaneous coronary intervention (PCI) in patients with heparin induced thrombocytopenia (HIT)

1. Discontinue all heparin products, including heparinized saline.
2. Alternative anticoagulant such as bivalirudin. Argatroban can also be used particularly in patients with renal insufficiency [4,8].
3. 'Radial cocktail' for transradial angiography given without heparin. Instead intravenous bivalirudin given at standard dose, with vasodilator/s given intra-arterial.
4. Additional strategies such as using a smaller sheath size, sheathless guide catheter, avoiding prolonged radial artery compression, prophylactic ipsilateral ulnar artery compression and patent hemostasis etc can be used to minimize spasm.
5. Dual antiplatelet therapy after PCI as per current guidelines [13].
6. In patients with HIT and thrombosis, short term or extended oral anticoagulation can be considered. Either warfarin or a newer oral anticoagulant are options [24].

Table 3: Strategies during percutaneous coronary intervention (PCI) in patients with heparin induced thrombocytopenia (HIT).

include no anticoagulant use, small radial artery to sheath ratio, and prolonged high-pressure compression of the radial artery. Studies have indicated thrombus formation as a factor precipitating RAO, which is why adequate anticoagulation during angiography is necessary [45]. During transradial angiography, a “radial cocktail” of medications is usually administered, which usually includes vasodilators such as verapamil, nitroglycerin and/or nicardipine in combination with heparin. Spaulding et al. [45] studied rates of RAO with different doses of heparin and found rates of 70%, 24%, and 4.3% in groups without heparin, 2000-3000 IU heparin and 5000 IU of heparin, respectively. Heparin (50 IU/kg up to a maximum dose of 5000 IU) is the usual dose at most centers. Pancholy et al. [46], compared the use of intra-arterial versus intravenous use of heparin during transradial angiography and found no difference in the incidence of RAO. Plante et al. [47], studied 400 patients undergoing diagnostic angiography who received intravenous heparin (70 IU/kg) just before radial sheath removal, compared with patients receiving standard doses of bivalirudin (half of the patients required PCI) and found no difference in RAO. Although there are no direct comparisons between intravenous bivalirudin and intra-arterial heparin administration and the incidence of RAO, the fact that there was no difference in the incidence of RAO with intravenous vs. intra-arterial heparin or between intravenous heparin and bivalirudin, administration of standard dose bivalirudin during diagnostic angiography is a feasible option. There are no clear guidelines or prospective trials regarding optimal DAPT in HIT patients. Current American College of Cardiology/American Heart Association (ACC/AHA) guidelines provide a Class I recommendation for the use of aspirin plus a P2Y₁₂ inhibitor (clopidogrel or ticagrelor) in acute coronary syndrome [48] and a Class IIa indication for choosing ticagrelor over clopidogrel based on the PLATO trial⁴⁸. Currently there are no prospective studies comparing different P2Y₁₂ inhibitors in HIT patients. Clopidogrel provides incomplete inhibition of ADP, and when used along with statins might not be as effective in HIT patients as in the general population. In patients with severe HIT, with current or previous thrombosis and/or stent thrombosis, use of the newer P2Y₁₂ inhibitors like ticagrelor or prasugrel may be warranted given better outcomes compared to clopidogrel in the general population (Table 3).

Conclusion

HIT though rare, can have devastating consequences in the form of thrombotic complications. The management of patients with HIT undergoing PCI and/or CABG can be challenging due to increased rates of stent thrombosis and graft occlusion. Immediate cessation of all heparin products and initiation of alternative anticoagulation is recommended. DTI such as bivalirudin and argatroban are the mainstay of therapy during PCI and CABG, followed by oral warfarin for few weeks to 3 months or longer after the diagnosis of HIT. There are no specific studies or guidelines addressing anti-platelet therapy after coronary stenting in HIT patients, and currently DAPT protocols similar to that used in the general population is recommended. Further studies are warranted to determine appropriate DAPT therapy, and the safety and efficacy of various anticoagulants. Designing and successfully completing such a study may be difficult due to the frequency of this diagnosis and the variable clinical presentation.

References

- Linkins LA, Dans AL, Moores LK, Bona R, Davidson BL, et al. (2012) Treatment and prevention of heparin-induced thrombocytopenia: Antithrombotic Therapy and Prevention of Thrombosis (9th edn.) American College of Chest Physicians Evidence-Based Clinical Practice Guidelines. *Chest* 141: e495S-530S.
- Ananthasubramaniam K, Shurafa M, Prasad A (2000) Heparin-induced thrombocytopenia and thrombosis. *Cardiovasc Dis* 42: 247-260.
- Kelton JG, Smith JW, Warkentin TE, Hayward CP, Denomme GA, et al. (1994) Immunoglobulin G from patients with heparin-induced thrombocytopenia binds to a complex of heparin and platelet factor 4. *Blood* 83: 3232-3239.
- Brieger DB, Mak KH, Kottke MK, Topol EJ (1998) Heparin-induced thrombocytopenia. *J Am Coll Cardiol* 31: 1449-1459.
- Krzych LJ, Nowacka E, Knapik P (2014) Heparin-induced thrombocytopenia. *Anesthesiology Intensive Therapy* 47: 63-76.
- Hussain F, Philipp R, Zieroth S (2009) HIT and stent thrombosis: a “clinical” diagnosis not to be missed. *Int J Cardiol* 133: e11-e13.
- Shin HW, Yoon HJ, Choi SW, Bae HJ, Sohn JH, et al. (2012) Acute stent thrombosis and heparin induced thrombocytopenia in a patient with ST-segment elevation myocardial infarction. *Korean Circ J* 42: 646-649.
- Cruz D, Karlsberg R, Takano Y, Vora D, Tobis J (2003) Subacute stent thrombosis associated with a heparin-coated stent and heparin-induced thrombocytopenia. *Catheterization and Cardiovascular Interventions* 58: 80-83.
- Dardas PS, Tsikaderis DD, Theofilogiannakos EK, Spyrou AN, Mezilis NE, et al (2013) Bi-ostial coronary thrombosis due to heparin induced thrombocytopenia. *Int J Cardiol* 162: e36-e38.
- Gallagher MJ, Ajluni SC, Almany S (2005) Coronary Artery Stent Thrombosis Associated with Heparin-Induced Thrombocytopenia: Case Report and Review of the Literature. *J Int Cardiol* 18: 131-137.
- Matsuo T, Suzuki S, Matsuo M, Kobayashi H (2005) Preexisting antibodies to platelet factor 4-heparin complexes in patients with acute coronary syndrome who have no history of heparin exposure. *Pathophysiol Haemost Thromb* 34: 18-22.
- Rota E, Bazzan M, Fantino G (2008) Fondaparinux-related thrombocytopenia in a previous low-molecular-weight heparin (LMWH)-induced heparin-induced thrombocytopenia (HIT). *Thromb Haemost* 99: 779-781.
- Warkentin TE (2004) Bivalent direct thrombin inhibitors: hirudin and bivalirudin. *Best Pract Res Clin Haematol* 17: 105-25.
- Shammas NW (2005) Bivalirudin: pharmacology and clinical applications. *Cardiovasc Drug Rev* 23: 345-360.
- Mahaffey KW, Lewis BE, Wildermann NM, Berkowitz SD, Oliverio RM, et al. (2003) The anticoagulant therapy with bivalirudin to assist in the performance of percutaneous coronary intervention in patients with heparin-induced thrombocytopenia (ATBAT) study: main results. *J Invas Cardiol* 15: 611-616.
- Koster A, Meyer O, Fischer T (2001) One-year experience with the platelet glycoprotein IIb/IIIa antagonist tirofiban and heparin during cardiopulmonary bypass in patients with heparin-induced thrombocytopenia type II. *J Thorac Cardiovasc Surg* 122: 1254-1255.
- Palatianos GM, Foroulis CN, Vassili MI (2004) Preoperative detection and management of immune heparin-induced thrombocytopenia in patients undergoing heart surgery with iloprost. *J Thorac Cardiovasc Surg* 127: 548-554.
- Poetzsch B, Klövekorn WP, Madlener K (2000) Use of heparin during cardiopulmonary bypass in patients with a history of heparin-induced thrombocytopenia. *N Engl J Med* 343: 515.
- Koster A, Dyke CM, Aldea G, Smedira NG, McCarthy HL, et al. (2007) Bivalirudin during cardiopulmonary bypass in patients with previous or acute heparin-induced thrombocytopenia and heparin antibodies: results of the CHOOSE-ON trial. *Ann Thorac Surg* 83: 572-577.
- Dyke CM, Aldea G, Koster A, Smedira N, Avery E, et al. (2007) Off-pump coronary artery bypass with bivalirudin for patients with heparin-induced thrombocytopenia or antiplatelet factor four/heparin antibodies. *Thorac Surg* 84: 836-839.
- Serebruany MV, Malinin AI, Serebruany VL (2006) Argatroban, a direct thrombin inhibitor for heparin-induced thrombocytopenia: present and future perspectives. *Expert Opin on Pharmacotherapy* 7: 81-89.
- www.accessdata.fda.gov/drugsatfda_docs/label/2016/020873s0361bl.pdf
- Nikolsky E, Dangas GD (2004) Percutaneous interventions in patients with immune-mediated heparin-induced thrombocytopenia. In *Seminars in Thrombosis and Hemostasis* 30: 305-314.
- Lewis BE, Matthai WH, Cohen M, Moses JW, Hursting MJ, et al. (2002) ARG-216/310/311 Study Investigators. Argatroban anticoagulation during percutaneous coronary intervention in patients with heparin-induced thrombocytopenia. *Catheter Cardiovasc Interv* 57: 177-184.

25. Laubenthal FC, Grosch B, Szurawitzki G, Sabin GV (1999) Heparin-induced thrombocytopenia type II with early aortocoronary bypass occlusion and stent thrombosis after PTCA of the RCA-treatment with lepirudin (Refludan) and abciximab (Reopro) during recanalization of the RCA [in German]. *Z Kardiol* 88: 141-146.
26. Pinto DS, Sperling RT, Tu TM, Cohen DJ, Carrozza JP (2003) Combination platelet glycoprotein IIb/IIIa receptor and lepirudin administration during percutaneous coronary intervention in patients with heparin-induced thrombocytopenia. *Catheter Cardiovasc Interv* 58: 65-68.
27. Skelley JW, Kyle JA, Roberts RA (2016) Novel oral anticoagulants for heparin-induced thrombocytopenia. *J Thromb Thrombol* 42: 172-178.
28. Mirdamadi A (2013) Dabigatran, a direct thrombin inhibitor, can be a life-saving treatment in heparin-induced thrombocytopenia. *ARYA Artheroscler* 9: 112-114.
29. Sharifi M, Bay C, Vajo Z, Freeman W, Sharifi M, et al. (2015) New oral anticoagulants in the treatment of heparin-induced thrombocytopenia. *Thromb Res* 135: 607-609.
30. Fieland D, Taylor M (2012) Dabigatran use in a postoperative coronary artery bypass surgery patient with nonvalvular atrial fibrillation and heparin-PF4 antibodies. *Ann Pharmacother* 46: e46.
31. Ng H, Than H, Teo E (2015) First experiences with the use of rivaroxaban in the treatment of heparin-induced thrombocytopenia. *Thromb Res* 135: 205-207.
32. Tardy PB, Piot M, Montmartin A, Burdier A, Chalayer E, et al. (2015) Delayed-onset heparin-induced thrombocytopenia without thrombosis in a patient receiving postoperative thromboprophylaxis with rivaroxaban. *Thromb Haemost* 114: 652-654.
33. Sharifi M, Freeman W, Bay C, Sharifi M, Breed C, et al. (2014) Treatment of heparin-induced thrombocytopenia with new oral anticoagulants. *J Am Coll Cardiol* 63: A2096.
34. Selleng K, Selleng S, Raschke R, Schmidt CO, Rosenblood GS, et al. (2005) Immune heparin-induced thrombocytopenia can occur in patients receiving clopidogrel and aspirin. *Am J Hematol* 78: 188-192.
35. Lau WC, Waskell LA, Watkins PB (2003) Atorvastatin reduces the ability of clopidogrel to inhibit platelet aggregation. A new drug-drug interaction. *Circulation* 107: 32-37.
36. Walenga JM, Jeske WP, Wallis DE, Bakhos M, Lewis BE, et al. (1998) Clinical experience with combined treatment of thrombin inhibitors and GPIIb/IIIa inhibitors in patients with HIT. In *Seminars in Thrombosis and Hemostasis*. Europe PMC 25: 77-81.
37. Koster A, Meyer O, Fischer T, Kukuckaa M, Krabatsch T, et al. (2001) One-year experience with the platelet glycoprotein IIb/IIIa antagonist tirofiban and heparin during cardiopulmonary bypass in patients with heparin-induced thrombocytopenia type II. *J Thoracic Cardiovas Surg* 122: 1254-1255.
38. Said SM, Hahn J, Müller M, Fiedler GM, Prondzinsky R (2007) Glycoprotein IIb/IIIa inhibitor-induced thrombocytopenia. *Clinical Research in Cardiology* 96: 61-69.
39. Liu JC, Lewis BE, Steen LH, Grassman ED, Bakhos M, et al. (2002) Patency of coronary artery bypass grafts in patients with heparin-induced thrombocytopenia. *Am J Cardiol* 89: 979-981.
40. Bauer TL, Arepally G, Konkle BA (1997) Prevalence of heparin-associated antibodies without thrombosis in patients undergoing cardiopulmonary bypass surgery. *Circulation* 1995: 1242-1246.
41. Jackson MR, Gillespie DL, Chang AS (1998) The incidence of heparin-induced antibodies in patients undergoing vascular surgery: A prospective study. *J Vasc Surg* 28: 439-445.
42. Stella PR, Kiemeneij F, Laarman GJ, Odekerken D, Slagboom T, et al. (1997) Incidence and outcome of radial artery occlusion following transradial artery coronary angioplasty. *Cathet Cardiovasc Diagn* 40: 156-158.
43. Nagai S, Abe S, Sato T, Hozawa K, Yuki K, et al. (1999) Ultrasonic assessment of vascular complications in coronary angiography and angioplasty after transradial approach. *Am J Cardiol* 83: 180-186.
44. Yoo BS, Lee SH, Ko JY, Lee BK, Kim SN, et al. (2003) Procedural outcomes of repeated transradial coronary procedure. *Catheter Cardiovasc Interv* 58: 301-304.
45. Spaulding C, Lefèvre T, Funck F, Thébault B, Chauveau M, et al. (1996) Left radial approach for coronary angiography: results of a prospective study. *Cathet Cardiovasc Diagn* 39: 365-370.
46. Pancholy SB (2007) Transradial access in an occluded radial artery: new technique. *J Invasive Cardiol* 19: 541-544.
47. Plante S, Cantor WJ, Goldman L, Miner S, Quesnelle A, et al. (2010) Comparison of bivalirudin versus heparin on radial artery occlusion after transradial catheterization. *Catheter Cardiovasc Interv* 76: 654-658.
48. Amsterdam EA, Wenger NK, Brindis RG, Casey DE, Ganiats TG, et al. (2014) AHA/ACC guideline for the management of patients with non-ST-elevation acute coronary syndromes: a report of the American College of Cardiology/American Heart Association Task Force on Practice Guidelines. *J Am Coll Cardiol* 64: e139-228.