

Orthodontic and Surgical Treatment in an Inverted Maxillary Impacted Central Incisor: A Case Report

Thang Phu Nguyen^{1*} and Khanh Nguyen Le Ngoc²

¹Head of Oral Surgery Department, School of Odonto-Stomatology, Hanoi Medical University, no.1 Ton That Tung street, Hanoi, Vietnam

²Orthodontics Department, National Hospital of Odonto - Stomatology, no. 40 Trangthi, Hanoi, Vietnam

*Corresponding author: Dr. Thang Phu Nguyen, DDS, PhD, Head of Oral Surgery Department, School of Odonto-Stomatology, Hanoi Medical University, no.1 Ton That Tung street, Hanoi, Vietnam, Tel: 84913581394; E-mail: phuthangdentist@gmail.com

Received date: August 24, 2017; Accepted date: September 05, 2017; Published date: September 12, 2017

Copyright: © 2017 Nguyen TP. This is an open-access article distributed under the terms of the Creative Commons Attribution License, which permits unrestricted use, distribution, and reproduction in any medium, provided the original author and source are credited.

Abstract

A 13-year-old boy was referred to the oral surgery department with the chief complaint of non-eruption of the permanent maxillary left incisor. The anterior traumatic history of the patient was unremarkable. A clinical examination revealed the presence of an inverted impacted incisor in the vestibular. A radiographic examination, CT Scanner evaluated accurately the position, morphology and adjacent structures. The findings showed the necessity for an interdisciplinary approach between the orthodontist and oral surgeons to address the patient's issue.

Keywords Oral surgery; Maxillary; Dental pathology; Facial aesthetics

Introduction

Inversion of the impacted tooth has not been presented frequently in clinical practice. Of those, only a few cases of the impaction of the maxillary central incisor have been reported in the literature [1]. It is worth notice that the complication of this may vary from facial aesthetics to dental pathology such as dentigerous cyst [2,3]. Hence, various authors claimed that the condition could be less complicated when whole scenarios found at the early stage [4-6].

The treatment for this state may be surgical removal followed by bridge or implant. Another approach is surgical exposure and orthodontic traction of the impacted incisor into desirable position [7,8]. Although the possible treatment plans depend on patient's wishes, findings and practitioner skills, the latter is more likely to be a preferable way to achieve a natural and healthy smile. Therefore, the purpose of this case report is to review this attractive management of the uncommon case.

Case Report

A 13-year-old boy was referred to our department with the chief complaint of the un-erupted maxillary central incisor. The medical and dental history showed no previous trauma.

Intra orally, the examination indicated that the permanent left central incisor was not present in the maxillary with no past history of

the incorrect extraction. However, there was not either palatal or buccal gingival swelling in the related region (Figures 1 and 2).

A Panoramic and Cephalometric radiograph revealed an impacted inversion of an upper left central incisor in the vestibular (Figure 3). In the meantime, maxillary braces had been applied for 6 months to align all the teeth and gain the gap for the impacted tooth (Figure 4).

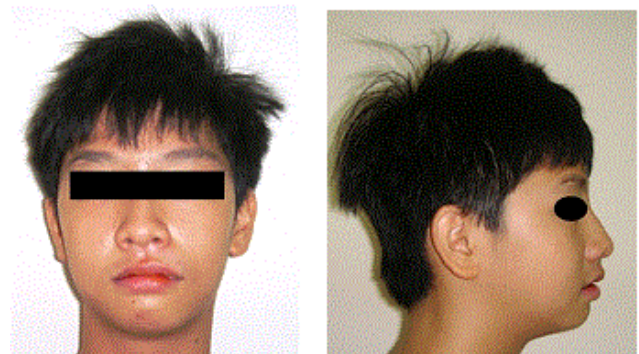

Figure 1: Extra oral images showed asymmetry face and incompetent lip.

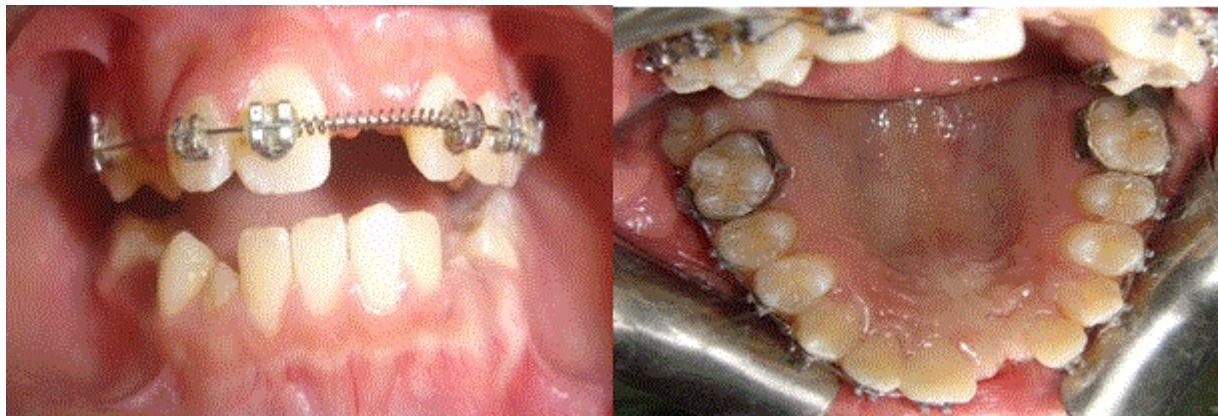


Figure 2: Intra oral examination revealed the upper left central incisor was not present.

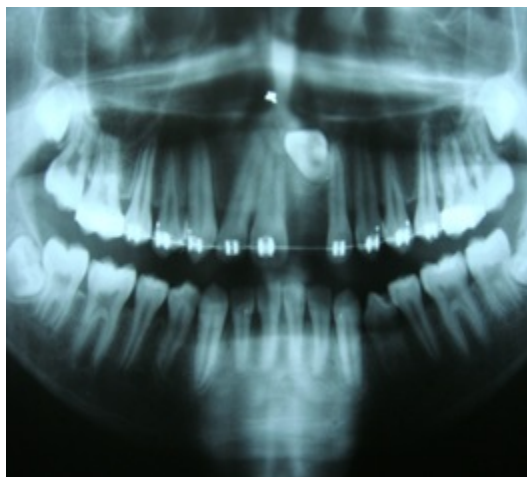

Figure 3: An impacted and inverted Maxillary central incisor was found in the Panoramic and Cephalometric radiograph with the tooth crown facing the floor of the nose while the root was orienting the alveolar process.

In addition to the last investigations, we also needed an additional image of Computer Tomography (CT) to obtain accurately the tooth position in order to make an optimal approach. As showed in Figure 5, the tooth crown was close to the floor of the nose; and thus, a small hole which was 1 mm away from the incisor edge was made by using 0.25 mm diamond round bur when surgical exposure procedure performed.

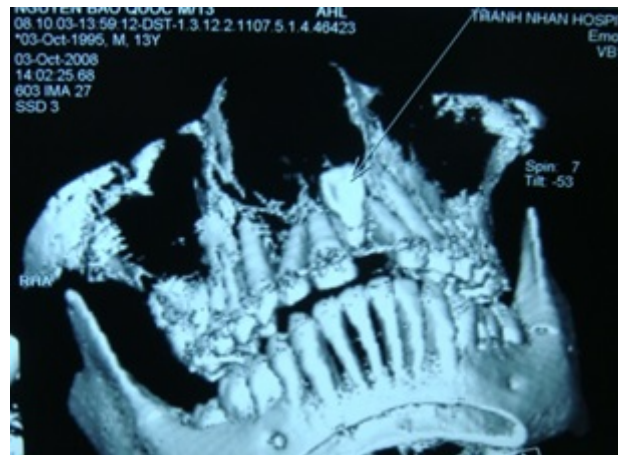

Figure 4: Sufficient space for the impacted had been created by applying braces for 6 months.

This technique would be beneficial to support bonding attachment on the impacted incisor when the distance of orthodontic traction was far from the prepared position (Figures 5 and 6). Another reason was related to isolation of the impacted tooth. The button was hardly attached on the crown as it was not straightforward to control bleeding and saliva surrounding the deep cervical.

Two months later, the maxillary impacted incisor was partially present in the vestibular (Figure 7). One 2 × 6 mm miniscrew of Jeil was also inserted to correct the tooth position in the 3 dimension (Figure 8). By this way, the force was applied on the crown via ligature and elastic chain to turn the lingual surface to the palatal side.

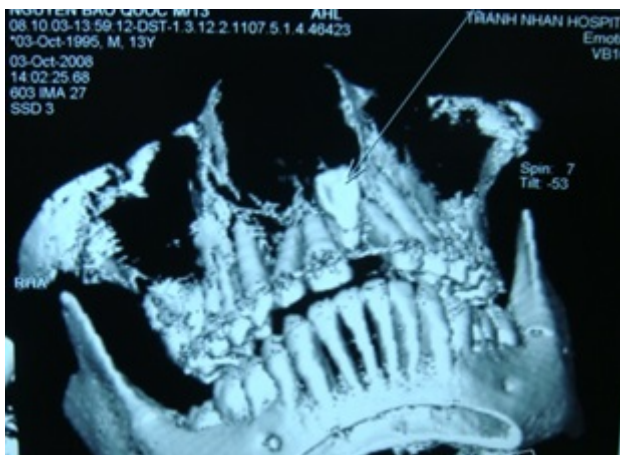


Figure 5: The CT image showed obviously an impacted and inverted upper anterior tooth compared to unclear position of the tooth in the Cephalometric radiograph in Figure 3.

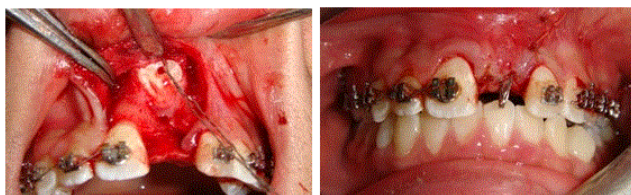


Figure 6: Surgical exposure and orthodontic traction, A) Impacted tooth was exposed and a hole was made to stabilize bonding attachment, B) Stainless steel wire 0.017 × 0.025 in was applied to allocate the non-eruption tooth to the correct position.

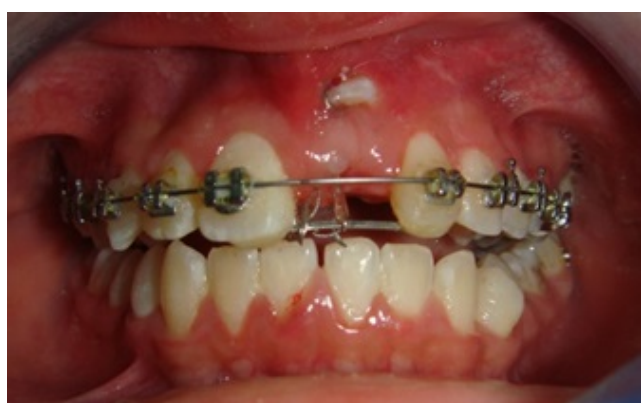

Figure 7: After two months, the incisor edge was visible in the buccal region.

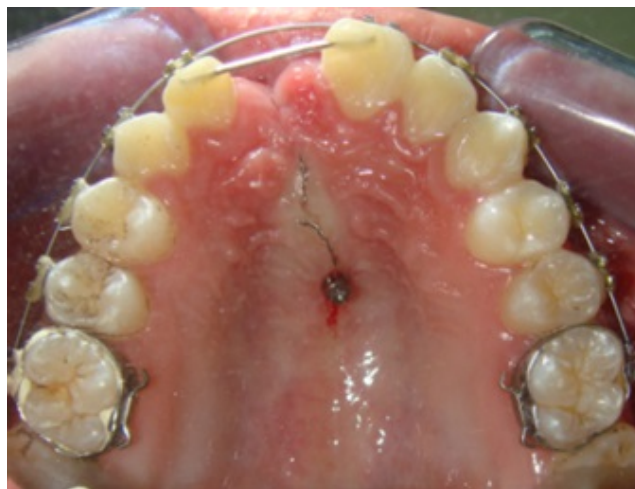

Figure 8: Miniscrew was prescribed in the palatal under local anaesthesia to obtain more supportive orthodontic force for this case after consent form was done.

Three months postoperative result was accepted by the patient and his parents although there was still an asymmetric gingival margin between two upper central incisors (Figure 9). This issue may be resolved by another periodontal surgery when the patient requires. Otherwise, there were no recorded complications concerning functional and esthetic features.

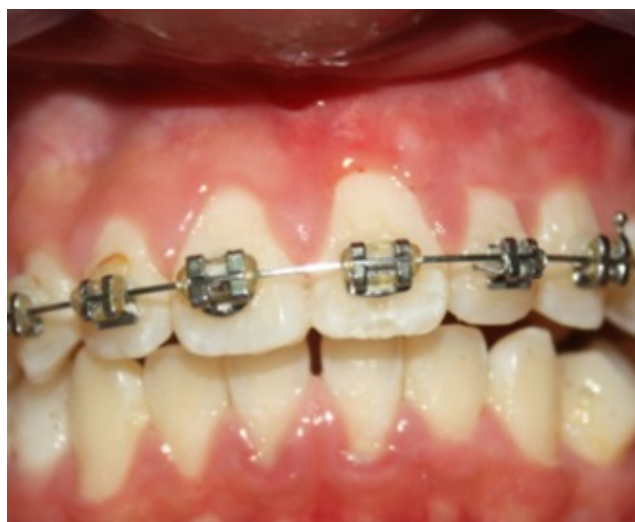

Figure 9: The impacted tooth was located into an expected position with well force control. The mild gingival recession was a probably inevitable complication as the long distance of tooth movement was performed.

Discussion

Numerous papers mentioned the impaction of third molars or canine [3-5,9], while the minority of impacted cases reported in lateral

incisors and central incisors. Of these, the presence of inverted central incisors is much less frequent compared to the other series [10]. In addition to this rate, only a few case reports indicated the solution for the circumstance based on similar situation in other sites [7,8,11,12].

The etiology of impacted maxillary incisors could be associated with hereditary and environmental factors [13-15]. Early findings may play a major role in the management of this situation [6] as most failures in the past were due to late treatment. When aligning the impacted teeth within the dental arch, the dilacerated root was completely developed or too long will reduce the success rate; and if the apex was not covered by labial osseous gingival and lamella result in fail to heal. Therefore, the present case was challenging by reason of the undesirable treatment time.

Other difficulties of the reported case could be its position and direction [7,16,17]. The location of anterior teeth will challenge the clinician to achieve both functional and esthetical factors. Moreover, the inverted tooth is one additional complication as the force control must be restricted to enable move the tooth into the correct position.

Regarding treatment plan, several techniques were developed as the treatment options to overcome those hassles. One of the easiest and fastest ways is combining tooth extraction and prosthodontic such as bridge. However, the alveolar bone in extraction area will be thinner and deficient following the healing period [7,13]. Because of that drawback, orthodontics traction co-operated with surgical exposure will act as the most acceptable approach for such impacted teeth.

In this case, the need for space was the first requirement. Only when all teeth aligned and sufficient space for the impacted tooth made, the followed surgical exposure would be carried out to apply attachment and insert miniscrew for bringing that tooth into right anatomical position. It should be bear in mind that preserving keratinized gingival or using an apical flap could provide an optimal outcome. This is due to the evidences that the "window" technique may cause significantly attachment loss, gingival recession and gingivitis [5,18,19].

Conclusions

Inverted impaction of central incisors is rare and challenging condition. The choice of treatment should be based on the patients' need, their state and clinicians' ability. In the case of the delayed eruption, orthodontic traction could be an ideal approach if there is enough space in the dental arch to accommodate. Intervention of an oral surgeon is necessary to provide the access for the orthodontic instruments.

References

1. Nuvvula S, Pavuluri C, Mohapatra A, Nirmala SVSG (2011) Atypical presentation of bilateral supplemental maxillary central incisors with unusual talon cusp. *J Indian Soc Pedod Prev Dent* 29: 149-154.
2. Lustmann J, Shear M (1985) Radicular cysts arising from deciduous teeth. *Int J Oral Surg* 14: 153-161.
3. Waite PD, Reynolds RR (1998) Surgical management of impacted third molars. *Semin Orthod* 4: 113-123.
4. Dalessandri D, Parrini S, Rubiano R, Gallone D, Migliorati M (2017) Impacted and transmigrant mandibular canines incidence, aetiology, and treatment: a systematic review. *Eur J Orthod* 39: 161-169.
5. Kuftinec MM, Shapira Y (1995) The impacted maxillary canine: I. Review of concepts. *ASDC J Dent Child* 62: 317-324.
6. Shi XR, Hu Z, Wang XZ, Sun XY, Zhang CY, et al. (2015) Evaluation of the Effect of the Closed-eruption Technique on Impacted Immature Maxillary Incisors. *Chin J Dent Res Off J Sci Sect Chin Stomatol Assoc CSA* 18: 111-115.
7. Kannan PKKPS, Palanisamy SKKP, Kumar TS (2012) A case of impacted maxillary central incisor and its management. *J Pharm Bioallied Sci* 4: S174-S176.
8. Pinho T, Neves M, Alves C (2011) Impacted maxillary central incisor: surgical exposure and orthodontic treatment. *Am J Orthod Dentofac Orthop Off Publ Am Assoc Orthod Its Const Soc Am Board Orthod* 140: 256-265.
9. Garib DG, Lancia M, Kato RM, Oliveira TM, Neves LT das (2016) Risk of developing palatally displaced canines in patients with early detectable dental anomalies: a retrospective cohort study. *J Appl Oral Sci Rev FOB* 24: 549-554.
10. Aitasalo K, Lehtinen R, Oksala E (1972) An orthopantomographic study of prevalence of impacted teeth. *Int J Oral Surg* 1: 117-120.
11. Jayam C, Bandlapalli A, Patel N, Choudhary RSK (2014) A case of impacted central incisor due to dentigerous cyst associated with impacted compound odontome. *BMJ Case Rep* 2014.
12. Das D, Misra J (2012) Surgical management of impacted incisors in associate with supernumerary teeth: a combine case report of spontaneous eruption and orthodontic extrusion. *J Indian Soc Pedod Prev Dent* 30: 329-332.
13. Nawaz M, Sivaraman GS, Santham K (2015) Surgical management of an inverted and impacted maxillary central incisor - case report. *J West Afr Coll Surg* 5: 84-89.
14. Becker A, Chaushu S (2015) Surgical Treatment of Impacted Canines: What the Orthodontist Would Like the Surgeon to Know. *Oral Maxillofac Surg Clin N Am* 27: 449-458.
15. Chu FCS, Li TKL, Lui VKB, Newsome PRH, Chow RLK, et al. (2003) Prevalence of impacted teeth and associated pathologies--a radiographic study of the Hong Kong Chinese population. *Hong Kong Med J Xianggang Yi Xue Za Zhi* 9: 158-163.
16. Brin I, Zilberman Y, Azaz B (1982) The unerupted maxillary central incisor: review of its etiology and treatment. *ASDC J Dent Child* 49: 352-356.
17. Lin YT (1999) Treatment of an impacted dilacerated maxillary central incisor. *Am J Orthod Dentofac Orthop Off Publ Am Assoc Orthod Its Const Soc Am Board Orthod* 115: 406-409.
18. Moss JP (1975) An orthodontic approach to surgical problems. *Am J Orthod* 68: 363-390.
19. Levin MP, D'Amico RA (1974) Flap design in exposing unerupted teeth. *Am J Orthod* 65: 419-422.