

Orbital Cholesterol Granuloma: A Case Report

Chantal Ngoune Nanfack¹*, Yannick Bilong^{2,3}, Yan Luo³, Yuanyuan Han⁴ and Lucienne Assumpta Bella¹

¹Ophthalmology Unit, Pediatric and Gynéco-Obstetric Hospital, Yaounde, Cameroon; ²Cameroon-China Fellow Program, Shanxi Eye Hospital, Shanxi, China; ³Department of Ophthalmology, University of Yaoundé I, Yaoundé, Cameroon; ⁴Orbit and Tumor Department, Shanxi Eye Hospital, Shanxi, China

Abstract

Orbital cholesterol granuloma is a rare entity with few cases described in the literature. We report the case of a 44 years old male presenting with a proptosis; an inferomedial displacement and motion limitation in upgaze of the left eye. The CT scan reveals an extraconal hypodense mass, frontal bone thinning and erosion infiltration of the zygoma. The management consists of the complete resection of the mass with curettage of the underlying bone cavity. The pathology shows cholesterol clefts; calcifications; and blood products degradation in between mononuclear cells and foamy macrophages and the absence of epithelial element thus confirming the diagnosis of cholesterol granuloma and ruling out dermoid cysts which is an important differential diagnosis

Keywords: Proptosis; Cholesterol granuloma; Orbit curettage

Introduction

Orbital cholesterol granuloma is a rare disease with very few cases reported in the literature worldwide [1-4]. Trauma has been pointed out to be an important factor for the occurrence of this tumor [1] and cholesterol granulomas develop as an inflammatory reaction to localized hemorrhages, often occurring within the frontal bone overlying the lacrimal fossa [2]. It is usually seen in young to middle-aged males [2,3]. The aim of this work is to share a case of orbital cholesterol granuloma which should be distinguished from dermoid cyst and cholesteatoma.

Case report

We present the case of a 44 years old male who consulted for progressive painless proptosis of left eye lasting for a year without a history of trauma. Ophthalmologic examination reveals in the left eye a proptosis of 25mm; an infero-medial displacement of the eyeball; limitation of eye movements in upgaze. The best corrected visual acuity; the anterior segment the fundus and the intraocular pressure were normal in both eyes. The computed tomography scan of left eye findings were: an extraconal supero-lateral hypodense mass measuring 35 mm × 28 mm × 25 mm;

frontal bone erosion with irregular border; infiltration of the zygoma bones (Figure 1).

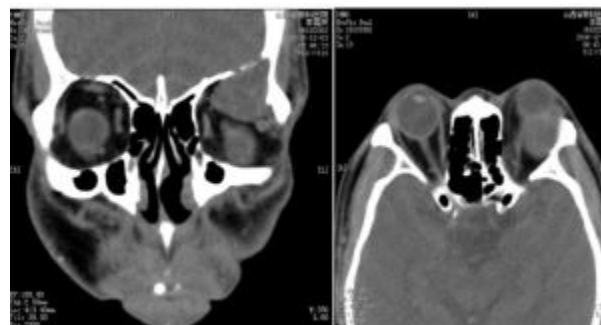

Figure 1: Orbit computed tomography scan of cholesterol granuloma.

The patient underwent surgery by a lateral orbitotomy approach through a Reese Berke and superior lid crease incision. The tumor was completely resected and curettage of the underlying bone cavity to prevent recurrence was performing. The histopathology reveals an inflammatory granulomatous reaction with cholesterol clefts; calcifications; blood products degradation in between mononuclear cells and foamy macrophages surrounded by hyperplasia fibro-cysts and the absence of

*Corresponding author: Nanfack CN, Ophthalmology unit, Pediatric and gynéco-obstetric hospital, Yaounde, Cameroon, Tel: 237 699878192; E-mail: cngoune2001@yahoo.fr

Received date: December 20, 2018; Accepted date: January 02, 2019; Published date: January 08, 2019

Citation: Nanfack C.N, Yannick B, Yan L, Yuanyuan H, Lucienne A. B (2019) Orbital Cholesterol Granuloma: A Case Report. J Tumor Res & Reports, 4: 123

Copyright: © 2018 Nanfack CN. This is an open-access article distributed under the terms of the creative commons attribution license, which permits unrestricted use, distribution, and reproduction in any medium, provided the original author and source are credited.

epithelial cells which are pathognomonic of orbital cholesterol granuloma (Figure 2). The outcome after 14 months follow up is favorable with the absence of recurrences.

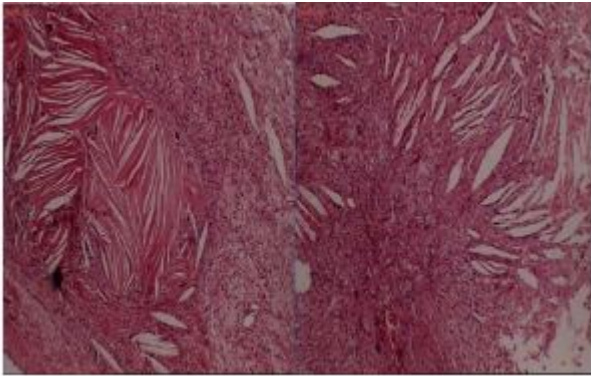


Figure 2: Histology findings of cholesterol granuloma.

Discussion

Orbital cholesterol granuloma is a rare orbital tumor with very few reported cases [1]. It is an inflammatory reaction to a foreign body. The pathogeny is not well known but about 1/3 of reported cases point out the major role of preexisting trauma with hemorrhages occurring in the diploe of frontal bone [4]. The absence of trauma in many cases suggests the existence of other factors such as bone malformations that need to be elucidated [4,5]. It occurs mainly always in young to middle age males at the superolateral quadrant of the orbit although a case involving the superomedial quadrant of the orbit has been reported in India [5]. The computed tomography scan features are typical showing hypodense or isodense extraconal lesion in supero temporal quadrant of the orbit causing an inferomedial displacement of the eyeball, with frontal bone erosion without any calcification [5-7]. In our case we notice calcification in the mass; and infiltration in the zygoma. If for the treatment all the authors agreed that the complete excision of the mass follow by curettage of the underlying bone leads to a good curative outcome [1-5], the surgical approach varies; from one to others. Some prefer the anterior orbitotomy through sub brow incision [2] others the fronto orbital craniotomy [8]. For this patient, we

choose the lateral orbitotomy to have a better exposure of the tumor and a well dissimulation of the incisional scar. The histopathology confirms the diagnosis by showing inflammatory cells, blood breakdown products, multinucleate giant cells; foamy macrophages and cholesterol crystals [9]. The absence of epithelial cells is a very important sign to rule out dermoid cyst and cholesteatoma [6,9].

Conclusion

Orbital cholesterol granuloma is a rare entity. The management consists of the complete resection of the mass with curettage of the underlying bone cavity. The pathology shows cholesterol clefts; calcifications; and blood products degradation in between mononuclear cells and foamy macrophages and the absence of the epithelial element. After the surgery, the outcome is good.

References

1. Shrirao N, Mukherjee B, Krishnakumar S, Biswas J. Cholesterol granuloma: a case series and review of literature. *Graefes Arch Clin Exp Ophthalmol.* 2016;254:185-188.
2. Yan J, Cai Y, Liu R, Lin J, Li J. Cholesterol granuloma of the orbit. *J Craniofac Surg.* 2015;26:124-126.
3. Sia DI, Davis G, Selva D. Re-current orbitofrontal cholesterol granuloma: a case report. *Orbit.* 2012;31:184-186.
4. Steiner B, Santerre N, Marks C, Pasquesoone X, Hugues P, et al. Orbitofrontal cholesterol granuloma: a case report. *J Fr Ophthalmol.* 2008;31:216.
5. Rizvi SA, Hasan M, Alam MS. Cholesterol granuloma of the orbit: an atypical presentation. *Indian J Ophthalmol.* 2014;62:344-346.
6. Chow LP, McNab AA. Orbitofrontal cholesterol granuloma. *J Clin Neurosci.* 2005;12:206-209.
7. Hill CA, Moseley IF. Imaging of Orbitofrontal cholesterol granuloma. *Clin Radiol.* 1992;46:237-242.
8. Hughes JD, Jacob JT, Garrity JA, Salomao DR, Link MJ, et al. Orbitofrontal cholesterol granuloma: four case reports and a systematic review of the english literature. *World Neurosurg.* 2016;87:355-361.
9. Heaton RB, Ross JJ, Jochum JM, Henry MR. Cytologic diagnosis of cholesterol granuloma: case report. *Acta Cytol.* 1993;37:713-716.