

# Oral Rehabilitation of Permanent Maxillary Incisors Affected by Amelogenesis Imperfecta using CAD-CAM Technology: A Case Report

Maen Zreaqat<sup>1</sup>, Yasser Stas<sup>2</sup>, Rozita Hassan<sup>3</sup>

<sup>1</sup>Orthodontic Unit, School of Dental Science, Universiti Sains Malaysia. <sup>2</sup>Prosthodontic Department, School of Dental Science, Universiti Sains Malaysia. <sup>3</sup>Orthodontic Unit, School of Dental Science, Universiti Sains Malaysia.

## Abstract

This paper describes treatment planning and dental rehabilitation of permanent maxillary incisors of an 11-year old patient affected by hypoplastic Amelogenesis imperfecta using CEREC chair side technology. The treatment was conducted in a multidisciplinary approach and followed by orthodontic treatment using self-ligating brackets to achieve optimum results. The teeth were treated endodontically and reinforced by fiber posts. Oral hygiene instructions and periodontal treatment were conducted. Individual CEREC crowns were fabricated and cemented. The patient's esthetic and functional expectations were satisfied and the new restorations improved significantly her emotional status.

*Key Words: Amelogenesis imperfecta, Multidisciplinary management, CEREC chair side, Anterior crowns, Self-ligating brackets, Follow-up*

## Introduction

Amelogenesis Imperfecta (AI) is associated with different clinical problems including tooth sensitivity, loss of occlusal vertical dimension, dysfunction, and poor esthetics. The enamel may be hypoplastic, hypomineralised or both resulting in teeth being discolored, sensitive or prone to disintegration. Generally both the primary and permanent dentitions are diffusely involved in a more or less equal manner.

AI is basically is an inherited anomaly. It may show autosomal dominant, autosomal recessive, sex-linked and sporadic inheritance patterns [1]. The incidence of AI varies widely between different populations according to the gene pool. Studies reported that the incidence of AI is in the range of 1:700 and 1:14,000 in western population [2]. However, no racial predilections have been demonstrated [3].

Amelogenesis imperfecta is associated with different clinical problems including tooth sensitivity, loss of occlusal vertical dimension, dysfunction, and poor esthetics. Moreover, AI has marked psychosocial effects, which suggests that dental treatment could be medically necessary especially in esthetics-driven societies and at younger ages [4]. Treatment is as ever based on the principles of prevention before intervention. However, in these patients' cases, intervention will likely be earlier and more radical than for others [5]. The multidisciplinary approach is necessary to address the esthetic appearance and optimize masticatory function of affected teeth.

Several authors prefer full porcelain restorations as an alternative to conventional restorations (such as porcelain-fused-to metal crowns) in the treatment of their patient with AI for reasons of esthetics and biocompatibility [6,7]. The introduction of dental CAD/CAM systems in the fabrication of crowns and fixed partial dentures provided innovative, state-of-the-art dental service especially with the development of new high strength ceramic materials. One such system is CEREC 3D (Sirona Dental Systems GmbH, Bensheim, Germany). With CEREC 3D system, crowns are fabricated

by milling ceramic blocks as a single-layer restoration. The system employs Charge-Coupled Device (CCD) camera to take a three-dimensional image of the abutment tooth, and the ceramic material is milled based on these optical data. It has been reported that CEREC 3D system yields reliable marginal and internal fit [8], with low rate of restoration fracture, optimum shade match, and long-term clinical survivability. The aforementioned features document the effectiveness of the CEREC system as a dependable esthetic restorative option.

This paper describes aesthetic restoration of permanent maxillary incisors using the CEREC chair side technology in an 11 year-old girl affected with hypoplastic Amelogenesis imperfecta.

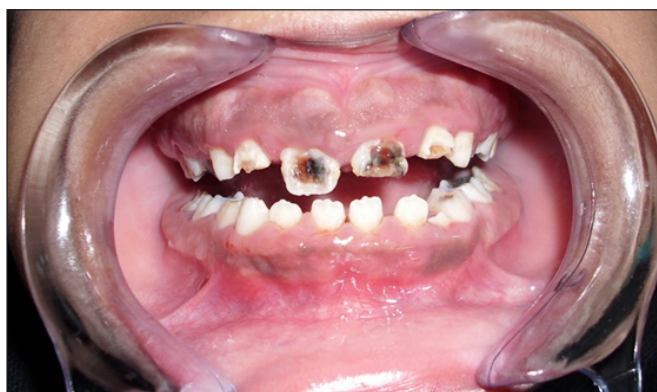## Starting position

An 11-year-old female patient presented with small, discolored, and sensitive anterior teeth. poor aesthetics of front teeth was her main concern and her parents reported that her primary dentition was affected in the same manner. Medical history revealed no systemic disease and no other family member had the same dental problem. The patient's oral hygiene was poor; gingiva was hyperemic and edematous with gingival enlargement around upper central incisors. Her mixed dentition comprised 12 permanent teeth (16,12,11,21,22,26,31,32,36,41,42,46) and 12 deciduous teeth (53,54,55,63,64,65,73,74,75,83,84,85) erupted in the mouth .

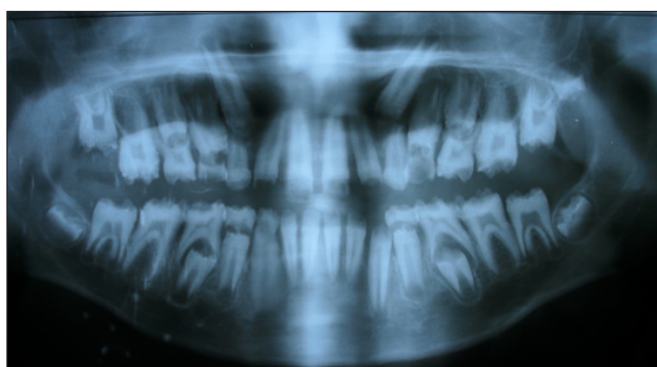
Central and lateral maxillary incisors were severely affected with clinically short crowns, carious remaining dentine, and deep-brown- colored surfaces. Mesial and distal contacts were lost between these teeth as well. Mandibular incisors were intact and sound while the upper and lower first permanent molars were mildly affected (*Figure 1*).

## Procedure

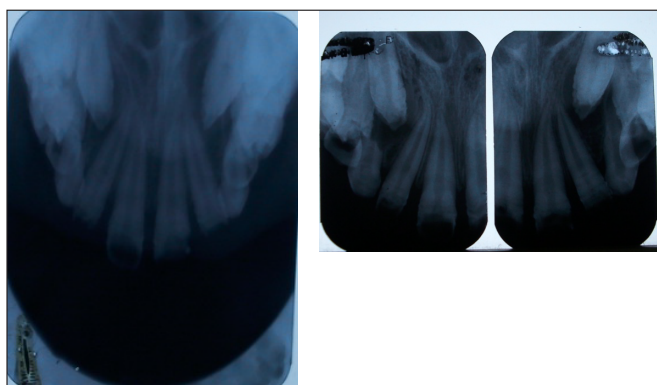
Panoramic, occlusal and periapical radiographs of the patient were obtained (*Figures 2-3*). No congenital missing of any tooth was detected with third molars forming normally except for 18. OPG radiograph confirmed the clinical findings of AI and showed badly decayed maxillary incisors with active



**Figure 1.** Starting position of the patient with AI.



**Figure 2.** Panoramic view of the patient.

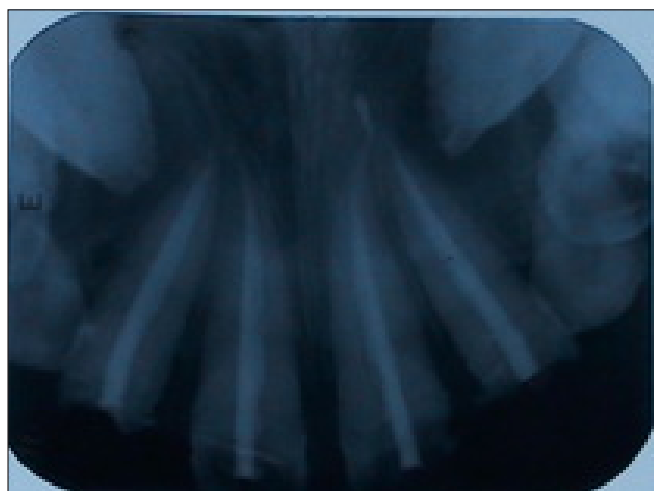

**Figure 3.** Occlusal and periapical radiographs of the maxillary permanent incisors.

caries lesions. An evidence of pre-eruptive coronal resorption on maxillary permanent canines was seen as well.

A team consisting of two paediatric dentists, an orthodontist, a restorative dentist, and periodontist participated in the management of the patient's case. The treatment plan was based on restoring the maxillary incisors with full-ceramic crowns using CEREC 3D chair side technology followed by orthodontic treatment to resolve the proclination of anterior teeth.

The initial stage was periodontal therapy and consisted of scaling, root planning, and oral hygiene instructions. One month later, the gingival edema was resolved and hyperemic appearance of gingiva turned to normal. Also bleeding on probing was normal. All incisors were subjected to root canal treatment (*Figure 4*), root reinforcement using fiber optic posts (3M ESPE-USA), and composite build-up to withstand future crowns. This decision was considered based on the poor long term prognosis of these teeth as they were crumble and had signs of pulp involvement. Teeth were non vital as determined by electric pulp tester.



**Figure 4.** Root canal treatment of maxillary incisors.

Preparation of the maxillary incisors was conducted as a 1.0-mm-wide rounded shoulder around the entire tooth circumference (*Figure 5*). At this stage optical impressions were taken using a CD camera and crowns were then milled from ceramic blocks (Vitablocs Mark II, Vita Zahnfabrik, Germany) based on the captured optical data. Luting space setting on the computer was 30  $\mu$ m. There were no corrections or adjustments for the fit of the crowns. Special attention was paid to coincide facial and dental midline appropriately. CEREC crowns were cemented using dual-curing resin cement 3M ESPE UNICEM. The patient was satisfied with the final appearance of crowns (*Figure 6*).

At this stage, orthodontic treatment was commenced to align the maxillary anterior teeth and resolve their proclination using the self-ligating SmartClip™ SL3 Appliance system from 3M Unitek. the orthodontic treatment was segmental and performed to a minimum to reduce the marked proclination of anterior teeth. Definitive orthodontic treatment is planned once all permanent teeth are erupted (permanent canines have not erupted yet). The patient was reviewed regularly until her orthodontic treatment finished (*Figure 7*) and she was favorably motivated towards her new appearance with a significant improvement in her oral hygiene.

## Discussion

The oral rehabilitation of young children with AI is necessary to reestablish the aesthetic, function, and physiological wellbeing as those patients may develop serious problems that can result in reduced oral health-related quality of life. The purpose of this case report was to present the esthetic and functional rehabilitation of the teeth in an 11-year-old patient with Amelogenesis Imperfecta (AI) following a multidisciplinary approach and using CEREC 3D chair side restorations.

The longer-term care still revolves around either crowns or, more frequently these days, adhesive, plastic restorations. However, whilst many practitioners strive rightly to delay the first "tooth-cutting" restoration, conversations with a substantial number of adults with AI suggest that this professional restraint may be unwelcome and paternalistic. Some of these same adults will recount that, if they had realized that restored teeth must eventually fail, they would have chosen tooth-tissue destructive, but aesthetically more



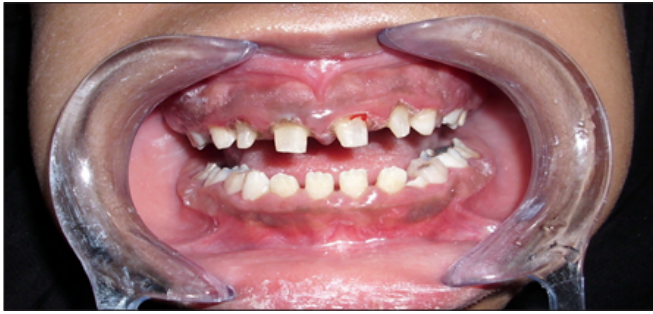

Figure 5. prepared anterior teeth ready for CEREC crowns.

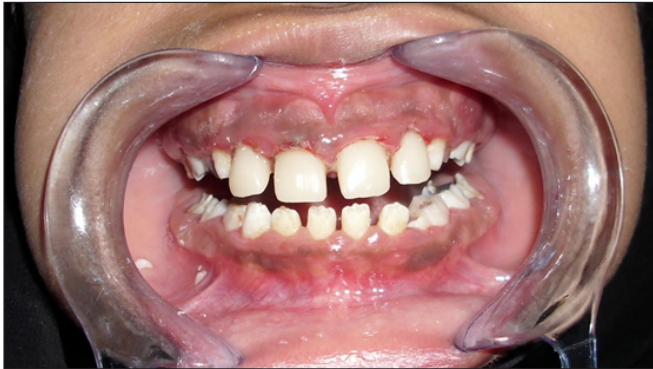

Figure 6. CEREC crowns cemented in the patient mouth.

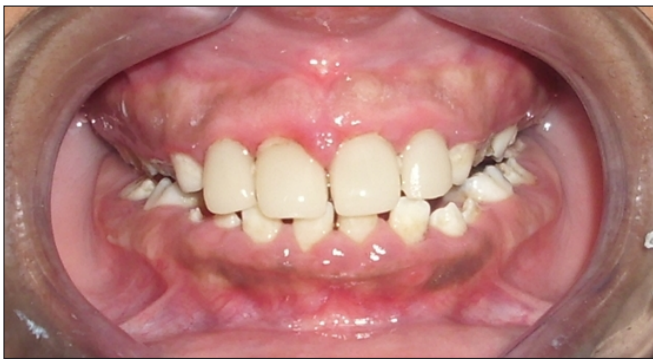

Figure 7. One year after orthodontic treatment.

attractive restorations earlier in their adolescence, in order to appear most "ordinary" to their peers at an important time in social development.

Full porcelain restorations are becoming increasingly popular, because of their inheriting esthetics, excellent biocompatibility and improved physical properties. Advances in dental ceramic materials and the development of CAD/CAM and milling technology have facilitated the development

and application of superior dental ceramics prepared from industrially manufactured ceramics blocks which can yield a homogenous material structure where voids, flaws, and cracks are reduced to a minimum. It has been reported that Cerec 3D system yields reliable marginal and internal fit, and that even severely decayed teeth could be successfully restored while preserving natural tooth structure [9]. The procedure is completed in only one appointment, instead of the multiple visits that are needed for conventional laboratory-created restorations and the patient must undergo only one administration of local anesthetic which is a novel situation in paediatrics with paramount importance. CEREC chair side machine can go beyond conventional restoration protocols to more naturally harmonic applications [10,11].

When considering treatment of the maxillary anterior teeth for esthetic purposes, the dentist must consider each case on its own merits. Porcelain veneers are considered much more conservative in terms of the requirements for preparation, and they provide satisfactory, long-lasting esthetic results. However, if the teeth are already compromised by the presence of extensive carious lesions, wear, old restorations or endodontic treatment, placement of a crown is the more prudent choice especially when support (bracing) to the lingual tooth structure, to prevent future failure is needed. Unfortunately, in this case, parents failed to appreciate the importance of early intervention and the endodontic part was indispensable due to pulp involvement. Early recognition followed by appropriate preventive and restorative care is essential in the successful management of AI and guarantees minimally invasive treatment.

### Conclusion

The complexity of the management of patients with AI supports the suggestion that the dental profession should have appropriate methods for the rehabilitation of rare dental disorders. Dental CAD/CAM systems may exhibit satisfactory clinical performance in such cases where superior esthetics and less clinical sessions are of major concern for patients and clinicians. Moreover, the philosophy of minimally invasive dentistry which reaches the treatment objective with the removal of the minimal amount of healthy tissues and at earlier stages should be addressed among clinicians and patients' families.

### References

1. Bäckman B. Inherited enamel defects. *Ciba Foundation Symposium*. 1997; **205**: 175-182.
2. Brook AH, Smith JM. The aetiology of developmental defects of enamel: A prevalence and family study in East London, U.K. *Connective Tissue Research*. 1998; **39**:151-156.
3. Stephanopoulos G, Garefalaki ME, Lyroudia K. Genes and related proteins involved in amelogenesis imperfecta. *Journal of Dental Research*. 2005; **84**: 1117-1126.
4. Coffield KD, Phillips C, Brady M, Roberts MW, Strauss RP, Wright JT. The psychosocial impact of developmental dental defects in people with hereditary amelogenesis imperfecta. *Journal of American Dental Association*. 2005; **136**: 620-630.
5. Canger EM, Celenk P, Yenisey M, Odyakmaz SZ. Amelogenesis imperfecta, hypoplastic type associated with some

dental abnormalities: A case report. *Brazilian Dental Journal*. 2010; **21**: 170-174.

6. Kamble VD, Parkhedkar RD. Multidisciplinary approach for restoring function and esthetics in a patient with amelogenesis imperfecta: A clinical report. *Journal of Clinical and Diagnostic Research*. 2013; **7**: 83-85.

7. Nel JC, Pretorius JA, Weber A, Marais JT. Restoring function and esthetics in patient with amelogenesis imperfecta. *International Journal of Periodontics Restorative Dentistry*. 1997; **17**: 478-483.

8. Kassem AS, Atta O, El-Mowafy O. Fatigue resistance and microleakage of CAD/CAM ceramic and composite molar crowns. *Journal of Prosthodontics*. 2012; **21**: 28-32.

9. Reich SM, Rinne H, Shortall A, Wichmann M. Clinical performance of large, all-ceramic CAD/CAM-generated restorations after three years: A pilot study. *Journal of American Dental Association*. 2004; **135**: 605-612.

10. Stas Y. Cantilevered restorations using CAD/CAM Cerec chairside technology: A case report. *International Journal of Computerized Dentistry*. 2008; **11**: 131-138.

11. Pozzi A, Tallarico M, Mangani F, Barlattani A. Different

implant impression techniques for edentulous patients treated with CAD/CAM complete-arch prostheses: A randomised controlled trial reporting data at 3 year post-loading. *European Journal of Oral Implantology*. 2013; **6**: 325-340.