

Mycotoxins that Affect the Human Cardiovascular System

Magda Carvajal-Moreno*

Laboratorio de Micotoxinas, Departamento de Botánica, Universidad Nacional Autónoma de México, Ciudad Universitaria, México

Abstract

Mycotoxins are toxic secondary metabolites produced by fungi in the field or during storage; these fungi are mainly saprophytic molds growing on foodstuffs or animal feeds. These molds produce chemical compounds of low molecular weight that are not detected by antigens and hence are insidious poisons with no obvious symptoms. Since 1960, mycotoxins have been considered responsible for diseases and death in domestic animals and humans. Mycotoxicoses, the diseases caused by mycotoxins, have been responsible for major epidemics in humans and domestic animals since agriculture was developed. Each of these diseases is caused by specific molds that produce one or more potent toxins, usually in one specific type of commodity or feed. Among the main mycotoxigenic fungi are the genera *Aspergillus* spp., *Penicillium* spp. and *Fusarium* spp.

The symptoms caused by mycotoxins can be acute or chronic, depending on the type of toxin and the dose. The symptoms of acute mycotoxicoses include liver and kidney damage, attacks on the central nervous system, skin disorders, hormonal effects, miscarriage, hemorrhage, vomiting, diarrhea and many others. Mycotoxins are eaten in trace quantities in the daily diet; some, such as aflatoxins, can accumulate, whereas others are quickly eliminated. Examples of chronic mycotoxicoses include Reye syndrome, Kwashiorkor, and cancers that develop in experimental animals or humans long after the mycotoxin is eaten. In the present review, we will describe some mycotoxins that cause circulatory problems, vein breakage, hemorrhage, and heart failure.

Keywords: Mycotoxins; Aflatoxins; Citreoviridin; Moniliformin; T-2 toxin; Cardiovascular system

Aflatoxins

Chemical name: 2,3,6aR,9aS-tetrahydro-4-methoxy-1H,11H-cyclopenta[c]furo[3',2':4,5]furo[2,3-h][1]benzopyran-1,11-dione (Figure 1).

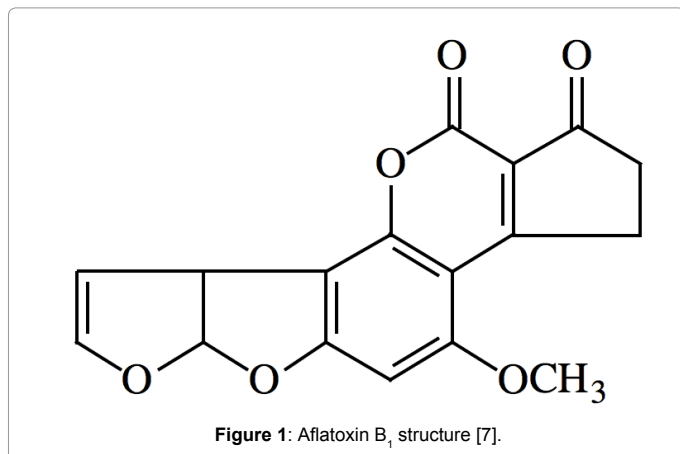


Figure 1: Aflatoxin B₁ structure [7].

The fungal asexual phase and producer of aflatoxins is *Aspergillus*, a green-yellowish mold of the species *A. flavus* Link ex Fries, *A. parasiticus* Speare [1], *A. bombycis* [2], *A. ochraceoroseus* [3-5], *A. nomius* Kurtzman Horn and Hesselt and *A. pseudotamarii* [6].

The structures, physicochemical properties [7], biosynthesis [8], production conditions and occurrence of aflatoxins are also well known [9,10]. One important property of aflatoxins is that they form links to DNA, RNA and proteins [11,12], and they accumulate over time as adducts of AFB₁-formamidopyrimidine (AFB₁-FAPY) [13] and AFB₁-lysine albumin [14], which are active carcinogens.

Aflatoxins, the most powerful mycotoxins, were discovered in the

early 1960s with the outbreak of turkey "X" disease in England and high incidences of liver disease in ducklings in Kenya and hatchery-reared trout in the United States; the causes of all these problems were aflatoxins [15]. Aflatoxins are present in numerous foods, such as cereals, spices [16], oilseeds [17], and dry fruits. After these foods are consumed, the aflatoxins pass into milk, [18,19], all dairy products, eggs [20] and meat [21] derivatives. Aflatoxins are considered unavoidable toxins [22]. Biological control measures include lactic acid bacterial fermentation, which is known to render cereal-based foods and beverages safe [23], and the use of aluminosilicates, glucomannans and optimal storage conditions to prevent fungal growth.

Aflatoxin intake is related to kwashiorkor [24] and Reye syndrome [25], and aflatoxins induce liver damage in undernourished individuals [26]. Aflatoxins are classified as Group I carcinogens in humans [27]; they are potent mutagens and teratogens, and they cause abortions, immunosuppression and cardiovascular symptoms. These toxins weaken veins and arterial walls, break platelets and cause internal hemorrhaging [28]. Aflatoxin B₁ (AFB₁) may interfere with the normal process of protein synthesis and may inhibit several metabolic systems, thus causing damage to various organs, especially the liver, kidney and heart [29,30].

The histopathological features of various abnormalities induced by different doses of ochratoxin A, AFB₁, and their combination in rat fetuses have been studied [31]. Histological examination of fetal organs

*Corresponding author: Magda Carvajal-Moreno, Laboratorio de Micotoxinas, Departamento de Botánica, Instituto de Biología, Universidad Nacional Autónoma de México, Ciudad Universitaria, Coyoacán, 04510 México DF, Tel: +5255 5622 9138; Email: magdac@ib.unam.mx

Received March 18, 2015; Accepted April 15, 2015; Published April 22, 2015

Citation: Carvajal-Moreno M (2015) Mycotoxins that Affect the Human Cardiovascular System. J Biomol Res Ther 4: 124. doi:10.4172/2167-7956.1000124

Copyright: © 2015 Carvajal-Moreno M. This is an open-access article distributed under the terms of the Creative Commons Attribution License, which permits unrestricted use, distribution, and reproduction in any medium, provided the original author and source are credited.

after AFB1 treatment revealed that the liver, brain, kidney, and heart were affected. The incidence of heart lesions, especially valvular defects, was higher in rats treated with the combination diets. There was an antagonist effect of ochratoxin A with the AFB1, which was responsible for the teratogenic effect [31].

In the case of poultry, serious pathological changes were noted in the heart when crude toxin preparations from *Aspergillus flavus* mixed with normal foodstuff were given to animals [32]. Some clinical effects of aflatoxins on the cardiovascular system are frequent hemorrhage in different organs in animals such as chickens [33,34], horses [35], dogs [36] and humans [37]. The effects of chronic oral exposure (28 days) to AFB1 and fumonisin B1 (FB1) were studied in weaned piglets. The heart/body weight ratio of the piglets was significantly greater in groups fed with 30 mg of FB1/kg of feed with or without 50 mg of AFB1/kg added to the feed. The heart effect was more strongly associated with fumonisins than with aflatoxins [38].

Aflatoxin poisoning occurred in Uganda in 1967, in a 15-year-old boy who was diagnosed as suffering from heart failure; he died 2 days after hospital admission. An autopsy revealed pulmonary edema, flabby heart, and interstitial edema of the heart, along with other symptoms, such as liver necrosis [39]. Aflatoxins have been detected in the heart muscle [40].

Cereals (e.g., maize, rice, and sorghum), nuts (e.g., walnut, pecan, pistachio, and cashew) and spices (e.g., black and green peppers and chili) cannot avoid *Aspergillus* fungal attacks; therefore, all of these foods are heavily contaminated with aflatoxins, and their consumption facilitates the development of human cancer. Physicians recommend maize, cereals and nuts in the diet, which have heavy loads of carcinogens, mutagens, and teratogens and inhibit immunological defenses. AFs are analyzed at the ng/g level, but the amount that a person consumes in cooked foods and desserts exceeds tolerance limits and, depending on frequency, can be considered a risk factor for chronic health effects.

However, maize and nuts have developed substances to inhibit the mutagenicity of the fungus and protect themselves. In this way, cereals and oilseeds have contradictory properties; maize has oleic acid to protect against aflatoxin mutagenicity, and walnuts are considered part of a "healthy" diet that provides oils, proteins, minerals, flavonoids, tannins, phenolic acids, polyphenols, and antioxidants, which protect against fat nodules (atheroma plaques) in the arteries, are anti-inflammatory and anti-mutagenic [41] and contain unsaturated fatty acids and vitamins [42], which protect against diabetes [43].

Additionally, pecans contain compounds that have protective effects on the heart [44] and are a source of monounsaturated fatty acids and heart-protective compounds, including vegetable sterols, vitamins A, B and E, folic acid, calcium, magnesium, phosphorus, zinc and fiber [44]. Pecans are a cholesterol-free food with high protein content, and its oleic acid is similar to that of olives [45].

Cashews contain cardol, which has antimicrobial activities [46]. They contain more ascorbic acid than oranges, vitamins B1 and B2, pantothenic acid, and minerals, such as magnesium [47], and they are rich in unsaturated fatty acids, such as oleic and linoleic acids. The cashew has raw protein and lysine levels comparable to those of peanuts [48] and soybean, and it has higher amounts of sulfur amino acids and oils and gums with cardol, which is a caustic and poisonous substance that evaporates when the nuts are heated [49]. The cashew contains a group of phenolic compounds known as "cashew nut shell liquid" (CNSL) [50-52], which includes anacardic acid, cardanol and cardol, the last of which has been reported to have antimicrobial activities [46],

possibly conferring resistance to *Aspergillus* invasion. Thus, a dialectic situation is established: the food that cures you has toxins that can also kill you, and life and death are united in a single nut or maize cob.

Aflatoxins have an effect on the cardiovascular system, with hemorrhage being the most frequent symptom, although their main symptoms are as liver carcinogens.

Citreoviridin

Chemical name: 2,5-anhydro-1,6-dideoxy-2-C-[(8-(4-methoxy-5-methyl-2-oxo-2H-pyran-6-yl)-2-methyl-1E,3E,5E,7E-octatetraen-1-yl)-4-C-methyl-D-idoitol (Figure 2).

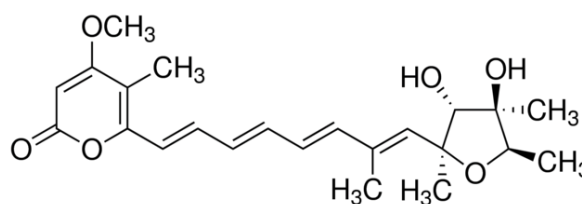


Figure 2: Structure of citreoviridin, a mycotoxin produced by *Penicillium citreoviride* [52].

The history of mycotoxin research in Japan began in 1891, when Sakaki demonstrated that moldy, unpolished rice was fatal to experimental animals, with symptoms indicating paralysis of the central nervous system (Shoshin-kakke) [53,54]. In 1920, Miyake and Takada first reported that *Penicillium commune*, known as a causal agent of "Mossy diseased rice", was toxic when fed to rabbits and rats [53]. Miyake and collaborators discovered the first sample of yellow rice grains from Taiwanese and domestic rice containing *Penicillium citreonigrum* (= *P. toxicarium*), which produced citreoviridin [53,55]. Among isolates from imported rice, Tsunoda et al. found *Penicillium islandicum*, which produced brownish, discolored rice containing two hepatotoxic metabolites: luteoskyrin and cyclochlorotine [53,56]. Toxic disturbances associated with the consumption of rice contaminated with *Penicillium* species occurred and became known as "Yellow rice syndrome" [56,57]. Although no human cases of poisoning have been recorded, mycotoxicologists recommended that the Japanese government take action to protect citizens against "yellow rice poisoning" caused by a metabolite of *Penicillium citreoviride* called citreoviridin. This disease, which is manifested in humans and experimental animals by respiratory and circulatory failure, paralysis, convulsions and death, is identical to beriberi, originally considered to be a thiamin nutritional deficiency [53,58].

Citreoviridin plays a major role in causing myocardial injury (degeneration and necrosis) in adult Wistar rats exposed to it, and citreoviridin combined with deficiencies in selenium and protein can aggravate the damage at the biochemical level [59]. Cardiac toxicity of citreoviridin in selenium-protein with citreoviridin group caused the intercalary discs of cardiac myocytes to become fragmented; the junctions between myocytes were broken; in some regions, cardiac myocytes became edematous and even dissolved; the structure of sarcomeres was not obvious; mitochondrial cristae were loosened; cavities in myocytes were occasionally observed; and there was substantial disseminated sarcoplasmic reticulum extension. In selenium-protein with no citreoviridin group, the change in cardiac myocytes' membrane structures was not obvious; the filament structure disappeared around the nucleus, and the deposition of mass floccule was observed. The authors concluded that citreoviridin is the main risk

factor for inducing myocardial damage [60].

Acute cardiac beriberi

Acute cardiac beriberi is caused by citreoviridin, a mycotoxin produced by *Penicillium citreonigrum*. Acute cardiac beriberi was a common disease in Japan, especially in the second half of the last century. This disease is characterized by difficulty breathing, nausea and vomiting, and, after 2 to 3 days, severe pain and distress. Progressive paralysis may lead to respiratory failure and death. There was also an outbreak of beriberi deaths reported in 2006 in the Maranhao State of Brazil, which was caused by citreoviridin from *Penicillium citreonigrum* strains and was associated with rice consumption [61].

Beriberi is the general name for vitamin deficiencies resulting from the consumption of polished rice. Acute cardiac beriberi may be a toxicosis rather than a vitamin deficiency [62]. In 1910, the incidence of acute cardiac beriberi suddenly decreased in Japan when government inspection led to a reduction in the sale of moldy rice. The incidence of true beriberi, resulting from the consumption of polished rice, was unaffected. The victims of acute cardiac beriberi were often young, healthy adults. This mycotoxicosis is characterized by precordial distress with palpitation and tachypnea; as the dyspnea worsens, nausea and vomiting are experienced. After a few days, the victim suffers severe anguish, pain, and restlessness and can become violently maniacal at times. The right heart is dilated, and the heart sounds are abnormal. In the final stages, as the dyspnea increases, the extremities become cold and cyanotic, the pupils dilate, and the person loses consciousness. The neurotoxic mycotoxins of *Penicillium citreo-viride* Biourge may also cause acute cardiac beriberi [62].

Keshan disease

Keshan disease is also caused by citreoviridin toxin [63]. An individual with Keshan disease will have an abnormally large heart. Keshan disease can also lead to higher rates of cancer, cardiovascular disease, hypertension, and stroke. In addition, an individual can experience eczema, psoriasis, arthritis, cataracts, alcoholism, and infections. There has been controversy because some authors initially thought that Keshan disease was caused by coxsackievirus B3 viral infection [64,65]. Currently, many other authors attribute Keshan disease to the mycotoxin citreoviridin [60,63,66,67]. Tsunoda et al. found that *P. citrinum* was responsible for yellowish rice, which was associated with the high nephrotoxic toxicity produced by citrinin [53,56].

Moldy millet or maize, but not wheat, eaten for 4-12 months produced an outbreak of Keshan disease. Rats fed with 4 mg/kg (body weight) of citreoviridin-contaminated grain every day for 4-6 weeks exhibited necrosis of myocardium and cell mitochondrial swelling, proliferation and damage, identical to what was observed in cases of death from Keshan disease.

A number of genes in peripheral blood mononuclear lymphocytes of patients with Keshan disease are significantly differently expressed from those of healthy people [67]. These genes are mainly involved in cell proliferation, apoptosis and cell function restoration, and they may play an important role in the development of Keshan disease. Keshan disease must not be confounded with Kashin-Beck disease, which is a permanent and disabling osteoarticular disease involving growth and joint cartilage with multifactorial etiology associated with selenium deficiency, inorganic (manganese and phosphate) and organic matter (humic acids and fulvic acids) in drinking water, and fungi on self-

produced storage grain (*Alternaria spp.* and *Fusarium spp.*), which produce trichothecene (T-2) mycotoxins.

The gene expression profiles of Kashin-Beck and Keshan diseases occurring within the same endemic areas of China were compared [66]. Total RNA was isolated from peripheral blood mononuclear cells from 36 patients and 28 controls, and gene expression profiles were analyzed using oligonucleotide microarrays. Sixteen genes that were differentially expressed in both Kashin-Beck and Keshan disease (versus controls) were identified, including nine genes with synchronous expression and seven with asynchronous expression. The comparative toxicogenomics database shows that the expression and biological function of these genes can be affected by multiple environmental factors, including mycotoxin and selenium content, which are potential environmental risk factors for the two diseases. Thus, these shared differentially expressed genes may contribute to the distinct organ lesions caused by the common environmental risk factors for Kashin-Beck and Keshan diseases [66].

Onyalai

Onyalai is an acute disease of the circulatory system characterized by hemorrhaging lesions in the mouth. Onyalai has been endemic in Africa, especially in Southern Sahara regions, for at least 80 years [68]. This disease is much more common in rural than in urban populations. Many of the people affected by onyalai subsist on millet; therefore, Rabie et al. (1975) [68] suggested a possible role of a mycotoxin in this cereal. Toxicogenic isolates of *Phoma sorghina* were found to be common in millet consumed by affected populations, and Rabie et al. (1975) [68] reproduced many of the symptoms of onyalai in rats fed maize and wheat on which *P. sorghina* had been grown.

Moniliformin

Chemical name: Sodium 3,4-dioxo-1-cyclobutenolate. The condensed formula of moniliformin is K or NaC₄H₃O₃ (Figure 3).

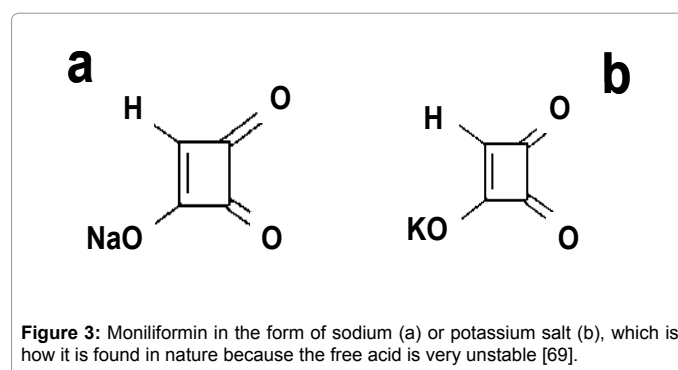


Figure 3: Moniliformin in the form of sodium (a) or potassium salt (b), which is how it is found in nature because the free acid is very unstable [69].

Moniliformin or semiquaric acid is a mycotoxin formed by 3-hydroxy-3-cyclobutene-1,2 dione acid. This toxin was discovered in 1973 in maize in the USA [69], and the fungus was incorrectly identified as *Fusarium moniliforme* Sheldon emend. Snyd. and Hans., leading to its being named moniliformin. The following *Fusarium spp.* produce moniliformin [70,71]:

I. Section Liseola: *F. anthophilum* (A. Braun) Wollenw., *F. dlamini*, *F. napiforme*, *F. nygamai*, *F. proliferatum* (Matsushima) Nirenberg [72], *F. subglutinans* (Wollenw. and Reinking) Nelson, Toussoun and Marasas. [73-75].

II. Section Arthrosporiella: *F. concolor*, *F. semitectum* Berk. and

Rav (*Syn F. roseum*).

III. Section Discolor: *F. culmorum* (W.G. Smith) Sacc. [76], *F. sambucinum* Fuckel (*Syn F. roseum*) and *F. graminearum* Schwabe.

IV. Section Elegans: *F. beomiforme*, *F. oxysporum* Schlecht emend. Snyder and Hans. (*Syn F. redolens*);

V. Section Gibbosum: *F. acuminatum* Ell. and Ev. (*Syn F. equiseti*);

VI. Section Martiella and Ventricosum: *F. solani* (Mart.) Appel and Wollenw. emend. Snyder and Hans.

VII Section Roseum: *F. arthrosporioides* Sherb. (sometimes identified as a clone of *F. avenaceum*), *F. avenaceum* (Fr.) Sacc. [77].

VIII. Section Sporotrichiella: *F. chlamydosporum* Wollenw. and Reinking (*Syn. F. fusarioides* (Frag. and Cif.) Booth. *Syn F. sporotrichioides* [76], *F. tricinctum*).

Springer et al. (1974) [78] first characterized the structure of moniliformin as a small cyclic molecule with a molecular weight of 136.11 g/mol, which is found in nature as a water-soluble sodium or potassium salt (Figure 3) because the free acid has a very low pKa (<1.7). The physicochemical properties of moniliformin have been described [79-81]. Moniliformin as free acid decomposes when it is heated to 150-153°C without melting, and the maximum absorbance with UV light is 229 nm to 260 nm in methanol.

The fungi that produce moniliformin also produce other mycotoxins, such as fumonisins, beauvericin, fusaproliferin, fusarins, trichothecene, and zearalenone [82-89], which are generally found in mixtures with moniliformin [83-88].

Moniliformin is produced by at least 30 *Fusarium* species isolated from different substrates and geographical areas [70,71,77]. *F. proliferatum* and *F. subglutinans* parasitize maize, and *F. avenaceum* parasitizes wheat [89]. There is great variability in the moniliformin synthesized by *Fusarium spp.* in both the percentage of producer lines and the amount produced. Moniliformin was isolated and chemically characterized from *F. nygamai* Burgess and Trimboli NRRL-6022 (ATCC-12763), a millet isolate from Nigeria strain 4364, which produces large amounts of this toxin [80]. Other producer strains were isolated from cotton from North Carolina, USA. *F. proliferatum* in rice incubated at 25°C for 21 days is produced at up to 16,000 ppm; these amounts in maize cause rejection syndrome in cattle [90]. Moniliformin occurs naturally in different cereals (maize, rice, wheat, oat and barley). Its incidence varies from 1/1 to 57/57 and 47/104, its concentration ranges from 0.02 to 530 ng/g, and it has been reported in countries such as South Africa, Tanzania, Canada, USA, China, Austria, The Netherlands, United Kingdom, Italy and Poland [71,86,89,91].

Moniliformin in large amounts acts at the level of sugar metabolism; it inhibits the oxidative decarboxylation of pyruvate, increasing its level in serum, causing a decrease in oxalate and an increase in the Krebs cycle, and is cytotoxic at high concentrations in mammalian cells. This toxin causes intoxication, and the lesions include intestinal hemorrhage, muscle weakness, breathing difficulty, cyanosis, coma and death [73]. However, in studies in barnyard fowls and rodents using subacute and chronic dosages, its effect was on the heart.

The high metabolic rate of heart tissue makes it a target organ for the toxic effects of the energetic inhibition of metabolism. Moniliformin inhibits the basal mechanism of enzymes (thiamine, pyruvate dehydrogenase, ketoglutarate dehydrogenase, pyruvate decarboxylase and acetohydroxy acid synthetase). Because these enzymes share a

cofactor, it is possible that the action of moniliformin is based on its attack on thiamine. Reductions in glutathione peroxidase and reductase are due to the reduced activity of these antioxidants, which might be the cause of the myocardial damage observed in animals treated with this mycotoxin. Another suggested mechanism is the alteration of the electrolyte composition of cardiac myocytes, causing bradycardia and heart failure [91].

The use of a moniliformin-producing isolate of *Fusarium moniliforme* in corn as the base diet of chicks, ducklings and turkey poults was found to be lethal, with the ducklings being the most sensitive to the toxic feed. The gross lesions were ascites, hydropericardium, myocardial pallor, kidney failure [92,93], high levels of pyruvate in the serum, immunodeficiency [94], cardiomyopathy, heart lesions, ventricular arrhythmia, cardiac fibrosis, hemorrhage in the brains of treated birds, stunting, alterations in the electrical conductivity of the heart muscle and death. The microscopic lesions showed degeneration and necrosis of the myocardium and degeneration of hepatocytes. Cardiotoxicosis was the apparent cause of death [75,92]. Thiamine supplementation can overcome the cardiotoxic effects of *F. proliferatum* [95,96]. In human food, 12 of 14 maize tortillas had moniliformin concentrations ranging from 0.022 to 0.1 ng/g [75], although human exposure has not been studied.

Fumonisin

Formal name: 1,2,3-propanetricarboxylic acid, 1,1'-[1-(12-amino-4,9,11-trihydroxy-2-methyltridecyl)-2-(1-methylpentyl)-1,2-ethanediyl] ester (Figure 4).

Fumonisin is a group of mycotoxins found in corn contaminated with *Fusarium* fungus, mainly *F. verticillioides* (= *F. moniliforme*), the source of the name of these toxins. Fumonisin are chains of approximately 20 carbons with acidic ester, acetylamine and sometimes

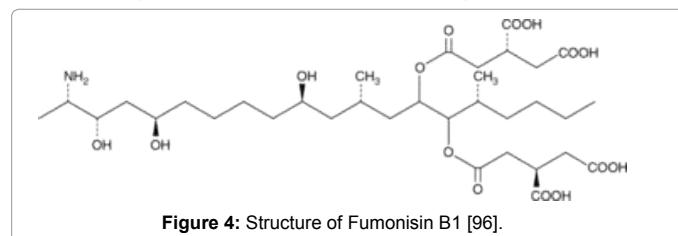


Figure 4: Structure of Fumonisin B1 [96].

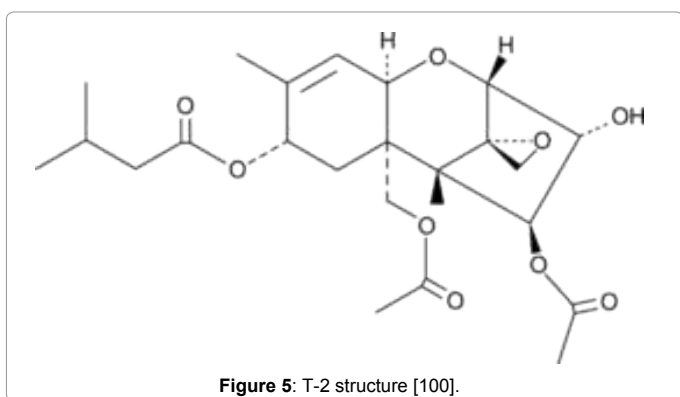
other radicals. The most important fumonisins are B1 and B2. At least 15 different fumonisins have been reported, and other minor metabolites have been identified, although most of them have not been shown to occur naturally [96].

Fumonisin inhibit the ceramide synthetase-catalyzed conversion of sphingolipids to ceramides, and they cause leukoencephalomalacia in equines and porcine pulmonary edema and liver cancer in rats. The hepato- and cardiotoxicity of *Fusarium verticillioides* (*F. moniliforme*) isolates from Southern African maize that produced only fumonisins and their toxicity to ducklings and rats were determined. Cirrhosis and nodular hyperplasia of the liver, as well as the occurrence of acute and proliferative endocardial lesions and concurrent intraventricular thrombosis were frequently encountered and were considered to be the most important lesions; thrombosis of the larger vessels of the heart occurred less often [97]. The individual and combined effects of the *Fusarium* mycotoxins Fumonisin B1 (FB1) and moniliformin were studied in broiler chicks. The interactive effects of moniliformin and fumonisins were not synergistic; moniliformin was much more toxic to broilers than FB1 [98].

The teratogenic, embryopathic and embryocidal effects of purified fumonisin B1 and moniliformin on chicken embryos were studied. Early embryonic changes in the exposed embryos included hydrocephalus, enlarged beaks and elongated necks. Pathologic changes were noted in the liver, kidneys, heart, lungs, musculoskeletal system, intestines, testes and brains of the toxin-exposed embryos [99].

T-2

Formal name: (3 α ,4 β ,8 α)-12,13-epoxy-4,15-diacetate 8-(3-methylbutanoate) trichothec-9-ene-3,4,8,15-tetrol (Figure 5) T-2 (synonyms are Fusariotoxin T-2, Insariotoxin and Mycotoxin T-2) is a trichothecene mycotoxin. T-2 is a naturally occurring mold that is a byproduct of *Fusarium* spp. fungi and is toxic to humans and animals. The clinical condition caused by T-2 is alimentary toxic aleukia (ATA) [100], with symptoms in diverse organs such as the skin and airway, and stomach ingestion, which may come from the consumption of moldy whole



grains. T-2 can also be absorbed through human skin [101]. Skin contact with T-2 causes acute disturbances in the circulatory system (hypotension and arrhythmia), which may result from general pathophysiological responses to the T-2 toxin, including a central effect on blood pressure and catecholamine elevation, which have been reported in pigs and rats [102,103]. General arteriosclerosis and hypertension have been reported as delayed sequelae of repeated exposure to T-2 toxin [104]. In a series of studies of rats exposed to a limited course of T-2 toxin, doses caused the thickening of coronary arteries, including myocardial changes. Four injections of 3 mg of T-2 toxin/kg bw on alternate days led to vacuolization and swelling of endothelial cells, basement membrane changes and enlarged medial smooth muscle cells. After the topical application of T-2 toxin (1-20 μ g) to rat skin, dilated microvessels packed with erythrocytes and an increased number of degranulated mast cells were observed [105-107]. In experimental animals, cardiovascular responses to T-2 toxin administration included tachyarrhythmia, hypotension, and shock [104,108].

T-2 mycotoxin has been used as biological weapon: flour contaminated with *Fusarium* was produced and distributed in bread, causing significant morbidity and mortality [101]. T-2 was also used in Vietnam and was known as "yellow rain" [109].

Conclusions

Among the most important mycotoxins that cause cardiovascular problems, aflatoxins have the risk of forming adducts and being stored for years in the DNA of all cells, causing hemorrhage and heart malformations. Among the typical cardiotoxic mycotoxins, the two potent toxins that cause the worst damage are citreoviridin and

moniliformin. Considering the worldwide occurrence of moniliformin together with its high acute toxicity, research into the subchronic toxicity is of vital importance to identify the possible risk in human or animal health. Fumonisin are very frequent and related to malformations as has been reported here. It is impossible to produce food completely free of mycotoxins, improvements in storage and handling of grains, can minimize mold growth, and so reduce the risk of mycotoxin contamination in food supplies.

Acknowledgements

The authors would like to thank the Instituto de Biología, Universidad Nacional Autónoma de México (UNAM) for supporting this work. I would like to thank Georgina Ortega Leite and Gerardo Arévalo for library information (Pub Med), and to Joel Villavicencio and Jorge López for computer assistance, and to Noemí Chávez of the Technical Secretary, all from Institute of Biology, UNAM.

References

- Diener UL, Davis ND (1987) Biology of *Aspergillus flavus* and *A. parasiticus*. In: Zuber MS, Lillehoj EB, Renfro BL (eds.) Aflatoxin in maize: A Proceedings of the workshop. CIMMYT, Mexico, pp. 33-40.
- Peterson SW, Ito Y, Bruce W, Horn BW, Goto T (2001) *Aspergillus bombycis*, a new aflatoxinogenic species and genetic variation in its sibling species *A. nomius*. *Mycologia* 93: 689-703.
- Bartoli A, Maggi O (1978) Four new species of *Aspergillus* from Ivory Coast soil. *Trans Br Mycol Soc* 71: 383-394.
- Klich MA, Cary JW, Beltz SB, Bennett CA (2003) Phylogenetic and morphological analysis of *Aspergillus ochraceoroseus*. *Mycologia* 95: 1252-1260.
- Jeffrey C, Pamela H, Kenneth E, Shannon B, Maren K (2007) Cloning and characterization of the *Aspergillus ochraceoroseus* Aflatoxin biosynthetic gene cluster. *Am Soc Microbiol Annual Meeting*.
- Ehrlich KC, Kobbeman K, Montalbano BG, Cotty PJ (2007) Aflatoxin-producing *Aspergillus* species from Thailand. *Int J Food Microbiol* 114: 153-159.
- OPS, Organización Panamericana de la Salud (1983) Criterios de Salud Ambiental 11. Publicación Científica N° 453. Organización Mundial de la Salud, USA pp. 131.
- Sweeney MJ, Dobson AD (1999) Molecular biology of mycotoxin biosynthesis. *FEMS Microbiol Lett* 175: 149-163.
- Cotty PJ, Jaime-García R (2007) Influences of climate on aflatoxin producing fungi and aflatoxin contamination. *Int J Food Microbiol* 119: 109-115.
- Cole RJ, Sanders TH, Dorner JW, Blankenship PD (1989) Environmental conditions required to induce preharvest aflatoxin contamination of groundnuts: Summary of six years research. In: Aflatoxin contamination of groundnut. ICIRISAT Center, pp. 279-287.
- Wild CP, Pisani P (1998) Carcinogen DNA and protein adducts as biomarkers of human exposure in environmental cancer epidemiology. *Cancer Detect Prev* 22: 273-283.
- Yu MW, Lien JP, Liaw YF, Chen CJ (1996) Effects of multiple risk factors for hepatocellular carcinoma on formation of aflatoxin B₁-DNA adducts. *Cancer Epidemiol Biomarkers Prev* 5: 613-619.
- Carvajal M, Berumen J, Guardado-Estrada M (2012) The presence of aflatoxin B₁-FAPY adduct and human papilloma virus in cervical smears from cancer patients in Mexico. *Food Addit Contam Part A Chem Anal Control Expo Risk Assess* 29: 258-268.
- Groopman JD, Egner PA, Schulze KJ, Wu LS, Merrill R, et al. (2014) Aflatoxin exposure during the first 1000 days of life in rural South Asia assessed by aflatoxin B₁-lysine albumin biomarkers. *Food Chem Toxicol* 74: 184-189.
- Asao T, Buechi G, Abdel-Kader MM, Chang SB, Wick EL, et al. (1965) The structures of Aflatoxins B and G. *J Am Chem Soc* 87: 882-886.
- Akiyama H, Goda Y, Tanaka T, Toyoda M (2001) Determination of aflatoxins B₁, B₂, G₁ and G₂ in spices using a multifunctional column clean-up. *J Chromatogr A* 932: 153-157.
- Campbell BC, Molyneux RJ, Schatzki TF (2003) Current research on reducing pre- and post-harvest aflatoxin contamination of US almond, pistachio, and

- walnut. J Toxicol Toxin Rev 22: 225-266.
18. Carvajal M, Bolaños A, Rojo F, Méndez I (2003) Aflatoxin M1 in pasteurized and ultrapasteurized milk with different fat content in Mexico. J Food Prot 66: 1885-1892.
19. Carvajal M, Rojo F, Méndez I, Bolaños A (2003) Aflatoxin B1 and its interconverting metabolite aflatoxicol in milk: the situation in Mexico. Food Addit Contam 20: 1077-1086.
20. Yenice E, Mizrak C, Ceylan N, Yildiz T, Gültekin M et al. (2015) Effects of dietary sodium bentonite and mannan oligosaccharide supplementation on performance, egg quality, blood and digestion characteristics of laying hens fed aflatoxin contaminated diet. Kafkas Universitesi Veteriner Fakultesi Dergisi 21: 211-218.
21. Díaz-Zaragoza M, Carvajal-Moreno M, Méndez-Ramírez I, Chilpa-Galván NC, Avila-González E, et al. (2014) Aflatoxins, hydroxylated metabolites, and aflatoxicol from breast muscle of laying hens. Poult Sci 93: 3152-3162.
22. Waseem A, Shah SA, Sajjad A, Siddiqi AR, Nafees M (2015) Human exposure to mycotoxins: A retrospective review of leading toxins and metabolites in human biological matrices. J Chem Soc Pak 36: 1196-1214.
23. Waters DM, Mauch A, Coffey A, Arendt EK, Zannini E (2015) Lactic acid bacteria as a cell factory for the delivery of functional biomolecules and ingredients in cereal-based beverages: a review. Crit Rev Food Sci Nutr 55: 503-520.
24. Hendrickse RG, Coulter JB, Lamplugh SM, Macfarlane SB, Williams TE, et al. (1982) Aflatoxins and kwashiorkor: a study in Sudanese children. Br Med J (Clin Res Ed) 285: 843-846.
25. Reye RD, Morgan G, Baral J (1963) Encephalopathy and Fatty Degeneration of the viscera. A Disease Entity In Childhood. Lancet 2: 749-752.
26. Newell J (1983) Treatment for starvation may kill. New Sci 99: 471.
27. IARC Working Group on the Evaluation of Carcinogenic Risks to Humans (2002) Some traditional herbal medicines, some mycotoxins, naphthalene and styrene. IARC Monogr Eval Carcinog Risks Hum 82: 1-556.
28. Bottalico A (1999) Mycotoxins in foods with possible human health implication. Part 1-Aflatoxins. Ig Mod 111: 133-169.
29. Mohammed A M, Metwally N S (2009) Antiaflatoxicogenic activities of some aqueous plant extracts against AFB1 induced Renal and Cardiac damage. J Pharmacol Toxicol 4: 1-16.
30. Wangikar PB, Dwivedi P, Sinha N, Sharma AK, Telang AG (2005) Teratogenic effects in rabbits of simultaneous exposure to ochratoxin A and aflatoxin B1 with special reference to microscopic effects. Toxicology 215: 37-47.
31. Wangikar PB, Dwivedi P, Sharma AK, Sinha N (2004) Effect in rats of simultaneous prenatal exposure to ochratoxin A and aflatoxin B1. II. Histopathological features of teratological anomalies induced in fetuses. Birth Defects Res B Dev Reprod Toxicol 71: 352-358.
32. Baruah P, Baruah LM, Baruah HK (1980) Analysis of certain fungi in stored food products and their toxic effect. Mykosen 23: 583-589.
33. Rashid N, Bajwa MA, Rafeeq M, Tariq MM, Abbas F, et al. (2013) Prevalence of aflatoxicosis in broiler chickens in Quetta, Pakistan. Pakistan J Zool 45: 1021-1026.
34. Khan FA, Zahoor M (2014) *In vivo* detoxification of aflatoxin B1 by magnetic carbon nanostructures prepared from bagasse. BMC Vet Res 10: 255.
35. Caloni F, Cortinovis C (2011) Toxicological effects of aflatoxins in horses. Vet J 188: 270-273.
36. Reis-Gomes A, Marcolongo-Pereira C, Sallis ESV, Pereira DIB, Schild AL, et al. (2014) Aflatoxicosis in dogs in Southern Rio Grande do Sul. Pesqui Vet Bras 34: 162-166.
37. Meggs WJ1 (2009) Epidemics of mold poisoning past and present. Toxicol Ind Health 25: 571-576.
38. Dilkin P, Zorzete P, Mallmann CA, Gomes JDF, Utiyama CE, et al (2003) Toxicological effects of chronic low doses of aflatoxin B1 and fumonisin B1 containing *Fusarium moniliforme* culture material in weaned piglets. Food Chem Toxicol 41:1345-1353.
39. Serck-Hanssen A (1970) Aflatoxin-induced fatal hepatitis? A case report from Uganda. Arch Environ Health 20: 729-731.
40. Murthy TR, Jemmal M, Henry Y, Frayssinet C (1975) Aflatoxin residues in tissues of growing swine: effect of separate and mixed feeding of protein and protein-free portions of the diet. J Anim Sci 41: 1339-1347.
41. Davis L, Stonehouse W, Loots du T, Mukuddem-Petersen J, van der Westhuizen FH, et al. (2007) The effects of high walnut and cashew nut diets on the antioxidant status of subjects with metabolic syndrome. Eur J Nutr 46: 155-164.
42. Martínez ML, Labuckas DO, Lamarque AL, Maestri DM (2010) Walnut (*Juglans regia* L.): genetic resources, chemistry, by-products. J Sci Food Agric 90: 1959-1967.
43. Kendall CW, Josse AR, Esfahani A, Jenkins DJ (2010) Nuts, metabolic syndrome and diabetes. Br J Nutr 104: 465-473.
44. Griel AE, Kris-Etherton PM (2006) Tree nuts and the lipid profile: a review of clinical studies. Br J Nutr 96 Suppl 2: S68-78.
45. *Carya illinoensis* (2004) Chile Government, Ministry of Agriculture.
46. Tocco G, Fais A, Meli G, Begala M, Podda G, et al. (2009) PEG-immobilization of cardol and soluble polymer-supported synthesis of some cardol-coumarin derivatives: Preliminary evaluation of their inhibitory activity on mushroom tyrosinase. Bioorg Med Chem Lett 19: 36-39.
47. Sudzuki F (1996) Subtropical fruit trees for Chile. Universitaria, Santiago, Chile, pp. 218.
48. Fetuga B, Babatunde G, Oyenuga V (1974) Composition and nutritive value of cashew nut to the rat. J Agric Food Chem 22: 678-682.
49. FAO (2006) Technical files. Fresh and processed products. Cashew.
50. Mazetto SE, Lomonaco D, Mele G (2009) Óleo da castanha de caju: oportunidades e desafios no contexto do desenvolvimento e sustentabilidade industrial. Química Nova 32: 732-741.
51. Agostini-Costa TS, Jales KA, Oliveira MEB, Garruti DS (2005) Determinação espectrofotométrica de ácido anacárdico em amendoas de castanhas de caju. Comunicado Técnico 122, EMBRAPA, Brasília, Maio.
52. Sakabe N, Goto T, Hirata Y (1977) Structure of citreoviridin, a mycotoxin produced by *Penicillium citreo-viride* molded on rice. Tetrahedron 33: 3077-3081.
53. Udagawa S, Tatsuno T (2004) [Safety of rice grains and mycotoxins - a historical review of yellow rice mycotoxicoses]. Yakushigaku Zasshi 39: 321-342.
54. Yamakawa K1 (1995) [Historical sketch of modern pharmaceutical science and technology (Part 3). From the second half of the 19th century to World War II]. Yakushigaku Zasshi 30: 1-10.
55. Richard JL1 (2007) Some major mycotoxins and their mycotoxicoses--an overview. Int J Food Microbiol 119: 3-10.
56. Sakai A, Tanaka H, Konishi Y, Hanazawa R, Ota T, et al. (2005) Mycological examination of domestic unpolished rice and mycotoxin production by isolated *Penicillium islandicum*. Shokuhin Eiseigaku Zasshi 46: 205-212.
57. Park JW, Choi SY, Hwang HJ, Kim YB (2005) Fungal mycoflora and mycotoxins in Korean polished rice destined for humans. Int J Food Microbiol 103: 305-314.
58. Tanaka K, Sago Y, Zheng Y, Nakagawa H, Kushiro M (2007) Mycotoxins in rice. Int J Food Microbiol 119: 59-66.
59. Zhang D, Wei C, Yu J-N, Pei J-R, Li D-A, et al. (2012) Morphological changes of rat cardiac tissue caused by citreoviridin combined with selenium and protein deficiency. Chin J Endemiology 31: 389-392.
60. Wan Y-Z, Wang H-M, Yu J-N, Zhang D, Pei J-R, et al. (2011) Citreoviridin-induced rat myocardial damage under combined selenium and protein deficiency. Chin J Endemiology 30: 379-383.
61. Lima HC, Porto EA, Marins JR, Alves RM, Machado RR, et al. (2010) Outbreak of beriberi in the state of Maranhão, Brazil: revisiting the mycotoxin aetiological hypothesis. Trop Doct 40: 95-97.
62. Uruguchi K (1971) Citreoviridin In: Microbial Toxins, a Comprehensive Treatise Fungal Toxins. Academic Press, New York 6: 299-380.
63. Yang JB (2012) The causes, conditions and correlated factors of Keshan disease. Chinese Journal of Endemiology 31: 499-505.
64. Beck MA, Levander OA, Handy J (2003) Selenium deficiency and viral infection. J Nutr 133: 1463S-7S.

65. Ren LQ, Li XJ, Li GS, Zhao ZT, Sun B, et al. (2004) Coxsackievirus B3 infection and its mutation in Keshan disease. *World J Gastroenterol* 10: 3299-3302.
66. Wang X, Wang S, He S, Zhang F, Tan W, et al. (2013) Comparing gene expression profiles of Kashin-Beck and Keshan diseases occurring within the same endemic areas of China. *Sci China Life Sci* 56: 797-803.
67. Wang B, He SL, Lei YX, Tang, WH, Zhang F, et al. (2014) Microarray-based gene expression profiles related to Keshan disease. *J of Xi'an Jiaotong University* 35: 163-168.
68. Rabie CJ, Van Rensburg SJ, Van Der Watt JJ, Lübben A (1975) Onyalai--the possible involvement of a mycotoxin produced by *Phoma sorghina* in the aetiology. *S Afr Med J* 49: 1647-1650.
69. Cole RJ, Kirksey JW, Cutler HG, Doupnik BL, Peckham JC (1973) Toxin from *Fusarium moniliforme*: Effects on Plants and Animals. *Science* 179: 1324-1326.
70. Marasas WFO, Nelson PE, Toussoun TA (1988) Reclassification of two important moniliformin-producing strains of *Fusarium*, NRRL6022 and NRRL6322. *Mycologia* 80: 407-410.
71. Peralta Sanhueza CE, Degrossi MC (2004) Moniliformin, a *Fusarium* mycotoxin. *Revista Mexicana de Micología* 19: 103-112.
72. Abbas HK, Cartwright RD, Xie W, Mirocha CJ, Richard JL, et al. (1999) Mycotoxin production by *Fusarium proliferatum* isolates from rice with *Fusarium* sheath rot disease. *Mycopathologia* 147: 97-104.
73. Kriek NP, Marasas WF, Steyn PS, van Rensburg SJ, Steyn M (1977) Toxicity of a moniliformin-producing strain of *Fusarium moniliforme* var. subglutinans isolated from maize. *Food Cosmet Toxicol* 15: 579-587.
74. Lew H, Chelkowski J, Pronczuk P, Edinger W (1996) Occurrence of the mycotoxin moniliformin in maize (*Zea mays* L.) ears infected by *Fusarium* subglutinans (Wollenw. & Reinking) Nelson et al. *Food Addit Contam* 13: 321-324.
75. Sewram V, Nieuwoudt TW, Marasas WFO, Shephard GS, Ritieni A (1999) Determination of the mycotoxin Moniliformin in cultures of *Fusarium subglutinans* and in naturally contaminated maize by high performance liquid chromatography-atmospheric pressure chemical ionization mass spectroscopy. *J Chromatogr A* 848: 185-191.
76. Scott PM, Abbas HK, Mirocha CJ, Lawrence GA, Weber D (1987) Formation of moniliformin by *Fusarium sporotrichioides* and *Fusarium culmorum*. *Appl Environ Microbiol* 53: 196-197.
77. Morrison E, Kosiak B, Ritieni A, Aastveit AH, Uhlig S, et al. (2002) Mycotoxin production by *Fusarium avenaceum* strains isolated from Norwegian grain and the cytotoxicity of rice culture extracts to porcine kidney epithelial cells. *J Agric Food Chem* 50: 3070-3075.
78. Springer JP, Clardy J, Cole RJ, Kirksey JW, Hill RK, et al. (1974) Structure and synthesis of moniliformin, a novel cyclobutane microbial toxin. *J Am Chem Soc* 96: 2267-2268.
79. Mitchell JC, Perkins MJ, Gilbert J (1985) Moniliformin; a(13)C and (1)H NMR study. *Mycotoxin Res* 1: 83-86.
80. Steyn M, Thiel PG, van Schalkwyk GC (1978) Isolation and purification of moniliformin. *J Assoc Off Anal Chem* 61: 578-580.
81. Sydenham EW, Thiel PG, Vlegaar R (1996) Physicochemical data for some selected *Fusarium* toxins. *J AOAC Int* 79: 1365-1379.
82. Jestoi M, Rokka M, Yli-Mattila T, Parikka P, Rizzo A, et al. (2004) Presence and concentrations of the *Fusarium*-related mycotoxins beauvericin, enniatins and moniliformin in Finnish grain samples. *Food Addit Contam* 21: 794-802.
83. Abramson D, Clear RM, Gaba D, Smith DM, Patrick SK, et al. (2001) Trichothecene and moniliformin production by *Fusarium* species from western Canadian wheat. *J Food Prot* 64: 1220-1225.
84. Adler A, Lew H, Brodacz W, Edinger W, Oberförster M (1995) Occurrence of moniliformin, deoxynivalenol, and zearalenone in durum wheat (*Triticum durum* Desf.). *Mycotoxin Res* 11: 9-15.
85. Chelkowski J, Zajkowski P, Zawadzki M, Perkowski J (1987) Moniliformin, deoxynivalenol, 3Acetyldeoxynivalenol and zearalenone - Mycotoxins associated with corn cob fusariosis in Poland. *Mycotoxin Res* 3 Suppl 1: 25-27.
86. Chelkowski J (1998) Distribution of *Fusarium* species and their mycotoxins in cereal grains. In: Sinha KK, Bhatnager D (eds.) *Mycotoxins in Agriculture and Food Safety*. Marcel Dekker, New York, pp. 45-64.
87. Janssen C, Dose K (1984) Quantitative determination of Moniliformin in vegetable foods and feeds. *Fresen J Anal Chem* 319: 60-62.
88. Kostecki M, Szczesna JG, Golinski P (1997) Simultaneous analysis of beauvericin and moniliformin in fungal cultures and in cereal grain samples. *Mycotoxin Res* 13: 17-22.
89. Sharman M, Gilbert J, Chelkowski J (1991) A survey of the occurrence of the mycotoxin moniliformin in cereal samples from sources worldwide. *Food Addit Contam* 8: 459-466.
90. Vesonder RF, Wu W, Weisleder D, Gordon SH, Krick T, et al. (2000) Toxicogenic strains of *Fusarium moniliforme* and *Fusarium proliferatum* isolated from dairy cattle feed produce fumonisins, moniliformin and a new C21H38N2O6 metabolite phytotoxic to Lemna minor L. *J Nat Toxins* 9: 103-112.
91. Carvajal M, Peralta-Sihuenza C (2007) Moniliformina. En: José Miguel Soriano del Castillo (ed.) *Micotoxinas en Alimentos*. Capítulo 17. Vol. 1. Valencia, España, pp. 323-334.
92. Engelhardt JA, Carlton WW, Tuite JF (1989) Toxicity of *Fusarium moniliforme* var. subglutinans for chicks, ducklings, and turkey poults. *Avian Dis* 33: 357-360.
93. Harvey RB, Kubena LF, Rottinghaus GE, Turk JR, Casper HH, et al. (1997) Moniliformin from *Fusarium fujikuroi* culture material and deoxynivalenol from naturally contaminated wheat incorporated into diets of broiler chicks. *Avian Dis* 41: 957-963.
94. Li YC, Ledoux DR, Bermudez AJ, Fritsche KL, Rottinghaus GE (2000) The individual and combined effects of fumonisin B1 and moniliformin on performance and selected immune parameters in turkey poults. *Poult Sci* 79: 871-878.
95. Fan LL, Li J, Sun LH (1991) Effect of moniliformin on myocardial contractility in rats. *Biomed Environ Sci* 4: 290-294.
96. Marasas WFO, Miller JD, Riley RT, Visconti A (2000) Fumonisin B1. *Environmental Health Criteria* 219: Fumonisin B1. WHO, Vammala, Finland, pp. 9.
97. Kriek NP, Marasas WF, Thiel PG (1981) Hepato- and cardiotoxicity of *Fusarium verticillioides* (*F. moniliforme*) isolates from Southern African maize. *Food Cosmet Toxicol* 19: 447-456.
98. Ledoux DR, Broomhead JN, Bermudez AJ, Rottinghaus GE (2003) Individual and combined effects of the *Fusarium* mycotoxins fumonisin B1 and moniliformin in broiler chicks. *Avian Dis* 47: 1368-1375.
99. Javed T, Richard JL, Bennett GA, Dombrink-Kurtzman MA, Bunte RM, et al. (1993) Embryopathic and embryocidal effects of purified fumonisin B1 or *Fusarium proliferatum* culture material extract on chicken embryos. *Mycopathologia* 123: 185-193.
100. Joffe AZ (1971) Alimentary toxic aleukia. In: Kadis S, Ciegler A, Aji SJ (eds). *Microbial Toxins. Algal and Fungal Toxins*. Academic Press, New York 7: 139-189.
101. Boonen J, Malysheva SV, Taevernier L, Diana Di Mavungu J, De Saeger S, et al. (2012) Human skin penetration of selected model mycotoxins. *Toxicology* 301: 21-32.
102. Bubien JK, Lundeem G, Templeton C, Woods WT (1989) Effects on the circulatory system. In: *Trichothecene Mycotoxicosis: Pathophysiological Effects*. Beasley VR CRC Press, Boca Raton, Florida, USA, pp. 32-33.
103. WHO (1990) Selected mycotoxins: Ochratoxins, Trichothecenes, Ergot. *Environment Health Criteria* 105. Geneva.
104. Wilson CA, Everard DM, Schoental R (1982) Blood pressure changes and cardiovascular lesions found in rats given T-2 toxin, a trichothecene secondary metabolite of certain *Fusarium* microfungi. *Toxicol Lett* 10: 339-341.
105. Yarom R, Yagen B (1986) T-2 toxin effect on the ultrastructure of myocardial microvasculature. *Br J Exp Pathol* 67: 55-63.
106. Yarom R, Bergmann F, Yagen B (1987) Cutaneous injury by topical T-2 toxin: involvement of microvessels and mast cells. *Toxicol* 25: 167-174.

107. Yarom R, Sherman Y, Bergmann F, Sintov A, Berman LD (1987) T-2 toxin effect on rat aorta: cellular changes *in vivo* and growth of smooth muscle cells *in vitro*. Exp Mol Pathol 47: 143-153.
108. Feuerstein G, Goldstein DS, Ramwell PW, Zerbe RL, Lux WE Jr, et al. (1985) Cardiorespiratory, sympathetic and biochemical responses to T-2 toxin in the guinea pig and rat. J Pharmacol Exp Ther 232: 786-794.
109. Tucker JB (2001) The Yellow Rain Controversy: Lessons for Arms Control Compliance. The Nonproliferation Review/Spring 25-42.