

Multidisciplinary Approach in the Management of Head and Neck Vascular Malformations

Ludovica Marcella Ponzo*, Giovanni Dell'Aversana Orabona, Giorgio Iaconetta, Fabio Astarita, Giuseppe Leone, Renato Cuocolo, Lorenzo Uga, Francesco Briganti and Luigi Califano

AICEF - ORL Italian Association of Cosmetic Surgery Facial and Neck Functional Rino, Italy

Abstract

Purpose: Arteriovenous malformations (AVM) of the head and neck are rare anomalies, but often present with significant haemorrhage or cosmetic defects. The purpose of this study is to determine the effectiveness of embolization of each type of vascular malformation.

Methods: A retrospective review was performed between January 2009 to June 2015 on 36 patients who were diagnosed vascular malformations in the head and neck regions and were referred to our department for transarterial or percutaneous embolization before the surgical approach.

Results: All 26 AVM were embolized with a transarterial approach: 18 with Onyx, 8 with a combination of PVA and coils. All patients with an AVM had a single endovascular approach. All 10 venous-lymphatic malformations were treated with a percutaneous sclerotherapy with ethanol injection. Complete healing was obtained in 30 patients (83%). In 6 (17%) there was a recurrence with necessity of a retreatment, 4 at 6 months, 2 at 12 months.

Conclusion: Transarterial embolization and percutaneous sclerotherapy is a safe treatment for artero-venous malformations before the surgical treatment. A multidisciplinary approach is fundamental to reduce the bleeding risks, the time of the surgical intervention and favouring a lesser demolitive approach particularly in large vascular malformations.

Surgical complications occurred in 6 patients (17%); all of them developed infections of the surgical wounds; 3 of these developed necrosis of the skin flap used for the reconstruction with subsequent dehiscence. No other complications including sepsis, hemorrhages, cranial nerve palsies or neuropathies occurred.

Keywords: Vascular malformation; Embolization; Multidisciplinary approach

Introduction

Arteriovenous malformations (AVM) of the head and neck are rare anomalies, but often present with significant haemorrhage or cosmetic defects [1]. The first accepted classification, based on clinical, histochemical and cellular criteria, introduced two separate entities: hemangiomas and vascular malformations [2]. According to the International Society for the Study of Vascular Anomalies (ISSVA), hemangiomas are recognized as benign, auto-involutive vascular tumors of the infancy and childhood, while vascular malformation comprise non-regressive dysplastic vessels with no endothelial proliferation. They include capillary, venous, lymphatic, arteriovenous malformations (AVM) and complex-combined forms, and can present low or high flow [3]. The choice of therapy depends on type, site and extent of the lesion.

The aim of surgery is the complete removal of the malformation. Skin, mucosa and, more rarely, cartilage or bone may have to be sacrificed.

In the last years, endovascular treatment through selective transarterial catheterization of the lesion has been used. It can be used with different aims such as occlusion of blood vessels proximal to the lesion, which may be the only effective means of controlling potentially lethal blood loss, or to perform an intralesional deposit of a microparticulated substance [4].

Sclerotherapy has proved to be an efficient therapeutic option in low-flow venous malformations. In less-delineated, large lesions this therapy can replace a function-compromising and disfiguring radical resection [5].

Today, the treatment of vascular anomalies needs a multidisciplinary collaboration of maxillo-facial surgeons and interventional neuroradiologists. In fact, the evolution of both the radiological and surgical techniques permits the cure of dangerous anomalies, reducing bleeding risk and disfiguring resections with a particularly good cosmetic outcome.

We present our experience with 36 patients with head and neck vascular anomalies who required a selective transarterial or percutaneous approach before surgical removal of the lesion. We emphasize the importance of a multidisciplinary approach for the management of vascular anomalies.

Materials and Methods

Study design

This study was designed to define the role of endovascular and percutaneous treatment before surgery of vascular malformations of the head and neck region.

A retrospective review was performed between January 2009 to

***Corresponding author:** Ludovica Marcella Ponzo, AICEF - ORL Italian Association of Cosmetic Surgery Facial and Neck Functional Rino, Italy, Tel: +393421994601; E-mail: dottludovicaponzo@gmail.com

Received May 18, 2017; **Accepted** June 02, 2017; **Published** June 09, 2017

Citation: Ponzo LM, Orabona GDA, Iaconetta G, Astarita F, Leone G, et al. (2017) Multidisciplinary Approach in the Management of Head and Neck Vascular Malformations. J Vasc Med Surg 5: 316. doi: [10.4172/2329-6925.1000316](https://doi.org/10.4172/2329-6925.1000316)

Copyright: © 2017 Ponzo LM, et al. This is an open-access article distributed under the terms of the Creative Commons Attribution License, which permits unrestricted use, distribution, and reproduction in any medium, provided the original author and source are credited.

June 2015 on 36 patients who were diagnosed vascular malformations in the head and neck regions and were referred to our department for transarterial or percutaneous embolization before the surgical approach. Diagnoses were based on clinical presentation and physical examination.

Inclusion criteria were: no previous surgical treatment, patient consensus to the endovascular or percutaneous procedure, presence of bleeding risk related to the surgical approach.

All patients had complete clinical-radiological pre- and post-procedural data.

The radiological definition was obtained in all cases by contrast-enhanced magnetic resonance angiography (CE-MRA) and/or computed tomography angiography (CTA), using the native images and 2D multi-planar reconstructions (MPR), and by digital subtraction angiography (DSA).

The size of the vascular malformation, presence of arterial feeders, of venous drainage and the angioarchitecture of the nidus were evaluated.

The endpoints were angiographic evidence of presurgical devascularization or volume reduction, restoring of the function and preventing bleeding complications with particularly good cosmetic results.

Patient characteristics

The 36 patients are 28 females and 8 males, between 15 and 60 years of age (median: 38 y). Of our patients, 10 (28%) had venous-lymphatic malformations and 26 (72%) had AVMs (Table 1).

The main clinical presentations included: regional swelling (19%), deformity and ulcerations (8%), pulsatile masses (22%), recurrent nasal bleeding (8%), difficulty in breathing (25%), difficulty in swallowing (11%), dental malocclusion (30%), headache (8%), tinnitus (2%), regional fever (72%), bleeding (30%) and massive enlargement of the tongue (11%).

Head and neck vascular malformations

Among the 26 AVMs, 3 were localized in the facial (11%), 1 in the auricular (4,5%), 3 in the nasal (11%), 5 in the orbital (20%), 4 in the oral (16%) and 3 in the mandibular (11%) regions, 1 in the tongue (4,5%), 3 in the oral mucosa (11%) and 3 in the neck (11%).

Of the 10 venous-lymphatic malformations 2 were in the oral region (20%), 3 in the tongue (30%), 1 in the mandibular region (10%), 2 in the neck (20%), 1 in the scalp (10%), 1 in the oral mucosa (10%).

The most common locations for both AVMs and venous-lymphatic

Localization	Venous-Lymphatic	AVM
Face	-	3
Ear	-	1
Nose	-	3
Orbit	-	5
Lip	2	4
Tongue	3	1
Mandible	1	3
Neck	2	3
Scalp	1	-
Oral mucosa	1	3
Total	10	26

Table 1: Anatomic localization of vascular malformations.

malformations was the oral region (6 or 17%), followed by the orbit (5 or 14%) and the neck (5 or 14%). The size ranged from 2.5 to 8 cm of diameter (mean: 4.5 cm) (Table 2).

Endovascular treatment and sclerotherapy

All patients underwent DSA. If it confirmed the presence of an AVM, the patient was then treated with an endovascular approach in the same session.

Among these patients 18 (50%) were treated with Onyx (Covidien, Neurovascular) and 8 (22%) with a combination of Polyvinyl Alcohol particles (PVA) and coils (Table 2).

Under general anesthesia, percutaneous arterious access was obtained via the right common femoral artery. A 6F guiding catheter (Cordis Envoy; Johnson and Johnson Medical, Miami, FL, USA) was positioned into the external carotid artery (ECA), proximal to the main feeders.

In the cases treated with Onyx, a flow-directed microcatheter (Marathon, Covidien Neurovascular) was navigated into the feeders as close as possible to the nidus of the AVM, with the aid of a 0.008-inch guidewire (Mirage, Covidien Neurovascular). Then, Onyx was slowly and progressively injected into the nidus under continuous visual control using fluoroscopy.

When a combined approach with PVA and coils was planned, embolization of the feeders was performed using 500-700 micron Contour PVA (Boston Scientific), then a microcatheter (Echelon, Covidien, Neurovascular) was advanced into the feeders and a variable number of coils (Axium 3D, Covidien, Neurovascular) were deployed.

All venous-lymphatic vascular malformations (28%) were treated with percutaneous sclerotherapy (Table 3). After localization by means of palpation, the lesions were directly punctured with a 23-G needle connected to a 3 mL contrast-filled syringe. A mixture of absolute ethanol and nonionic contrast medium (Iopamiro 370, Bracco) (1:2 by volume) was used to render the sclerosing agent radiopaque in all cases. The total amount of ethanol injected in a single session was determined according to the patient's body weight, not exceeding 1 mL/kg, and the amount for a single-injection dose was limited to 0.1 mL/kg, over a period of 10 min, and restricted to 10% of the maximum dose.

The injection was performed under fluoroscopy, after a test injection of contrast media in each venous space. Manual and ice-packing compression of venous outlets was performed in all the cases, to minimize the passage of alcohol into the systemic circulation and to maximize the sclerosing effect.

Corticosteroids were administered to prevent inflammatory reactions for a few days after the procedure.

Treatments	Venous-Lymphatic	AVM
Transarterial EVOH 18 (ONYX)	-	18
Transarterial PVA+ coils	-	8
Percutaneous ethanol	10	-
Total	10	26

Table 2: Types of endovascular/percutaneous treatments.

Surgical removal	36 (100%)
Cure	30 (83%)
Recurrence	6 (17%)
Endovascular/percutaneous complications	0
Surgical complications (infections, dehiscence of the surgical wound)	6 (17%)

Table 3: Surgical treatments and outcomes.

Surgical treatment

All patients underwent surgical removal of the malformations under general anaesthesia, via nasoendotracheal intubation and hypotension, within 48 h from the endovascular or percutaneous treatment.

Treatment planning depended on the risk of subsequent hemorrhage, which was determined by the demographic, historical, and angiographic features of each individual patient (Tab).

Surgery consisted of a wide excision of the malformations with margins of resection at least 5 mm wide to ensure complete removal. The reconstruction could be immediate and performed with rotation of locoregional flaps, with microvascular-free flaps or pedicle flaps. The technique was chosen on the basis of the extension of the malformation and according to the systemic conditions of the patient. Surgical resection was often associated to surgical revision of the scar, especially in cases in which the malformation extended to a wide area. In case of bone involvement, surgical resection of the soft-tissue vascular lesions and BWP of the bone cavity and curettage were performed (Figures 1-13).

Follow-up schedule

All patients underwent clinical examination after 1, 3, 6 and 12 months after the surgical procedure.

All referred to the maxillofacial surgeon once a year for the first 5 years.

MR and MRA were required in all patients after 6-12 months and always when a recurrence was suspected at the clinical follow-up. Follow-up ranged between 6 and 60 months.

Results

All 26 AVM were embolized with a transarterial approach: 18 with Onyx, 8 with a combination of PVA and coils. All patients with an AVM had a single endovascular approach.

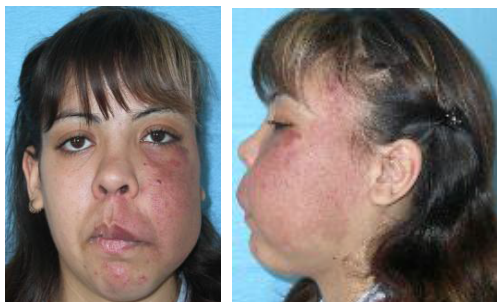

Figure 1: 20 year-old woman affected by a large AVM of the mid-face, pre-operative pictures.

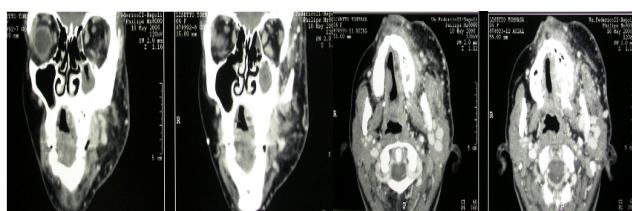


Figure 2: Computer tomography angiography coronal and axial shows a large AVM of the mid-face.

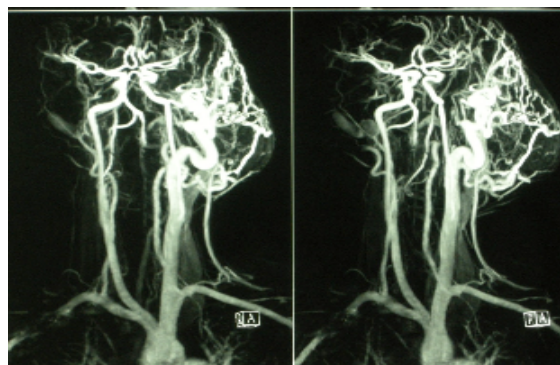


Figure 3: Contrast-enhanced magnetic resonance angiography depicted the arterial feeders and venous drainage.

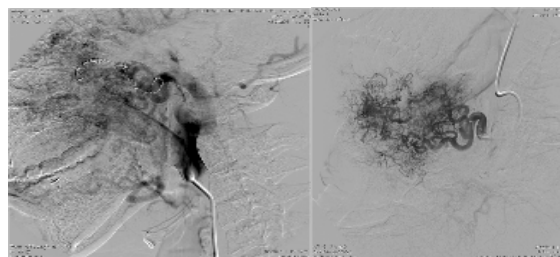


Figure 4: DSA (Digital subtraction angiography) confirmed the AVM with an enlarged internal maxillary artery feeder and facial artery; the arterial feeders were occluded by PVA plus coils.

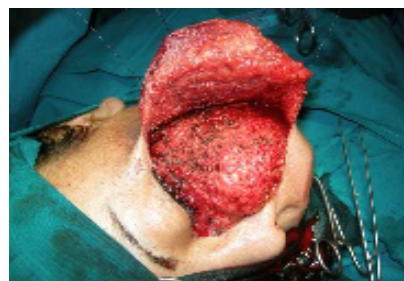

Figure 5: Surgical approach to the mid-face AVM, we apply a skin incision like weber ferguson.

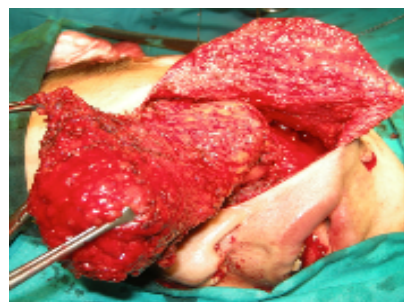

Figure 6: After dissection the AVM was removed, prior control of bleeding.

All 10 venous-lymphatic malformations were treated with a percutaneous sclerotherapy with ethanol injection. Most cases had multiple punctures in multiple sessions, depending on their size. Immediate swelling was exhibited in all patients. In all venous

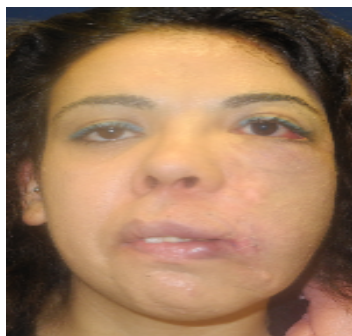


Figure 7: Control after surgery and endovascular treatment.

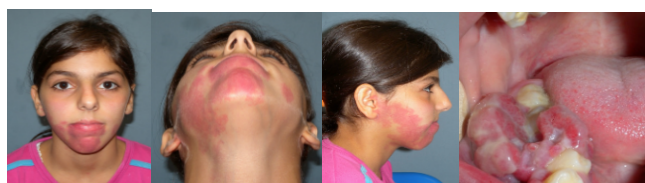

Figure 8: 11 year old woman affected by vascular lesion that evolved the alveolar portion of the mandible.

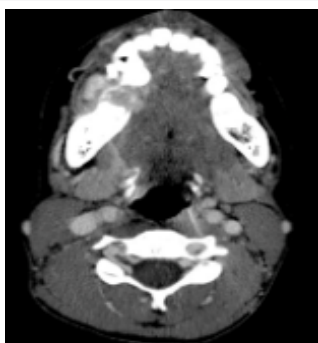


Figure 9: Contrast-enhanced CT shows the vascular lesion involving the right alveolar part of mandible.

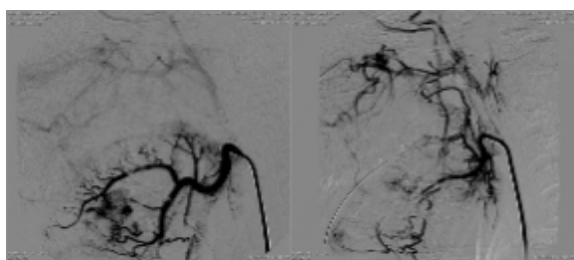


Figure 10: DSA confirmed the feeder of the lesion by the right lingual artery.

malformations, no skin necrosis or ulceration were found. No complications occurred in the pre-surgical procedures.

All patients then underwent surgical removal of the lesion within 72 h after the endovascular or percutaneous approach.

Complete healing was obtained in 30 patients (83%). In 6 (17%) there was a recurrence with necessity of a retreatment, 4 at 6 months, 2 at 12 months.

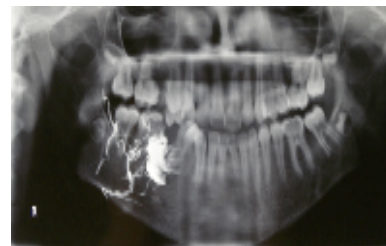

Figure 11: Radiographic control after embolization with ONYX.

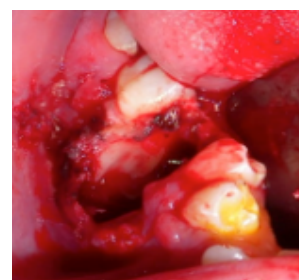

Figure 12: Surgical removal after endovascular embolization.

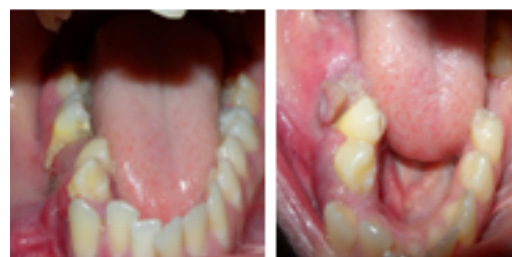

Figure 13: Control after surgical treatment.

Surgical complications occurred in 6 patients (17%); all of them developed infections of the surgical wounds; 3 of these developed necrosis of the skin flap used for the reconstruction with subsequent dehiscence.

No other complications including sepsis, hemorrhages, cranial nerve palsies or neuropathies occurred.

Among 36 patients, cure was documented in 30 patients (83%) and was satisfactory in 26 patients (72%) with an improvement of the quality of life.

With the debulking of soft tissue infiltrated by the malformation, in 11 patients (30%) we obtained the restoration of the dental occlusion and improvement of cosmetic results.

Discussion

The first step in the treatment of vascular malformations is a correct classification. AVMs of the head and neck region are rarer than intracranial ones. The diagnosis of fast-flowing malformations is usually done in young patients and can be aggravated by events such as puberty or trauma [1]. There are various possible approaches for treatment of AVMs, which is usually indicated on the basis of clinical symptoms or for aesthetic reasons.

DSA can be used both in the diagnosis and characterization of the AVM and as a means for endovascular treatment. It can assess the

size of the nidus, the flow pattern and presence of fistulas (micro or macroarteriovenous). In our experience, we proceeded to endovascular embolization of the nidus or of eventual fistulas using Onyx, PVAs and coils, choosing on the basis of the criteria we discussed in the previous paragraphs. As a rule, proximal occlusion of the AVM's feeding arteries should be avoided in the initial treatment as the risk of development of new anastomoses from other vessels in the region is very high and such practice would preclude the chance for endovascular access to the nidus in case of a new treatment.

The most common vascular malformations are venous and lymphatic mostly completely asymptomatic. Their growth is usually proportional to that of the patient and may be accelerated by puberty. These lesions present themselves as blue, soft masses which expand after a Valsalva maneuver or when they are in a dependent position.

Execution of sclerotherapy may be performed with various agents. We used ethanol, a substance that induces blood protein denaturation, determining thrombosis with a complete occlusion of the malformation, and has the added benefit of being easily available at very low costs [2]. This procedure causes an intense local inflammatory reaction whose symptoms may be mitigated by anti-inflammatory agents or other analgesics. In our experience we had no complications for this treatment in our population, even though local, cutaneous and nervous side effects and rare systemic complications have been reported in literature. Following correct safety measures such as venous-outlet manual compression help reduce the incidence of such undesired events.

Surgery is still considered the definitive treatment for most vascular malformations, because of the high recurrence rate after any type of endovascular or percutaneous treatment [6]. Beside it presents a higher risk of morbidity related to the risk of bleeding. Thus, preoperative embolization has been found to significantly reduce both intraoperative blood loss and postoperative recurrence rate [3].

Surgical excision, with previous angiography and embolization in cases of malformations, especially with larger dimension or abnormal blood supply, is our treatment of choice. After preoperative devascularization, the appropriate extent of resection must be performed; besides, radical resections for larger head and neck malformations can be dangerous and disfiguring and can sacrifice vital structures. Besides, even when apparently radical resection are undertaken, recurrence can be rapid due to recruitment of microfistulae in AVM or regrowth of venous/lymphatic malformations [4].

Close clinical and radiological follow-up for is always necessary. Analyzing our recurrence rate, 17% of the patients presented with a recurrence, with the necessity of retreatment (3 case of AVM, in 3 of venous-lymphatic malformations). So, we recommend a strictly clinical follow up, particularly in the first year, a radiological one with MR at 6-12 months; clinical follow-up should be performed at least once a year for the first five years, with immediate MR examination in the suspect of recurrence.

Optimal aesthetic results, especially for large vascular malformations occurred when the surgical resection was performed within a few days after the endovascular embolization or the percutaneous sclerotherapy. This aspect is strictly recommended when PVA particles were used, due to their limited temporary effect, and mainly for AVM to avoid the development of new microfistulae.

Moreover, the maintenance of facial symmetry, occlusion and aesthetics postoperatively is an important concern. This lead to the

concept of immediate reconstruction introduced by Weaver and Smith (1973) [7].

The cosmetic outcome was analyzed in our cohort and satisfactory was obtained in 26 patients (72%) with an improvement of the quality of life. In 4 patients, although a cure was documented, the aesthetic results were not judged satisfied, with the persistence of psychological disturbances.

When evaluating and planning treatment for patients with head and neck vascular malformations each case has unique concerns and a complete radiological assessment with CT, MR and DSA must be performed.

For these reasons, especially in complex malformations, a multidisciplinary approach with interventional radiologists and surgeons is nowadays mandatory.

Conclusion

Transarterial embolization and percutaneous sclerotherapy are a safe treatment before surgery in the management of head and neck vascular malformations.

We believe that the successful treatment and the lack of accompanied complications may reflect the careful technique used, which was based on a meticulous preoperative imaging of the lesions. Undoubtedly a multidisciplinary approach is fundamental to reduce the bleeding risks, the time of the surgical intervention and favouring a lesser demolitive approach particularly in large vascular malformations.

References

1. Waner M, Suen JY (1999) Hemangiomas and vascular malformations of the head and neck. New York: Wiley-Liss.
2. Mulliken JB, Glowacki J (1982) Hemangiomas and vascular malformations in infants and children: a classification based on endothelial characteristics. *Plast Reconstr Surg* 69: 412-422.
3. Enjorras O (1997) Classification and management of the various superficial vascular anomalies: hemangiomas and vascular malformations. *J Dermatol* 24: 701-710.
4. Braun IF, Levy S, Hoffman JC (1985) The use of transarterial microembolization in the management of hemangiomas of the perioral region. *J Oral Maxillofac Surg* 43: 239-248.
5. Mitchell SE, Shah AM, Schwengel D (2006) Pulmonary artery pressure changes during ethanol embolization procedures to treat vascular malformations: can cardiovascular collapse be predicted? *J Vasc Interv Radiol* 17: 253-262.
6. Kohout MP, Hansen M, Pribaz JJ, Mulliken JB (1998) Arteriovenous malformations of the head and neck: natural history and management. *Plast Reconstr Surg* 102: 643-654.
7. Weaver AW, Smith DB (1973) Frozen autogenous mandibular stent-graft for immediate reconstruction in oral cancer surgery. *Am J Surg* 126: 505-506.