

Mesenteric Lipoma in a Goat

Ghasem Farjanikish^{1*} and Hossein Mohammadi²

¹Department of Pathobiology, Faculty of Veterinary Medicine, Lorestan University, Khorramabad, Iran

²Department of Pathobiology, Faculty of Veterinary Medicine, Shahid Chamran University of Ahvaz, Khuzestan, Iran

*Corresponding author: Ghasem Farjanikish, DVM, PhD, Assistant Professor of Veterinary Pathology, Department of Pathobiology, Faculty of Veterinary Medicine, Lorestan University, Khorramabad, Iran, Tel: +98 -066-33302033; E-mail: farjanikish.gh@lu.ac.ir

Received date: April 30, 2016; Accepted date: June 20, 2016; Published date: June 27, 2016

Copyright: © 2016 Farjanikish G, et al. This is an open-access article distributed under the terms of the Creative Commons Attribution License, which permits unrestricted use, distribution, and reproduction in any medium, provided the original author and source are credited.

Abstract

A 5 years old female, mixed-breed goat was presented to clinic for evaluation of postmortem lesions because it showed evidence of paratuberculosis. At necropsy examination, whitish-yellow lobulated mass (11 × 8 × 4 cm) was found on the ileal mesentery. Histopathologically, the tumor consisted of well-differentiated fat cells with no pleomorphism and anaplasia. The cells have monovacuolated and multivacuolated cytoplasm. Mitotic figures were not observed in the mature adipocytes. On the basis of the gross and microscopical findings, the mesenteric lipoma was diagnosed.

Keywords: Goat; Mesenteric lipoma; Histopathologically

Introduction

Neoplasms of adipocytes are classified as lipomas, infiltrative lipomas, angioliipomas, and liposarcomas. Lipomas are benign fatty tumors composed of mature fat cells. These neoplasms are commonly encountered in dogs, occasionally identified in cats and horses, and rarely observed in other domestic species [1,2].

Lipomas are common benign tumors that are composed of lobules of well-differentiated adipocytes. They may arise in any anatomical location, but commonly occur in the subcutis of the chest, abdomen, legs and axillae [3-5]. Lipomas are usually found in older animal and the incidence of neoplasms increase with age [1,4,5]. In the present report, we describe pathological characteristics of a mesenteric lipoma in a goat.

Case Presentation

A 5 years old female, mixed-breed goat with history of lethargy, diarrhea, progressive weight loss and emaciation was necropsied and postmortem examination was conducted. In accordance to gross findings, it was concluded that significant findings in the goat were related to flock problems and showed evidence of paratuberculosis.

At the examination of the abdominal cavity, ileal mesentery in the lower abdominal cavity was covered by a whitish-yellow tumoral mass, which was coarsely lobulated and soft, with 11 × 8 × 4 cm dimensions (Figure 1). In addition, thickening and corrugation of the intestinal mucosa and enlargement of mesenteric lymph nodes were more evident in the ileum than other parts of the intestine.

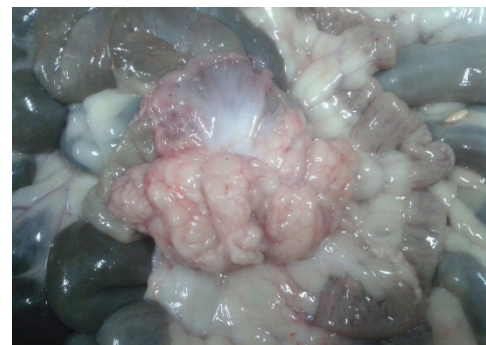

Figure 1: Lipoma. Whitish-yellow lobulated tumoral mass is in the abdominal cavity.

For microscopic investigations, histopathological specimens were obtained from the tumoral mass and, fixed in 10% neutral-buffered formalin, dehydrated in graded ethanol, cleared in xylene, and embedded in paraffin wax. Sections in 5- μ m thicknesses were stained by hematoxylin and eosin, and studied microscopically.

Histopathologically, the mass was composed of variable sized lobules separated by fibrous septa. The lobules were composed of relatively mature adipocytes with significant variation in cell size, with no pleomorphism and anaplasia (Figure 2). The adipocytes were well differentiated and contained a large, monovacuolated and multivacuolated cytoplasm (Figure 3). Mitoses were not observed in the mature adipocytes. Based on gross and microscopical findings giant mesenteric lipoma was diagnosed.

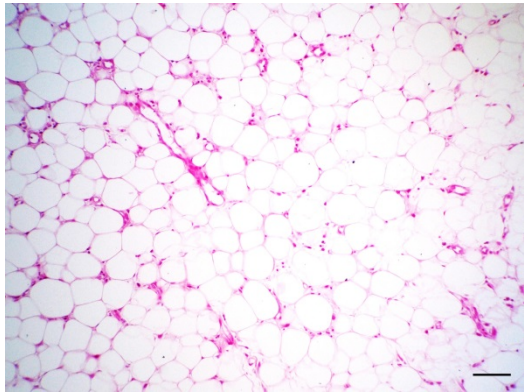


Figure 2: Lipoma. The mass is composed of well-differentiated fat cells (HE, Bar=100 µm).

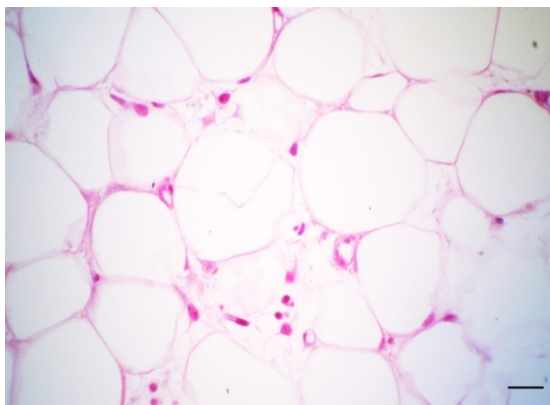


Figure 3: Lipoma. The adipocytes have variably sized and clear cytoplasmic vacuoles (HE, Bar=25 µm).

In the ileum, diffuse granulomatous enteritis and lymphadenitis with infiltration of mononuclear inflammatory cells such as lymphocytes and epithelioid macrophages were prominent. The mesenteric lymph nodes were shown multifocal granulomas distributed throughout the cortex and paracortex.

Discussion

Lipomas are neoplasms of well-differentiated lipocytes and lipoblasts [1]. These tumors are most common in dogs and are uncommon in other species [5-7]. Intrapericardial lipoma and infiltrative lipoma in the heart have been reported in horses [8,9].

In this case, because most neoplastic cells resembled neoplastic adipocytes and contained clear lipid vacuoles, the neoplasm was classified as a lipoma. It is difficult to define the origin of the mass in the present case, but mesenteric adipose tissue would be most likely.

Mesenteric lipomas are usually asymptomatic and create a clinical picture that depends on the localization and size of the lipoma. The tumors can cause symptoms consistent with a partial bowel

obstruction, such as intermittent abdominal pain, abdominal distention, and vomiting, with very few resulting in intestinal volvulus or complete intestinal obstruction due to torsion [10-15]. However, most mesenteric lipomas are of no clinical consequence. Although rare, intestinal strangulation by pedunculated lipomas has been reported in the dog. Pedunculated lipomas in horses can also cause strangulation, colic, ischemia and death [16,17].

In human, lipomas may show a familial tendency and an increased incidence in people who are obese, have diabetes mellitus or hypercholesterolemia, and experience a traumatic injury [18]. These tumors commonly recur after excision, but metastasis is rare.

The histologic characteristics of the present case were similar to those of other cases reported in humans and animals [14,16,19,20].

References

1. Goldschmidt MH, Hendrick MJ (2002) Tumors of the skin and soft tissues. In: Meuten DJ (ed.) Tumors in Domestic Animals. Ames, IA: Iowa State Press, pp: 45-117.
2. Head KW, Else RW, Dubielzig RR (2007) Tumors of the Alimentary Tract. In: Meuten DJ (ed.) Tumors of Domestic Animals. Blackwell Publishing Company, pp: 52.
3. Ogilvie GK, Moore AS (1995) Managing the Veterinary Cancer Patient. (1stedn), Veterinary Learning Systems, Trenton, pp. 486-487.
4. Kumar DD, Muralikrishana BV, Ramakrishna V (1997) Dystocia due to foetal lipomatosis in a she buffalo. Indian Vet J 74: 687-688.
5. Cheville FN (1999) Characterizing the Neoplasm. In: Ackerman M, Andreasen C (eds.) Introduction to Veterinary Pathology. Iowa State University Press, Iowa, pp: 281-283.
6. Weiss E (1974) Tumors of the soft (mesenchymal) tissues. In: Appley EC, Beveridge WIB (eds.) Bulletin of the World Health Organization, International Histological Classification of Tumors of Domestic Animals, Geneva, pp: 109.
7. Gincamillo M, Lombardo R, Beretta S, Pravettoni D, Cipone M, et al. (2002) Congenital facial infiltrative lipoma in a calf. Vet Radiol Ultrasound 43: 46-49.
8. Baker D, Kreeger J (1987) Infiltrative lipoma in the heart of a horse. Cornell Vet J 77: 258-262.
9. Hamir AN, Habecker P, Tulleners E (1994) Equine intrapericardial lipoma. Vet Record 135: 235-236.
10. Prando A, Wallace S, Marins JL, Pereira RM, de Oliveira ER, et al. (1990) Sonographic features of benign intraperitoneal lipomatous tumors in children--report of 4 cases. Pediatric Radiol 20: 571-574.
11. Takagi Y, Yasuda K, Nakada T, Abe T, Saji S (1998) Small bowel volvulus caused by a lipoma of the mesentery showing a distinct pattern on preoperative computed tomography. Dis Colon and Rectum 41: 122-123.
12. Sheen AJ, Drake I, George PP (2003) A small bowel volvulus caused by a mesenteric lipoma: report of a case. Surg Today 33: 617-619.
13. Ozel SK, Apak S, Ozercan IH, Kazez A (2004) Giant mesenteric lipoma as a rare cause of ileus in a child: report of a case. Surg Today 34: 470-472.
14. Cha JM, Lee JI, Joo KR, Choe JW, Jung SW, et al. (2009) Giant mesenteric lipoma as an unusual cause of abdominal pain: a case report and a review of the literature. J Korean Med Sci 24: 333-336.
15. Srinivasan KG, Gaikwad A, Ritesh K, Ushanandini KP (2009) Giant omental and mesenteric lipoma in an infant. Afr J Paediatr Surg 6: 68-69.
16. McLaughlin R, Kuzma AB (1991) Intestinal strangulation caused by intraabdominal lipomas in a dog. J Am Vet Med Assoc 199: 1601-1611.
17. Dunkerley SA, Williams A, Gillis JP (1997) Lipoma in a foal. J Am Vet Med Assoc 210: 322-323.
18. Ilhan H, Tokar B, Isiksoy S, Koku N, Pasaoglu O (1999) Giant mesenteric lipoma. J Paediatr Surg 34: 639-40.

19. Khodakaram-Tafti A, Shirian S, Vesal N, Hadadi S (2011) Lipoma of the urinary bladder in a cat. *J Comp Pathol* 144: 212-213.
20. Turk E, Edirne Y, Karaca F, Memetoglu ME, Unal E, et al. (2013) A Rare Cause of Childhood Ileus: Giant Mesenteric Lipoma and a Review of the Literature. *Eurasian J Med* 45: 222-225.