

Ludwig's Angina in Pregnant Patient: A Case Report of Multi-Professional Treatment

Melo Radamés B¹, Gurgel Jessica F¹, SÁ Carlos DL¹, Feitosa Victor P¹, Pimenta Yuri S², Ferreira Diego P³

¹Department of Dentistry, Paulo Picanço School of Dentistry, Brazil, ²Federal University of Amazonas, Brazil, ³University Hospital João de Barros Barreto, Brazil

Abstract

Ludwig's Angina (LA) is cellulitis frequently originated from an odontogenic infection, classically related to the second or third lower molars, involving bilateral submandibular spaces. The typical symptomatology includes pain, dysphagia, trismus, tongue protrusion, and fever. In addition, there is an imminent risk of airway obstruction. The aim of the present study is to report a case of a 28-year-old patient with 30-weeks pregnancy hospitalized due to a volume increase in the bilateral region under the mandibular jaw. Blood exam depicted leukocytosis whilst panoramic X-Ray showed tooth 38 with caries and periapical lesion, highlighting it was the possible cause of Ludwig's angina. Treatment was undertaken by a multi-professional team, a general surgeon to perform a tracheostomy and protect airways, an obstetrician to realize the child-birth due to the risk for the baby during general anesthesia, and a maxillofacial surgeon to extract tooth 38 and to drain submandibular area. During the entire treatment process, no complications occurred. The patient was followed up to 6 months and all complaints were overcome.

Key Words: Ludwig's angina, Abscess, Pregnant women, Surgery, Immunity

Introduction

Ludwig's Angina (LA), described by the German physician Wilhelm Frederick von Ludwig in 1836, is a rapid-development toxic cellulitis, often of odontogenic origin, involving bilateral submandibular and sublingual facial spaces as well as submental. It is an infection located below the mylohyoid muscle insertion anatomically nearby the submandibular space. When the spaces are affected, it usually causes stiffening of the buccal floor, difficult swallowing, tongue elevation and risk of airways obstruction giving the patient a sensation of suffocation, this overall combined might be classified as angina [1,2].

The symptomatology is basically the same in most cases, such as fever, dysphagia, dyspnea, trismus, and dysphonia. Patients with diseases such as AIDS, diabetes mellitus, malnutrition, alcoholism or those immunosuppressed are more susceptible to Ludwig's angina. In turn, pregnant women are at increased risk of dental caries for a number of reasons, including increased acidity in the oral cavity, binge eating and limited attention to oral health, which may lead to an oral infection that can attain serious proportions during pregnancy. The incidence of maxillofacial infections during pregnancy is low; however, we can find in the literature some cases of pregnant women with Ludwig's angina [3-5].

In order to assist accurate and rapid diagnosis, it is necessary to use imaging exams and laboratory tests. The treatment is basically a three-component of removal of the infection cause agent which is usually a carious tooth in the region of the lower third or second molars, surgical drainage for removal of the purulent collection and decompression of the facial spaces and antibiotic therapy with penicillin and metronidazole or clindamycin [2,3]. Despite not being an uncommon lesion, dental practitioners know little about the diagnosis, treatment plan and prognosis of Ludwig's Angina, and different case reports and reviews on the subject are needed.

Therefore, this study aims to report an atypical case of a pregnant patient with the LA requiring a multi-professional team to solve the case.

Case Report

A 28-year-old female patient was assisted in the Department of Maxillofacial Surgery and Traumatology of a regional hospital, with facial pain, difficulty to swallow and to open the mouth. The patient was pregnant with thirty weeks, in normal systemic condition without allergies and a mild anemia due to the pregnancy. In the clinical examination, a hardened swelling was observed bilaterally in submandibular, sublingual and left parotid-masseteric regions (*Figure 1A*). In addition, the patient presented the following symptoms: severe trismus, fever (39), dysphagia and dyspnea. Leukocytosis with 28,000/mm³ was highlighted in the complementary exams.

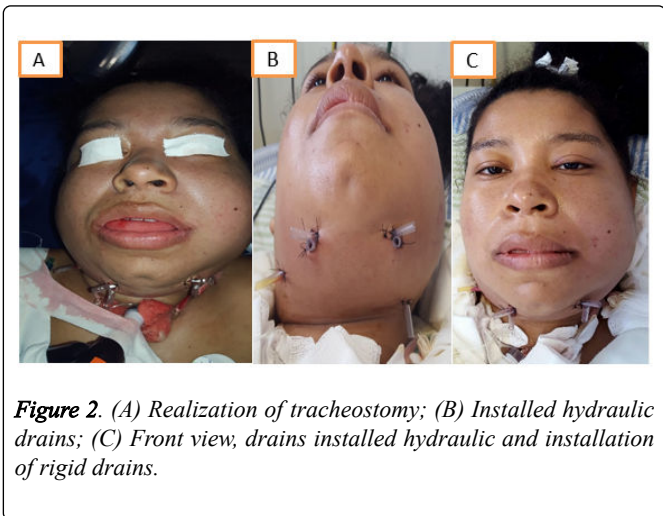
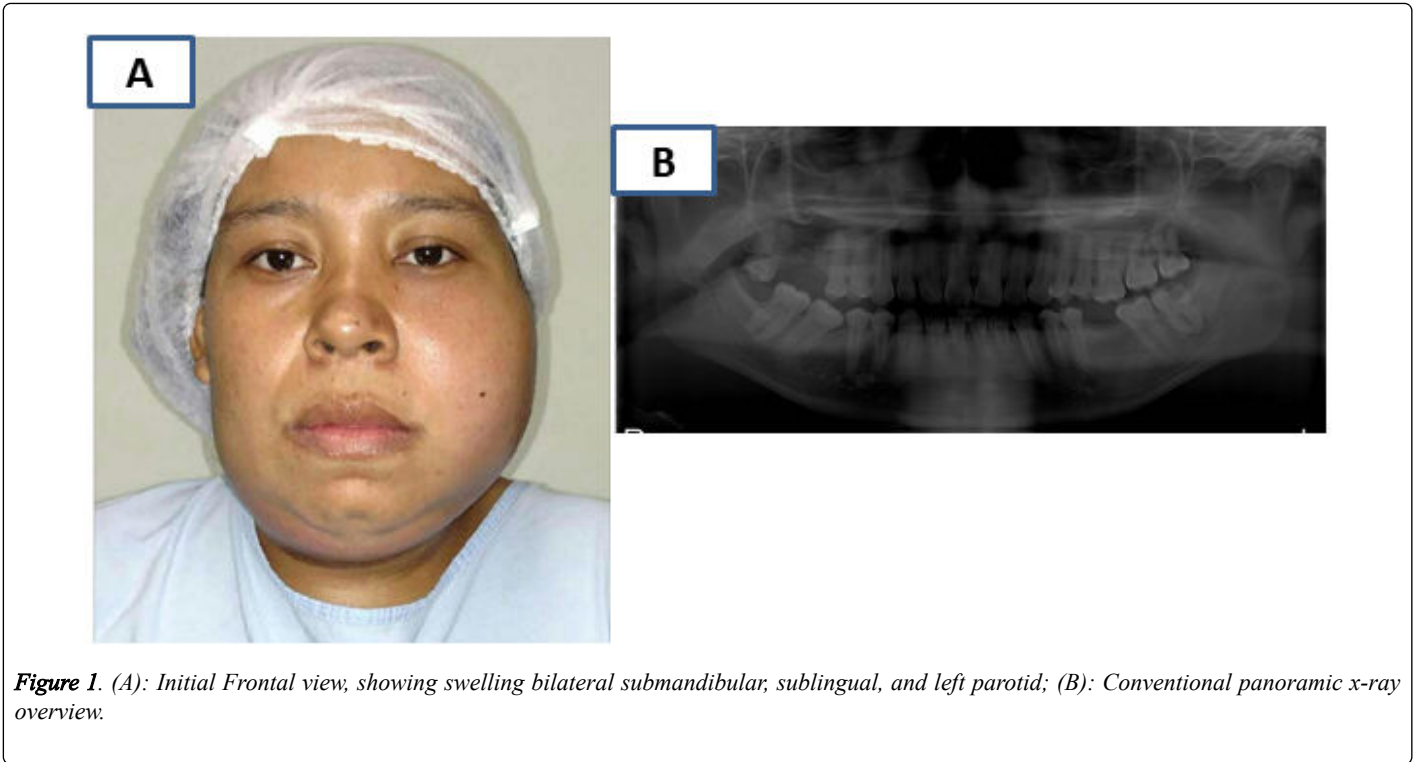
X-Ray exams were requested and the possible infectious agent was identified, the left lower Molar (dental element 38) with a periapical abscess that drained to the peri-mandibular spaces (*Figure 1B*).

The bilateral submandibular, sublingual, submental and left buccal spaces were affected. After the results of the clinical, radiographic and laboratory tests, Ludwig's Angina was diagnosed in advanced stage due to the summary of factors, such as the five facial spaces affected. As a result, a treatment plan with a multi-professional team of the hospital was carried out.

The patient underwent antibiotic therapy consisting of clindamycin 600 mg administration at each 6h (4 times a day). The multi-professional surgical procedures were performed in the following order: the obstetrician physician proceeded with emergency cesarean and the general surgeon performed a tracheostomy for the sake to maintain upper airways (*Figure 2A*). The maxillofacial surgeon, in the Trans operative period, performed the extraction of the infectious agent (dental

element 38) and then surgically drained through multiple incisions in the submental and submandibular region

bilaterally. After drainage of the infection, rigid drains were installed to continue drainage (Figures 2B and 2C).

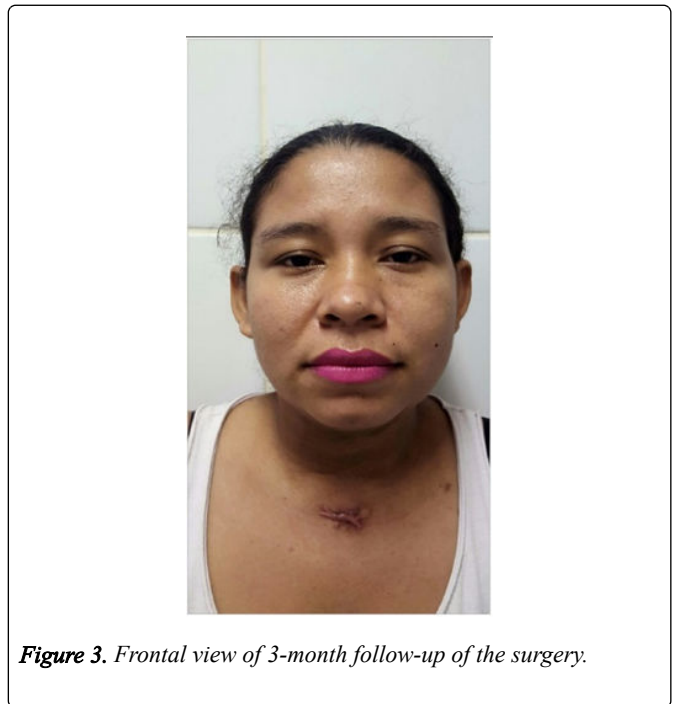

During the first three days, irrigation with saline solution at every 4 hours was used as the post-operative protocol, and complementary tests were again requested. A satisfactory decrease in leukocytosis was achieved with 17,000/mm³ level. After the drainage removal, at the third day after surgery, the patient was hospitalized for another 4 days and the intravenous antibiotic therapy with clindamycin 600 mg at each 8h (3 times a day) was conducted.

On the seventh postoperative day, the patient was discharged along with her newborn. She was oriented to realize warm-water compress three times daily and mouth opening physiotherapy.

The patient had periodic returns. After 3 months of surgery, she returned to the care unit without edema, the absence of pain and trismus, normal red blood cells and leukocytes, demonstrating that the operative procedure was fully

successful and resulted in the best care for both the patient and her healthy newborn (Figure 3).



Discussion

The literature shows that from 70% to 90% of cases of Ludwig's Angina, the etiology is an odontogenic infection. The reported clinical case was also of odontogenic origin. However, it can also be caused by other factors such as the presence of foreign bodies, mandibular fractures, infected oral neoplasms, abscesses located in the tonsils and among other factors [6-9].

More attention is needed for these infections, as their aggravation may result in Ludwig's Angina, Orbital Cellulitis, Cavernous Sinus Thrombosis, and Mediastinitis among others. The nature of odontogenic infection has a mixed microbiota composed of gram-positive aerobic microorganisms and gram-negative anaerobes, for example, streptococci and bacilli, also present in the oral cavity free of infection. Polymicrobial cultures are found in 50% of cases [10-13].

Over the years, antibiotics have become more effective and the oral hygiene of the population has improved significantly, but the severity of Ludwig's Angina, when found, remains high [1,14].

One of the criteria for diagnosing Ludwig's Angina is to observe the spaces affected bilaterally, gangrenous infiltration, serosanguinous and putrid, with little or no pus, if the communication between the spaces and the time of progression [4].

The present clinical manifestations aid in the diagnosis as dysphagia, trismus, algia, the sensation of suffocation, fever, dysphonia, dysphagia. Infection and edema are limited by the deep cervical fascia, mandible, and hyoid. The tongue and floor of the mouth are elevated and later displaced with compromised airway, resulting in abrupt asphyxia. [11,15] Of the clinical characteristics, one should ask for the imaging tests that will help identify the etiology and decide the treatment plan [3,4].

There are patients who are more susceptible to Ludwig's Angina such as patients with AIDS, alcoholics, malnourished patients with diabetes mellitus and immunosuppressed patients in general [2]. Pregnancy, for example, is accompanied by many physiological changes that put the mother at greater risk of infection or worsen when infected. Relatively quick progression occurs in pregnancy, resulting in a more rapid progression of an infection [12].

In the case reported, the pregnant woman fits into this risk group because the gestational period is associated with changes, where the oral cavity is undergoing enormous changes that must be followed by the dental surgeon. Dental caries and abscesses in the oral and maxillofacial region can release various exotoxins, cytolytic enzymes, as well as gram-positive and gram-negative bacteria, exhibiting their harmful effects throughout the physiological system [4].

Since it was a pregnant patient, the multi-professional team chose cesarean because the patient was 30 weeks pregnant and drainage should be performed in a hospital environment with general anesthesia that often induces labor. The most commonly used antibiotic therapy according to the literature is penicillin, usually associated with metronidazole. Tetracyclines should be avoided since they tend to cause permanent discoloration of the primary and temporary teeth of the fetus [11]. However, in the case reported, the antibiotic of choice was clindamycin throughout the treatment, due to its bactericidal action, its broad spectrum and, mainly, its excellent absorption in bone tissues.

For the treatment to be successful, it is essential to use correct antibiotics, removal of the cause, surgical exploration with the spaces involved and maintenance of the airways

[3,5]. The choice of antibiotic therapy, as well as the timing of the surgical intervention, were vital for the resolution of the presented case. Ludwig's angina is a life threat because of septicemia and asphyxia. In addition, in pregnancy, the risks that the condition and possible therapies may cause to the mother and the fetus should be considered, as well as the possible consequences of the condition and the therapies for both [12].

In view of the risks, to which Ludwig's angina patients are exposed, hospital admission is essential, so that the disease does not worsen and the patient does not die.

Conclusion

Ludwig's Angina is a rapidly progressing cellulite, which involves the mandibular spaces. The immediate and precise diagnosis based on the clinical and complementary examinations allied to the effective medication and surgical interventions are primordial for the maintenance of the patient life. Since Ludwig's Angina, if untreated, can lead to death due to obstruction of the airways or by septicemia. In the case presented, a good interaction of a multi-professional team in the treatment of Ludwig's Angina is essential for the maintenance of the patient's life.

References

1. Tavares SS, Tavares GR, Cavalcanti MOA, Carreira PFS, Cavalcante JR, et al. Angina de Ludwig: revisão de literatura e relato de caso. *Buco-Maxillo-Facial Surgery and Traumatology Journal*. 2009; **9**: 9-14.
2. Soares LP, Silva TSN, Beltrão RC, Oliveira MG, Beltrão GC. Angina de Ludwig associada à presença de corpo estranho em região sublingual. *Passo Fundo*. 2004; **9**: 23-26.
3. Zanni FD, Stefani E, Santos JC, Perito LS, Krueel NF. Angina de Ludwig: relato de caso e revisão do manejo terapêutico. *Arquivos Catarinenses de Medicina*. 2003; **32**: 20-23.
4. Kamath AT, Bhagania MK, Balakrishna R, Sevagur GK. Ludwig's Angina in Pregnancy Necessitating Pre Mature Delivery. *Journal of Maxillofacial and Oral Surgery*. 2015; **14**: 186-189.
5. Fogaça PFL, Queiroz EA, Kuramochi MM, Vanti LA, Correa JDH. Angina de Ludwig: uma infecção grave. *Revista Portuguesa de Estomatologia, Medicina Dentária e Cirurgia Maxilofacial*. 2006; **47**:157-161.
6. Martins L, Rocha RCA, Santos KCP, Marcucci M, Costa C, et al. Angina de Ludwig: considerações sobre conduta e relato de caso. *Revista Instituto Ciência e saúde*. 2009; **27**: 413-416.
7. Segundo AVL, Pinheiro RTA, Inaoka SD, Neto AR, Lago CAP. Angina de Ludwig decorrente de exodontias de molares inferiores: relato de caso clínico. *Revista de Cirurgia e Traumatologia Buco-Maxilo-Facial*. 2006; **6**: 23-28.
8. Moura PS, Alvares LD, Tuji FM, Nogueira JSE. Complicação sistêmica de angina de Ludwig: relato de caso. *Revista Paraense de Medicina*. 2010; **24**: 71-75.
9. Melo TAF, Rucker T, Carmo MPD, Irala LED, Salles AA. Ludwig's angina: diagnosis and treatment. *Revista Sul-Brasileira de Odontologia*. 2013; **10**: 172-175.
10. Patterson HC, Kelly JG, Strome M. Ludwig's angina: An update. *Laryngoscope*. 1992; **4**: 370-378.
11. Lawrenz DR, Whitley BD, Helfrick JF. Considerations in the management of maxillofacial infections in the pregnant patient. *Jornal de Cirurgia Bucomaxilofacial*. 1996; **54**: 474-485.
12. Abramowicz S, Abramowicz JS, Dolwik MF. Severe life-threatening maxillofacial infection in pregnancy presented as

ludwig's angina. *Infectious Diseases in Obstetrics and Gynecology*. 2006; 1-4.

13. Azenha MR, Lacerda SA, Bim AL, Caliento R, Guzman S. Celulite facial de origem odontogênica. Apresentação de 5 casos. *Revista de cirurgia e traumatologia buco-maxilo-facial*. 2012; **12**: 41-48.

14. Vasconcelos BCE, Cauás M, Albert DGM, Nascimento GJF, Holanda GZ. Disseminação de Infecção odontogênica através das

fácias cervicais profundas: relato de caso clínico. *Revista de Cirurgia e Traumatologia Buco Maxilo-Facial*. 2002; **2**: 21-25.

15. Niederhauser A, Kirkwood D, Magann FE, Mullin PM. Ludwig's angina in pregnancy. *The Journal of Maternal-Fetal and Neonatal Medicine*. 2006; **19**: 119-120.